

Original Research Article

Early same admission closure of temporary bowel stomas: pros and cons

Ahmed Abdelkahaar Aldardeer*, Alaa Alsuity, Ahmed Gaber Mahmoud

Department of General Surgery, Sohag Faculty of Medicine, Sohag, Egypt

Received: 09 July 2021

Revised: 28 July 2021

Accepted: 29 July 2021

*Correspondence:

Dr. Ahmed Abdelkahaar Aldardeer,

E-mail: ashour2003@gmail.com

Copyright: © the author(s), publisher and licensee Medip Academy. This is an open-access article distributed under the terms of the Creative Commons Attribution Non-Commercial License, which permits unrestricted non-commercial use, distribution, and reproduction in any medium, provided the original work is properly cited.

ABSTRACT

Background: Early closure of a temporary stoma is usually associated with low morbidity and mortality. However, some cases of stoma reversal may develop complications which may need surgical correction with subsequent major complications. We aim to evaluate early bowel stoma closure; de-functioning diversion stoma closure within the same admission (8-15 days) and study morbidity, health related quality of life (QOL) and length of stay at hospital (LOH).

Methods: This study was done at general surgery department, Sohag faculty of medicine; in the period between March 2020 and March 2021, 28 patients were closed early (at the same admission). Which are chosen randomly. The 28 patients who underwent early temporary stoma reversal following bowel surgery and abdominal exploration between March 2020 and March 2021 were included. The rate of complications (medical and surgical) following early stoma closure were assessed. Health-related QoL and LoH were assessed.

Results: Total 28 patients were taken up for early stoma closure, reversal of stoma occurred between 8-15 days following its creation. Postoperative complications occurred in 53% of our patients, skin excoriation the commonest (28%). No difficulty was encountered during stoma closure surgery. Post-operative complications occurred in 53% of patients. 5 patients develop Ileus which were managed conservatively and one patient (3.5%) develop intra-abdominal abscess and treated with aspiration under sonographic guided. In our study no mortality occurred.

Conclusions: Early stoma closure is feasible in selected patients, with reduced hospital stay, adhesions, bowel obstruction and medical complications and leads to better QOL, but a higher wound complication rate.

Keywords: Early stoma, Length of hospitalization, Quality of life

INTRODUCTION

A lots of bowel surgeries and open abdominal surgery (OA) commonly need Fecal diversion and Stoma creation. We use stomas or diversion of intestinal content as a wide spread technique for treating many surgical problems including congenital diseases, acute or chronic inflammation, acute or chronic colonic obstruction, usually to protect the distal anastomosis in cases where we expect anastomotic leakage. The most common procedures for fecal diversion are loop transverse colostomy and loop ileostomy.¹

There are many types of stoma. The most common classification done according to bowel part where they are classified to (jejunostomy, ileostomy, colostomy). They are also may classified to loop or end ostomy. They may be temporary or permanent and elective or part of emergent operations. Sometimes, it is performed as a part of challenging operations as well.^{2,3}

Complications due to stomas (major or minor) in recent studies remains widely distributed, ranging from 10 to 52%. It may be minor, needs only local care or can be severe, needs new operation. (According to Calvien-Dindo classifications of post-operative complications),

when stoma reversal was delayed, intraperitoneal adhesions occur; make reversal of stoma more difficult and increase both morbidity and mortality.⁴

Early stoma closure eliminates complications of stomas and enhance quality of life. The reversal time is important for temporary stomas. Some old reports, the temporary ileostomy accepted reversal time more than 3 months, created during low anterior resection for rectum carcinoma.⁵

Inspite this, during this time, stoma-related complications occur in quarter of patients, with adverse effects on quality of life. So, that early reversal (same admission) can be done without increasing mortality and morbidity.

Exploration is a life-saving and challenging strategy in situations such as the abdominal compartment syndrome (ACS), damage-control surgery in severe generalized peritonitis. During OA management, sometimes, stomas have to be created to overcome entero-cutaneous fistula (ECF), intra-abdominal sepsis, and distal bowel obstruction.^{6,7}

These stomas which may be opened at anywhere of the bowel (from more proximal jejunum to sigmoid colon) are usually temporary.⁸

According to our study, there is no any comprehensive data about reversal of stoma created during OA management in literature. we therefore aim to report our early stoma reversal series following OA management regarding morbidity and mortality.

METHODS

The present study was conducted at general surgery department, Sohag university hospital in the period from March 2020 to March 2021. The study was conducted on 28 patients (12 males and 16 females) who had temporary stoma, chosen randomly.

Contraindications for early closure include distal bowel non healing, wound sepsis, or persistent post-operative instability.

Surgical technique

The surgical technique is the standard procedure, and the closure of the stoma is carried out with stapling-only technique in all our cases, depending on the local guidelines.⁹

The data were analysed by SPSS data base with application of Chi-square test and test of comparison of proportions, $p < 0.01-0.05$.

The surgeon will register information regarding the surgical intervention: ASA score, stapled anastomosis, blood loss, duration of surgery and anesthetic method.

Early stoma closure decreases the incidence of preoperative complications that mentioned in cases of late closure.

A prospective analysis of 28 patients who underwent early reversal of stoma created between March 2020 and March 2021 was done. Twenty-eight cases were included into the study. Written informed consent was obtained from all patients.

Analyzed variables were as follows: patients' demographics, body mass index (BMI) the American society of anesthesiologists (ASA) classification for operative risk score, waiting time interval for reversal (time interval between the end of the delayed abdominal closure and stoma reversal), type of stoma (jejunostomy, ileostomy, colostomy, with end or loop), surgical complications after reversal, stoma-related complications during this time interval, surgical technique employed, length of hospital stay, and mortality rate.

Statistical analysis

In this study, standard deviation, median, and minimum and maximum values were used to summarize the numeric variables of patients.

RESULTS

Causes of stoma formation was shown in Table 2.

Fifteen (53.5%) of the 28 patients developed complications. The most common was surgical wound infection, which occurred in eight patients (28%), and the second one was ileus in five patients (17.5%), resolved in all with conservative treatment; one intra-abdominal abscess was resolved by radiological intervention; and one anastomotic leak (3.5 %) occurred after colostomy reversal and this patient underwent reoperation. The entire abdomen was irrigated and a new ileostomy was created, there was 30 days hospital stay after reversal. The distribution and percentage of complications according to the Clavien-Dindo classification are shown in (Table 2, 4 and 6). It was seen that 86.7% (13/15) of complications were grade I. There was no statistical difference in complication rate after reversal between the patients with jejunostomy, ileostomy, and colostomy reversal.

The mean age was 30.20 ± 10.08 years.

Types of stoma were 7 jejunostomy, 11 ileostomy and 10 colostomy. Post-operative complications shown in Figure 3, skin excoriation was present in 8 patients (28%), while no patients had stoma retraction or prolapse most of the preoperative complications was dehydration and electrolyte abnormalities present in 5 patients from 7 jejunostomies, ischemic necrosis is present in 2 stomas.

The duration of surgery was 52 ± 0.50 min, no iatrogenic injury occurred. The mean hospital stay was 15.70 ± 2.13 days.

Fifteen (53%) of the 28 patients developed postoperative complications; the most common was surgical wound infection which occurred in eight patients (28.5%).

Twenty-eight patients were included in our study (16 females and 12 males).

There were 22 loop ostomies and 6 end colostomies. After reversal of the 6 end colostomies, complications developed in 83.3% (5/6) of patients: four of them had minor complications and one of them had anastomotic leakage. After loop stoma reversal, minor complications developed in 45.5% (10/22) of patients. Patients with end stoma have significantly much more reversal complications than patients with loop stoma ($p=0.001$).

Mean length of hospital stay

The mean length of hospital stay was (15.70 ± 2.13 days.). There was no relation between length of hospital stay and stoma type (Table 5).

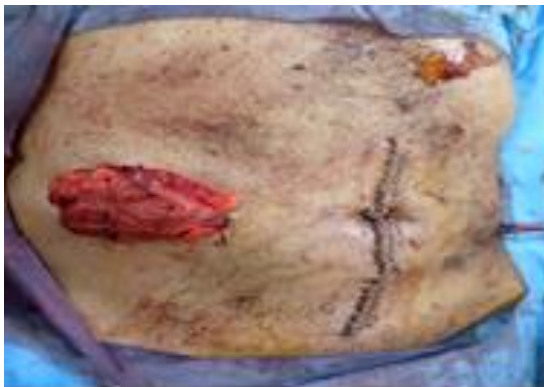

Figure 1: Covering transverse colostomy.

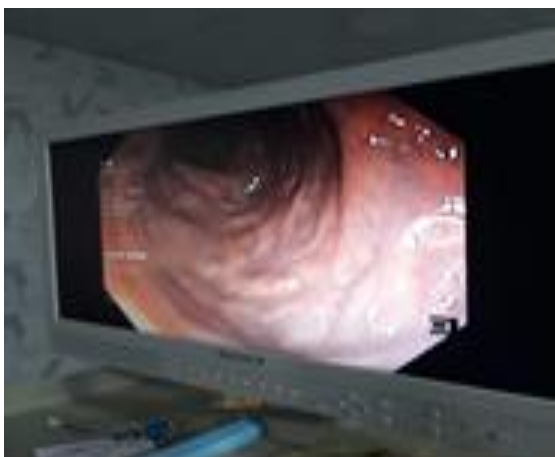

Figure 2: Lower endoscopy of healing of the traumatic distal repair.

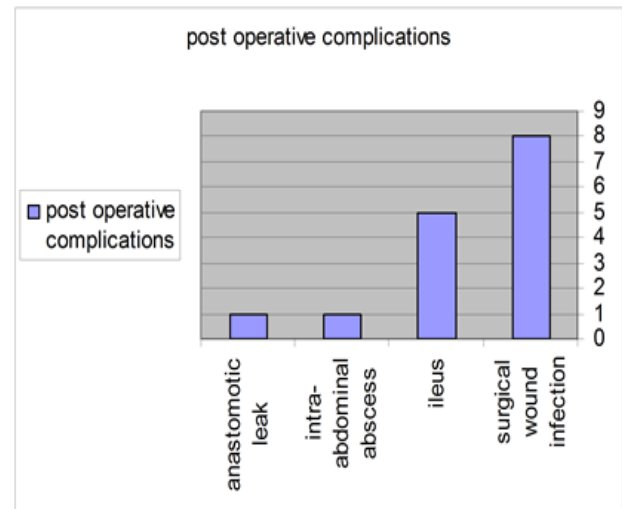


Figure 3: Surgical post-operative complications.

Table 1: Stoma-related complications before stoma reversal (Total 28).

Variables	N
Prolapse	0
Stoma herniation	0
Ischemia/necrosis of stoma	2
Stoma retraction	0
Peristomal skin complications	6
Mucocutaneous separation	0
Dehydration/electrolyte abnormalities	5
TPN nutrition requirement	2
Total stoma-related complication number/total patients	15/28

Table 2: The Clavien- Dindo classification for post-operative complications.

Grades	Definition
Grade 1	Any deviation from the normal postoperative course without the need for pharmacological treatment or surgical, endoscopic and the radiological interventions
Grade 2	Requiring pharmacological treatment
Grade 3	Requiring surgical, endoscopic or radiological intervention under general or without anesthesia
Grade 4	Life threatening complication and multi-organ-dysfunction
Grade 5	Death of a patient

Table 3: Distributions of patient with stoma.

Site of stoma	No. of patients
Proximal	5
Middle	4
Distal	8
Colostomy	11

Table 4: Stoma-related complications before stoma reversal (Total 28).

Variables	N
Prolapse	0
Stoma herniation	0
Ischemia/necrosis of stoma	2
Stoma retraction	0
Peristomal skin complications	6
Mucocutaneous separation	0
Dehydration/electrolyte abnormalities	5
TPN nutrition requirement	2
Total stoma-related complication number/total patients	15/28

Table 5: Reasons for stoma formation.

Variables	N
Fire arm injuries	10
Covering stoma for distal repair	8
Resection–exteriorization of gut gangrene/volvulus	6
Exteriorized other gut perforation	4
Total	28

Table 6: The distribution and percentage of complications according Clavien-Dindo classification (n=28).

Grades	Percentages (%)
Grade I	0
Grade II	13 (45.5)
Grade III	1 (3.5)
Grade IV	1 (3.5)
Grade V	0

Table 7: Length of hospitalization in early stoma closure.

Length of hospital stay (days)	Early stoma closure (n=28)
<10	17
10-20	8
>20	3

DISCUSSION

In the last four decades, there is an increase incidence towards early stoma reversal (at the same admission), this is because of the commonest complications associated with conventional closure (after 3 months), i.e., stoma prolapse, retraction, skin excoriation, difficulty in closure to marked adhesions that developed if the period from stoma creation to its reversal is delayed, psychic trauma to the patient, and delayed return to work etc.,

Temporary de-functioning stoma are either closed after 3 months (conventional closure), or recently early closure

(same admission) closure has gain wide acceptance, due to less morbidity and mortality associated with early stoma reversal, also there is still complications (both surgical and medical) rate; both minor complications ranging from (10-40%) and major complications that may leads to death (0-9%) like ECF and intra-abdominal abscess.

Twenty-eight patients. With temporary de-functioning stoma due to different pathologies (the most common is to protect distal anastomosis). The most common temporary de-functioning stoma created are looped ileostomy and looped colostomy. Stoma has different classifications; according to the part of the gut that has been exteriorized (jejunostomy, ileostomy and colostomy).

It may be end stoma or loope. The most dangerous stoma is jejunostomy especially proximal jejunostomy because it leads to electrolyte imbalance and multiorgan failure. In our study, early stoma closure (same admission) related complications, morbidity, mortality and the waiting time interval of the reversal of the stoma created during GIT operations or abdominal explorations were analyzed in detailed according to stoma type.¹⁰

There are some important differences between stomas created following GIT surgery and the others.¹¹

One of them is that many interventions to the abdomen have to be performed during exploration to overcome peritonitis or to achieve source control. Because of that, intra-abdominal adhesions may be more common after GIT surgery and stoma reversal may be more difficult. The second one is that stoma-related complications are more likely to be encountered in patients with intestinal surgery because of the fact that stoma formation have to be performed in a more challenging situation during abdominal exploration.¹²

Both subjects make reversal time of stoma following abdominal exploration much more critical. If reversal is delayed, the patients would have more stoma-related complications, on the other hand, in our study when reversal is performed early, complication after reversal might decrease due to less intra-abdominal adhesions.¹³

Three main patient categories are among many factors for the development of stoma related complications; patient, type of operation and disease specific issues. The commonest reported patient-specific parameters include age, gender, BMI, nutritional status, ASA score, and corticosteroid use.¹⁴

Emergency stoma creation increase the complication rate and stoma type may also affect the result. Associated chronic diseases, malignancy and obesity also increase the complication rate.¹⁵

Our patients have most of these risk factors; they were elderly, 30% of them had malignancy, and the creation of the stoma in our patients was performed in edematous, fragile bowel with short mesentery under emergent conditions. Because of that, stoma was matured very hardly.¹⁶

Necrosis, Mucocutaneous separation, and retraction may occur more than the elective stoma due to high tension between the bowel mucosa and skin. There were no stoma herniation and prolapse compared to literature in our series because opening the fascia and skin was opened larger or may be the number of our patients are small for judgment, and the most important factor is the short period (10-15 days) to close the stoma is not a sufficient time to allow stoma prolapse or retraction. In many of studies delayed stoma closure and after resolution of edema, prolapses and herniation developed more likely. During surgery period, if stoma is required, colostomy or distal ileostomy is preferred.¹⁷

But in some conditions, jejunostomy, even proximal jejunostomy, has to be created. In our study, jejunostomy had to be done in 7 of them. These seven cases with jejunostomies had more complications related to stoma due to the doing condition of jejunostomy was worse than others.¹⁸

Electrolyte abnormalities, dehydration and need of TPN are more common. In patients with intestinal ostomies especially with proximal jejunostomy, if waiting time interval for reversal of proximal jejunostomy prolongs, patients may develop organ failure. Usually, to get rid of this problem, early stoma reversal may be the only option, although early closure may be more dangerous in such patients. In our cases, the reversal of jejunostomies had to be performed earlier than ileostomy and colostomy, to avoid stoma-related complications. Early stoma closure had less morbidity and mortality in comparison to late reversal patients mentioned in literature. Operation time was longer due to dissection and exploration took more time in the early reversal patients.¹⁹ Creation of stoma and the reversal time of it, is one of the controversies in literature.

Recently, there is an incline towards early closure to decrease the mortality and morbidity specially adhesions developed 3 months after late stoma closure.²⁰

Alves et al, developed an early stoma reversal on postoperative 8 days during same hospital admission to improving the patients' quality of life and preventing possible stoma-related complications with good results. Mengaux et al, also reported the same results with early ostomy reversal within 10 days.²¹

However, some favors a late reversal later 3 months after surgery; they develop a higher morbidity rate in comparison to early reversal before 8.5 weeks, due to

edema of the ileostomy and still-firm intra-abdominal adhesions.²²

In this study, for less waiting time interval, (early closure) instead of delayed stoma formation, there is less mortality and morbidity. Because after delayed stoma formation, several intra-abdominal entries have to be performed and intra-abdominal adhesions will make closure more difficult.

The most difficult stoma creation is Hartmann's procedure, in literature reversal time of gut continuity after Hartmann's procedure was between 40 and 300 days, in some patient's necrosis of the distal stump occurred and the stoma becomes permanent, mean operative time of the operation was 167 min perioperative morbidity with Hartmann's reversal was reported at 4-43% and mortality rate ranges from 5 to 10% (26). In our series, there is one Hartmann's procedure, waiting time interval for the reversal of Hartmann's procedure (2-4 weeks), mean operative time was 125 min without mortality.²³

Before stoma reversal in the waiting period, distal logogram or endoscopic evaluation (Figure 2) must be performed to check the integrity of the distal bowel. We should check distal bowel integrity in any stoma closure, although some surgeons said that it is not necessarily in all cases.²⁴

Although there are lots of data about stoma reversal after colorectal surgery, there is less data about stoma reversal following GIT surgery. According to our knowledge, this is the first report about early stoma closure (same admission) in our department we discuss postoperative stoma-related complications, in comparison to preoperative complications after late stoma reversal.²⁵

One limitation of our study is that the number of patients is small and more studies is needed to confirm our results; our study group includes patients with many different kinds of stoma created at different parts of the bowel with different surgical techniques in distinct challenging clinical situations. However, because of the scarcity of our study group patients we think that our findings may be not dependent upon and in need for more studies, as we mentioned before.

CONCLUSION

The complications of stoma closure post GIT operations are more common during waiting time interval for ostomy reversal. Early stoma closure does not carry an increase more risk of postoperative complications, reduce cost towards stoma care and leads to a significant better QoL. Reversal time may be life threatening especially after jejunostomy due to severe electrolyte imbalance.

For loop stoma done during GIT surgery, the reversal may be performed early (average 8-15 days) without increasing morbidity and mortality.

No need to wait for long time >8 weeks (late closure) even if it is following GIT or open abdomen management surgery.

Funding: No funding sources

Conflict of interest: None declared

Ethical approval: The study was approved by the Institutional Ethics Committee

REFERENCES

- Kwiat M, Kawata M. Avoidance and management of stomal complications. Clin Colon Rectal Surg. 2013;26:112-21.
- Harris DA, Egbeare D, Jones S, Benjamin H, Woodward A, Foster ME. Complications and mortality following stoma formation. Ann R Coll Surg Engl. 2005;87(6):427-31.
- Formijne Jonkers HA, Draaisma WA, Roskott AM, Van Overbeeke AJ, Broeders IA, Consten EC. Early complications after stoma formation: a prospective cohort study in 100 patients with 1-year follow-up. Int J Colorectal Dis. 2012;27(8):1095-99.
- Nastro P, Knowles CH, McGrath A, Heyman B, Porrett TR, Lunniss PJ. Complications of intestinal stomas. Br J Surg. 2010;97(12):1885-9.
- Engel J, Kerr L. Quality of life in rectal cancer patients. A four-year prospective study. Ann Surg. 2010;238:203e13.
- O'Leary DP, Fide CJ, Foy C, Lucarotti ME. Quality of life after low anterior resection with total mesorectal excision and temporary loop ileostomy for rectal carcinoma. Br J Surg. 2001;88:1216-20.
- Thalheimer A, Bueter M, Kortuem M, Thiede A, Meyer D. Morbidity of temporary loop ileostomy in patients with colorectal cancer. Dis Colon Rectum. 2006;49:1011-17.
- Alves A, Panis Y, Lelong B, Dousset B, Benoist S, Vicaud E. Randomized clinical trial of early versus delayed temporary stoma closure after proctectomy. Br J Surg. 2008;95(6):693-8.
- Menegaux F, Jordi-Galais P, Turrin N, Chigot JP. Closure of small bowel stomas on postoperative day 10. Eur J Surg. 2002;168(12):713-5.
- Salman AE, Yetişir F, Aksoy M, Tokaç M, Yildirim MB, Kiliç M. Use of dynamic wound closure system in conjunction with vacuum-assisted closure therapy in delayed closure of open abdomen. Hernia. 2014;18(1):99-104.
- Yetişir F, Salman AE, Aygar M, Yaylak F, Aksoy M, Yalçın A. Management of fistula of ileal conduit in open abdomen by intra-conduit negative pressure system. Int J Surg Case Rep. 2014;9:385-8.
- Danielsen AK, Correa-Marinez A, Angenete E, Skullmann S, Haglind E, Rosenberg J, SSORG (Scandinavian Outcomes Research Group) Early closure of temporary ileostomy-the EASY trial: protocol for a randomised controlled trial. BMJ Open. 2011;1(1).
- Perez RO, Habr-Gama A, Seid VE. Loop ileostomy morbidity: timing of closure matters. Dis Colon Rectum. 2006;49(10):1539-45.
- Mengual-Ballester M, García-Marín JA, Pellicer-Franco E. Protective ileostomy: complications and mortality associated with its closure. Rev Esp Enferm Dig. 2012;104(7):350-54.
- Gastinger I, Marusch F, Steinert R, Wolff S, Koeckerling F, Lippert H. Protective de-functioning stoma in low anterior resection for rectal carcinoma. Br J Surg. 2005;92:1137-42.
- Hüser N, Michalski CW, Erkan M, Schuster T, Rosenberg R, Kleeff J et al. Systematic review and meta-analysis of the role of defunctioning stoma in low rectal cancer surgery. Ann Surg. 2008;248:52-60.
- Montedori A, Cirocchi R, Farinella E, Sciannoneo F, Abraha I. Covering ileo-or colostomy in anterior resection for rectal carcinoma. Cochrane Database Syst Rev. 2010:CD006878.
- Mattheisen P, Hallböök O, Rutegård J, Simert G, Sjødahl R. Defunctioning stoma reduces symptomatic anastomotic leakage after low anterior resection of the rectum for cancer: A randomized multicenter trial. Ann Surg. 2007;246:207-14.
- Gooszen AW, Geerlkerken RH, Hermans J, Lagaay MB, Gooszen HG. Quality of life with a temporary stoma: Ileostomy vs. colostomy. Dis Colon Rectum. 2000;43:650-5.
- O'Leary DP, Fide CJ, Foy C, Lucarotti ME. Quality of life after low anterior resection with total mesorectal excision and temporary loop ileostomy for rectal carcinoma. Br J Surg. 2001;88:1216-20.
- Mala T, Nesbakken A. Morbidity related to the use of a protective stoma in anterior resection for rectal cancer. Colorectal Dis. 2008;10:785-8.
- Rathnayake MM, Kumara SK, Wijesuriya SR, Munasinghe BN, Ariyaratne MH, Deen KI. Complications of loop ileostomy and ileostomy closure and their implications for extended enterostomal therapy: A prospective clinical study. Int J Nurs Stud. 2008;45:1118-21.
- Giannakopoulos GF, Veenhof AA, van der Peet DL, Sietses C, Meijerink WJ, Cuesta MA. Morbidity and complications of protective loop ileostomy. Colorectal Dis. 2009;11:609-12.
- Poon JT, Law WL, Chu KW. Small bowel obstruction following low anterior resection: The impact of diversion ileostomy. Langenbecks Arch Surg. 2004;389:250-5.
- Sprangers MA, Taal BG, Aaronson NK, Te Velde A. Quality of life in colorectal cancer. Stoma vs. non-stoma patients. Dis Colon Rectum. 1995;38:361-9.

Cite this article as: Aldardeer AA, Alsuity A, Mahmoud AG. Early same admission closure of temporary bowel stomas: pros and cons. Int Surg J 2021;8:2669-74.