

Case Report

Nonrotation of gut with nutcracker syndrome: a rare presentation

Saket Jha*, Shahaji Deshmukh, Apoorva Kulkarni, Abhaya Gupta, Paras Kothari

Department of Pediatric Surgery, Lokmanya Tilak Municipal Medical College and Hospital, Mumbai, Maharashtra, India

Received: 04 July 2021

Accepted: 14 August 2021

***Correspondence:**

Dr. Saket Jha,

E-mail: saketjh@gmail.com

Copyright: © the author(s), publisher and licensee Medip Academy. This is an open-access article distributed under the terms of the Creative Commons Attribution Non-Commercial License, which permits unrestricted non-commercial use, distribution, and reproduction in any medium, provided the original work is properly cited.

ABSTRACT

Nutcracker syndrome is a rare diagnosis which presents with hematuria, abdominal pain and is caused by left renal vein entrapment in between abdominal aorta and superior mesenteric artery. Symptomatic presentation of rotational abnormalities of gut are rare in adults though it can present with abdominal pain. Simultaneous presence of nonrotation with nutcracker syndrome was very rarely reported in literature. The authors reported a 38 year old female who presented with chronic pain in left side of abdomen and was diagnosed as nutcracker syndrome with nonrotation of gut. Patient underwent Ladd's procedure with left renal vein transposition. Patient was asymptomatic on follow up. Search of literature showed only two previous cases being reported making it a very rare presentation.

Keywords: Nutcracker syndrome, Nonrotation, Malrotation

INTRODUCTION

Intestinal rotational abnormalities usually present in infancy or paediatric age group, however patients may remain quiescent during childhood and present with symptoms in adulthood or incidentally diagnosed when investigated for other pathologies.

Nutcracker syndrome caused by left renal vein entrapment in acute aorto-mesenteric angle usually presents in second or third decade of life with haematuria, abdominal pain in adult age group both the conditions may present with chronic abdominal pain hence causing a diagnostic and therapeutic dilemma as mere presence of Nutcracker anatomy doesn't constitute presence of Nutcracker syndrome. Presence of both entities in same patient has been rarely reported in literature.¹

CASE REPORT

38 year old female presented with dull aching left lower quadrant pain since 2 years with orthostatic exacerbation and no associated symptoms. The severity of pain was

debilitating to hinder patient's daily routine work. No previous history of any major illness or surgery could be elicited. Patient's appetite was normal with no fever, nausea or vomiting. No history of Koch's contact was there. Patient was married with two children. Patient was lean and thin built, other than this the general survey was unremarkable. Per abdominal examination was unremarkable except for mild left iliac fossa tenderness. Patient had undergone ultrasound examination of abdomen at other institute which showed presence of uncomplicated non rotation of gut. Patient was investigated and diagnosed as having non rotation of gut with nutcracker syndrome. Orthostatic exacerbation of pain suggested nutcracker syndrome as the likely cause of pain. Patient underwent exploratory laparotomy with left renal vein transposition and Ladd's procedure. Post operatively patient was kept on anticoagulant therapy postoperatively and discharged after 1 week.

Investigation

Patient was investigated over 2 years for chronic left sided pain abdomen, underwent CECT abdomen twice

which revealed nonrotation of gut with appendix and larger bowel on the left and small bowel on the right side of abdomen. Presence of few Ladd's bands and absence of retromesenteric third segment of duodenum which was not passing to the left of the spine. Reduced aortomesenteric angle of 32.9 degrees was noted on CT. Superior mesenteric artery and vein axis was slightly inverted with vein anterior to artery.

Renal Doppler ultrasound revealed a dilated left renal vein of 9.8 mm diameter and dilated left gonadal vein of 6 mm diameter. Aorto-mesenteric angle on renal Doppler was 26 degrees.

All other investigations including routine blood investigations and urine routine examination were normal.

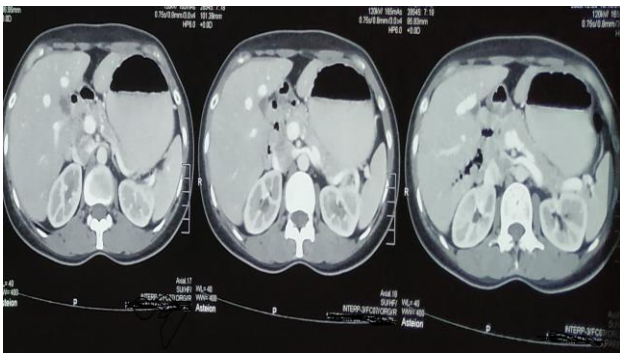


Figure 1: CT abdomen showing a dilated left renal vein entrapped between aorta and superior mesenteric artery.

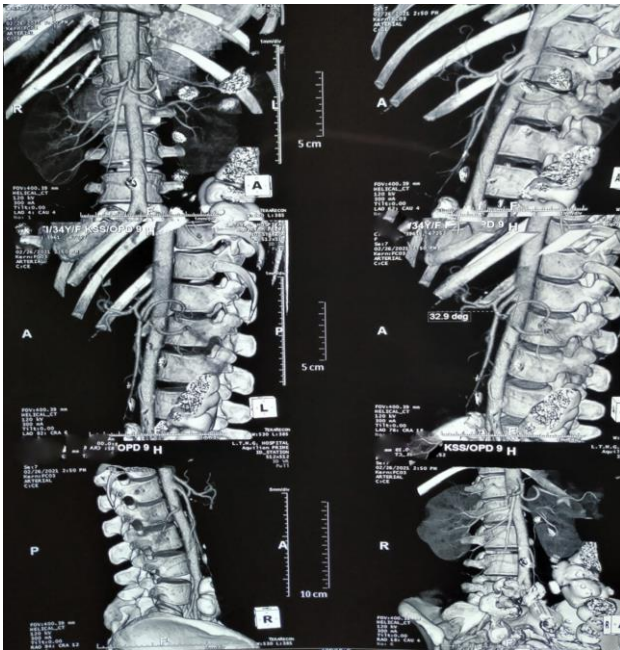


Figure 2: 3D reconstruction of CT abdomen showing a reduced aortomesenteric angle.

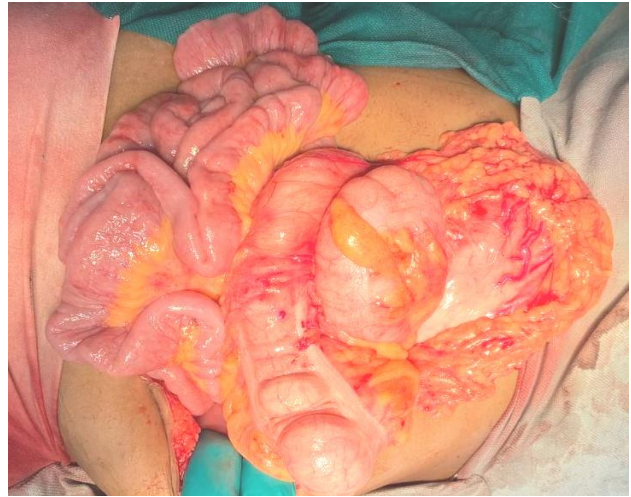

Figure 3: Intraoperative photo showing nonrotation of gut with large bowel on left and small bowel on right; standard midline incision laparotomy was performed and few Ladd's band encountered were divided, inversion appendectomy and left medial visceral rotation was done to expose left kidney and renal vessels, left renal vein and gonadal vein found dilated; left renal vein transposition caudally by about 5 cms was performed.

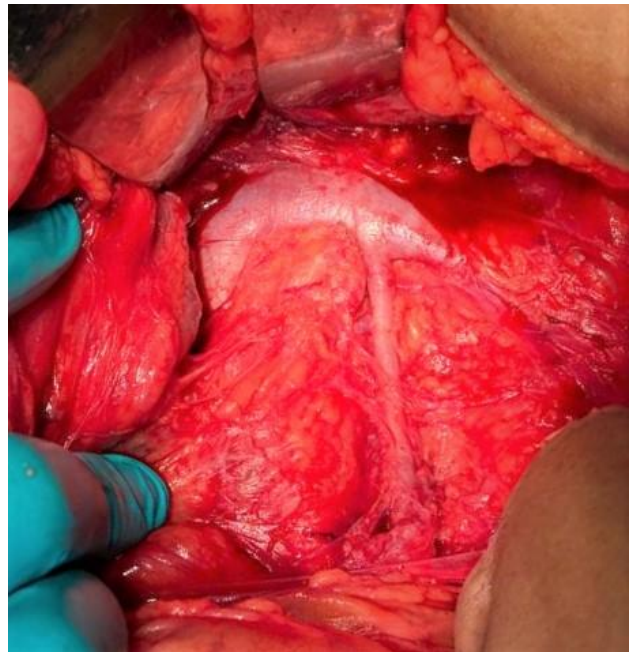


Figure 4: Intraoperative photo showing dilated left renal vein and left gonadal vein.

Differential diagnosis

Symptomatic non rotation of gut with Ladd's band, nonrotation of gut with subacute appendicitis and nutcracker syndrome were considered as differential diagnosis after excluding pelvic inflammatory syndrome or other gynaecological disorders by clinical examination and ultrasonography.

Treatment

Patient underwent exploratory laparotomy with left renal vein transposition and Ladd's procedure.

Outcome and follow up

Patient tolerated procedure well and was kept on anticoagulant therapy for 6 weeks postoperatively, discharged on postoperative day 7.

The patient was symptom free on 12 weeks follow up.

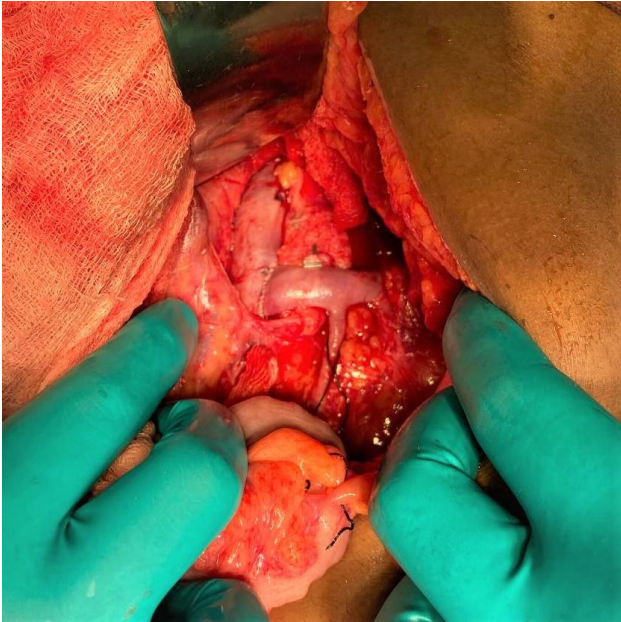


Figure 5: Intraoperative photo showing transposed left renal vein anastomosed to IVC and ligated left adrenal vein.

DISCUSSION

Incidence of rotational abnormalities of gut diagnosed in adults was 0.2%, however symptomatic presentation was very rare.^{5,6} Nutcracker phenomenon pertained to presence dilated distal left renal vein due to entrapment in between SMA and abdominal aorta.

Left renal vein compression can be caused by high course of left renal vein, abnormal SMA, excessive fibrosis at aortomesenteric angle, retroperitoneal lymphadenopathy or tumours.

There was lack of consensus regarding severity of symptoms to warrant a diagnosis of nutcracker syndrome as Nutcracker anatomy can be presented without symptoms.³ The diameter of left renal vein was not uniform and distal diameter was greater compared to proximal. Average normal diameter of left renal vein was considered to be 4-5 mm. The normal gonadal vein diameter was considered to be approximately 3 mm³. Buschi et al analyzed computed tomographic (CT),

ultrasonographic and pathologic data in a series of 72 random patients, showing that the ratio of LRV diameters of the distended to the narrowed portions (LRVD/N) may reach 4:1. The normal LRV hypertension occurred when the gradient was 3.0 mm Hg.⁴ The left renal vein diameter was 9.8 mm and left gonadal vein was 6 mm in this patient. Both Nutcracker syndrome and nonrotation of gut can present with chronic abdominal pain, though commonest symptom with nutcracker syndrome was haematuria. Moreover abnormal orientation of SMA and SMV axis and presence of Ladd's bands in nonrotation of gut may be the cause of acute aortomesenteric angle. Operative treatment of nutcracker syndrome was required for severe debilitating symptoms surgical options included left renal vein transposition, left renal vein bypass, SMA transposition, left renal vein to IVC shunt, and even nephrectomy.³ Surgical management of intestinal malrotation was first described by Ladd in 1936 and remained the mainstay of surgical management.

Spigland et al opined surgical management of even asymptomatic malrotation as anatomical abnormalities which can complicate the condition do not change with increasing age, hence potential for volvulus always exist.⁷

The patient in this case report had a left flank and lower quadrant pain which can be both due to Nutcracker and malrotation. Orthostatic exacerbation favoured pain due to Nutcracker syndrome. The diagnosis was further supported by imaging and USG which showed acute aortomesenteric angle and dilated left renal vein. Hence patient underwent Ladd's procedure with left renal vein transposition.

Search of literature found only two previous case reports of intestinal malrotation with Nutcracker syndrome.

Panchal et al reported incidentally found Nutcracker phenomenon in a 28 year old female who underwent exploratory laparotomy for malrotation of gut.²

Nishio et al reported similar findings in a 12 year old male though the case was managed by only Ladd's procedure.¹

CONCLUSION

Both Nutcracker syndrome and malrotation in adults are rare diagnosis and require high index of suspicion to diagnose.

Definitive clinical diagnosis is difficult due to presence of non-specific signs and symptoms and high incidence of clinical suspicion is required for the diagnosis and management of such cases.

Radiological investigations are of utmost importance in deciding upon the course of management of such cases.

Funding: No funding sources

Conflict of interest: None declared

Ethical approval: Not required

REFERENCES

1. Nishio Y, Kawano Y, Hara S. Nutcracker syndrome complicated with intestinal malrotation. *BMJ Case Rep.* 2019;12(10):231230.
 2. Kumar PNH, Shah D, Priyanka CB. Unusual presentation of midgut malrotation with incidental nutcracker syndrome in adulthood: case report and literature review. *BMJ Case Rep.* 2012;2012:0320126010.
 3. Kurklinsky AK, Rooke TW. Nutcracker phenomenon and nutcracker syndrome. *Mayo Clin Proc.* 2010;85(6):552-9.
 4. Buschi AJ, Harrison RB, Norman A, Brenbridge AG, Williamson BR, Gentry RR, et al. Distended left renal vein: CT/sonographic normal variant. *AJR Am J Roentgenol.* 1980;135(2):339-42.
 5. Flüe M, Herzog U, Ackermann C, Tondelli P, Harder F. Acute and chronic presentation of intestinal nonrotation in adults. *Dis Colon Rectum.* 1994;37(2):192-8.
 6. Wang CA, Welch CE. Anomalies of intestinal rotation in adolescents and adults. *Surgery.* 1963;54:839-55.
- Spigland N, Brandt ML, Yazbeck S. Malrotation presenting beyond the neonatal period. *J Pediatr Surg.* 1990;25(11):1139-42.

Cite this article as: Jha S, Deshmukh S, Kulkarni A, Gupta A, Kothari P. Nonrotation of gut with nutcracker syndrome: a rare presentation. *Int Surg J* 2021;8:2819-22.