

Case Report

Coexistence of thymoma and necrotizing pneumonia: a case report with a fatal outcome

Jefferson Fabian Nieves-Condoy^{1*}, Camilo Levi Acuña-Pinzón¹, Salvador Narváez-Fernández²,
José Luis Chavarría-Chavira¹, Bruno Crocco-Quirós¹, Daniel Agustín Rivera-Márquez¹

Department of ¹Surgery, ²Chest Surgery, Bajío Regional High Specialty Hospital. León, Guanajuato, Mexico

Received: 23 June 2021

Revised: 07 August 2021

Accepted: 10 August 2021

*Correspondence:

Dr. Jefferson Fabian Nieves-Condoy,

E-mail: jeffnc.md@gmail.com

Copyright: © the author(s), publisher and licensee Medip Academy. This is an open-access article distributed under the terms of the Creative Commons Attribution Non-Commercial License, which permits unrestricted non-commercial use, distribution, and reproduction in any medium, provided the original work is properly cited.

ABSTRACT

Thymoma is an entity with an estimated incidence of 1.2-3.2 per million people, with a prognosis and treatment determined by its clinical stage and histological classification, the most widely used classification systems being the Masaoka-Koga for clinical stage and that of the world health organization (WHO) for histology. Necrotizing pneumonia is another rare entity that was initially described in adults in the 1940s; however, it is currently being studied more extensively in the pediatric setting, and currently its treatment, especially in adults, is unclear and surgical treatment usually reserved in the presence of complications and poor response to medical management. The coexistence of two rare entities is a problem for which therapeutic options are limited; the general condition of the patient is a determining factor in the outcome in a critically ill patient. In the present case, the association of two infrequent entities is reported, which presented a pneumothorax as a complication that required placement of an endo-pleural tube for drainage, pre-surgical biopsy a B1 thymoma was reported. The post-surgery pathology report was an encapsulated thymoma, WHO type A, the broad-spectrum antibiotic management did not prevent the dissemination of the septic focus in the context of a patient with malnutrition and immunosuppression.

Keywords: Thymoma, Necrotizing pneumonia, Epithelial tumors of the thymus

INTRODUCTION

Thymus epithelial tumors (TET) and necrotizing pneumonia (PN) are two rare entities, with an estimated incidence of 1.2-3.2 per million people for TET and 0.8%-7% of community-acquired pneumonia (CAN) of pediatric tertiary centers for PN, however the picture is unclear in adulthood. Both increase morbidity.¹

The thymoma (T) according to its clinical stage determined by Masaoka classification, and classification of the world health organization (WHO), determines the treatment and prognosis; however, treatment of necrotizing pneumonia is less clear, partly due to absence of large studies that determine a standardized treatment, so it is referred to small case series.^{2,3}

The coexistence of two rare entities limits the therapeutic options due to the lack of standardization of treatment options with proven efficacy. The prognosis depends on multiple factors derived in part from the general conditions of the patient.

CASE REPORT

A 55-year-old man with no history of previous chronic degenerative diseases, at the initial evaluation, he presented protein-calorie malnutrition, mucocutaneous mycosis in the feet, inguinal region, and oral cavity. Surgical history of varicocele; denies allergies, consumption of tobacco or illicit drugs and transfusions of blood components, he has worked in textile manufacturing for 25 years.

Presented with a history of persistent cough for 7 months, productive with initially green expectoration that recently changes to brown, denies hemoptysis, presents weight loss of approximately 30 kg, hypoxia, asthenia. Physical examination revealed an exfoliative skin lesion, oxygen saturation (Sat. O₂) 92%, heart rate 100 per minute, weight of 49 kg.

Computed tomography (CT) shows an intrathoracic tumor with two components, one involving the pulmonary apex and right middle mediastinum measuring 107x85 mm and the other in the right cardiac mediastinum measuring 89x53 mm (Figure 1 A and B).

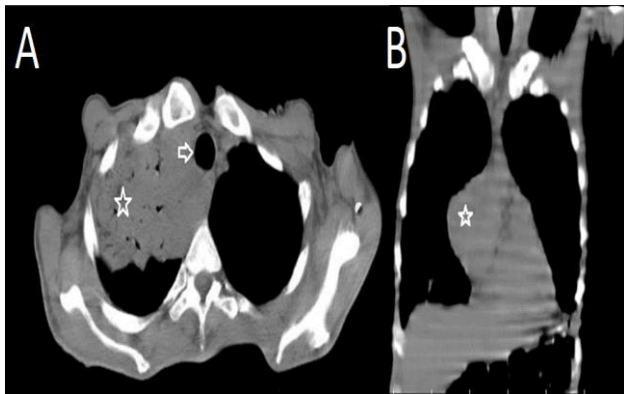


Figure 1: Chest CT mediastinal window-(A) Axial section, evidence of a tumor involving the right pulmonary apex with extension to the mediastinum (star), intimate contact with the airway, but without its obstruction with patent trachea (arrow). (B) Coronal section, which shows mediastinal involvement for the right heart.

A biopsy outside our center was performed; In lamellae revision, according to the WHO classification, reported a type B1 thymoma rich in lymphocytes with mild fibrosis, hyaline change without necrosis.

He presented sudden dyspnea at rest and acute chest pain, CT showed destruction of the right apical lung parenchyma, a 40% right hydropneumothorax associated with lower right lobar collapse (Figure 2), a right endopleural tube was placed, Pleural fluid was analyzed and cultured, which reported sensitive oxacillin S. epidermidis. He was admitted to hospital and laboratory tests were performed (Table 1).

A right thoracotomy for suspected rupture of lung abscess with bronchopleural fistula plus tumor biopsy was scheduled. During which apical adherence to the chest wall was evidenced, which was dissected and showed an anterior mediastinal tumor with cardiac extension, necrotizing pneumonia in segment 8 with opening to the pleura encapsulating empyema with an approximate volume of 100 ml. Mediastinal tumor resection, right upper lobectomy, basal segment decortication, resection of necrotic tissue from basal pneumonic focus, and fistula

repair were performed. Samples were sent for pathological study (Table 2).

Table 1: Laboratory tests.

Admission labs	
Creatinine (mg/dl)	0.3 (NV 0.52-1.04)
Urea (mg/dl)	32.1 (NV 15.0-36.0)
Na (mmol/l)	134 (NV 137-145)
K (mmol/l)	3.8 (NV 3.5-5.1)
Cl (mmol/l)	93 (NV 98-107)
Mg (mg/dl)	2.2 (NV 1.6-2.3)
Glucose (mg/dl)	80 (NV 74-106)
Erythrocytes (ul)	4.04x10 ⁶ (NV 4.10-5.10)
Hemoglobin (g/dl)	11.4 (NV 12.3-15.3)
Hematocrit	33.5% (NV 36-45)
Medium corpuscular volume (MCV) (fL)	83.0 (NV 80.0-100.0)
Average hemoglobin concentration (AHC) (pg)	28.2 (NV 26.3-33.8)
RDW (%)	13.97
Leukocytes (ul)	8.38x10 ³ (NV 4.40-11.30)
Neutrophils (%)	53
Lymphocytes (%)	41
Monocytes (%)	0.4
Basophils (%)	0.1
Platelets (ul)	249x10 ³
Total protein (g/dl)	5.0
Albumin (g/dl)	2.5 (NV 3.5-5.0)
Total bilirubin (mg/dl)	0.6 (NV 0.2-1.3)
Direct bilirubin (mg/dl)	0.3 (NV 0.3)
Alkaline phosphatase (U/l)	194 (NV 36-126)
TGO (U/l)	48 (NV 17-59)
TGP (U/l)	44 (NV 21-72)
Prothrombin time (PT)	14 segundos (NV 9.8-12.8)
INR	1.05 (NV 1.5-2.5)
Patial thromboplastin Time (PTT)	28.5 (NV 22.5-33.5)
Hepatitis C antibodies (Ac-HCV)	Negative
anti-HIV antibodies	Negative
Hepatitis B surface antigen (HBsAg)	Negative

Table 2: Histopathological report of samples.

Variables	
Pleura	Negative for malignant neoplastic cell. Acute abscessed chronic pachypleuritis
Mediastinal tumor*	Type A thymoma. encapsulate, without necrosis
Lung lobe	Acute abscessed chronic inflammation. Five lymph nodes with anthracosis.

*WHO Classification

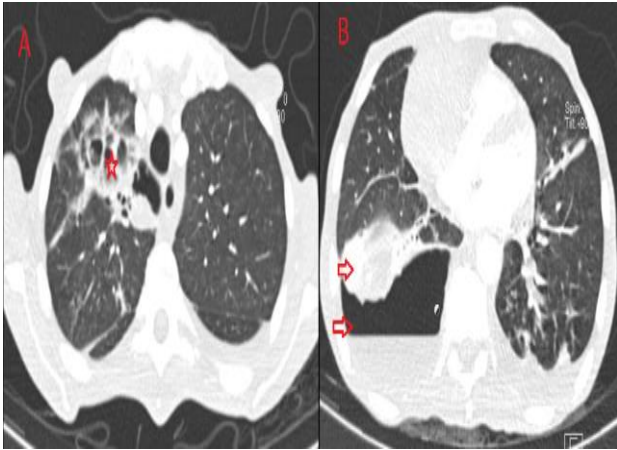


Figure 2: Chest CT lung window-(A) Axial section, showing destruction of the lung parenchyma (red star). (B) Axial section showing hydropneumothorax in basal segments of the right lung (red down arrow) with adjacent parenchyma collapse (red up arrow).

He was admitted to the intensive care unit where he stayed intubated for 5 days, due to hemodynamic instability due to septic shock, the culture of the bronchial aspirate showed gram-negative bacilli, negative galactomannan, due to the associated risk factors and imaging characteristics, a broad-spectrum antibiotic and antifungal were started. Later, *Pseudomonas aeruginosa* was identified and antibiotic treatment was adjusted.

He was successfully extubated, but presented progressive respiratory deterioration, requiring reintubation, an early tracheostomy was performed and a naso-jejunal tube was placed for enteral feeding. It presented with fever and renal and respiratory deterioration, antibiotic treatment with quinolone with activity against *Pseudomonas* was adjusted; A chest X-ray was performed showing diffuse multinodular infiltrate; A CT scan was performed in which consolidation foci suggestive of multiple areas of pneumonia are identified with different characteristics that, due to patient's condition, are suspected of pyogenic infection added to fungal etiology, infectious disease specialist adjusted management by escalating antibiotic therapy and antifungal therapy; however, it rapidly deterioration was seen and patient died within 48 hours.

DISCUSSION

Thymus epithelial tumors (ETTs) are rare entities, with a reported annual incidence of 1.2-3.2 per million. They are divided into thymomas (T) and thymic carcinoma (TC), the most common being thymoma, which corresponds to between 85%-95% of cases and TC to 5%-15%. Mean age at diagnosis is 53 years for T and 54 years for TC.¹

Due to the wide use of tomography, many patients with thymomas are discovered incidentally through this study. When they present symptoms, they are usually related to compression or invasion of adjacent tissues, manifesting

as dysphagia, diaphragmatic paralysis, or superior vena cava syndrome. It can also debut as a paraneoplastic syndrome, most of which are myasthenia gravis, others such as hypogammaglobulinemia/pure RBC aplasia occur in 10% and 5% respectively. Between 30-50% of patients with thymoma have myasthenia gravis, but only 10-15% of patients with myasthenia gravis have thymoma.²

Classically, two classification systems are used for TETs on the basis that they have been shown to correlate with outcomes. The Masaoka system proposed in 1981 and later modified by Koga, classifies them according to the degree of invasion of the neoplasia to the capsule and adjacent tissues, stage I corresponds to encapsulated T, stage IIa corresponds to microscopic invasion of the capsule, IIb to macroscopic invasion of extra-thymic fat without infiltration of the pleura or pericardium, stage III to invasion of adjacent organs such as the pericardium, great vessels, or lung, and stage IV to lymphatic or hematogenous dissemination.³ This classification has shown a correlation between stage and survival at 5 years, stages I, II and III together report an overall survival of 85% at 5 years, and stage IV 65%. The WHO published a classification system according to the morphology of the epithelial cells and the lymphocyte/epithelial cell index and classifies them as: A medullary thymoma, AB mixed thymoma, B1 predominantly cortical thymoma, B2 cortical thymoma, B3 well-differentiated thymic carcinoma and C thymic carcinoma, considering A, AB and B1 as low risk and B2, B3 and C as high risk. However, the TNM staging system was developed based on a retrospective database of 10808 cases from 105 institutions around the world, which is correlated with overall survival.²

The treatment of choice is surgery when complete resection is possible. Radiation therapy is adopted in advanced stages, mainly when they invade adjacent tissues or as an adjunct in cases of residual R1-R2 tumors after surgery; and chemotherapy is currently considered the standard when for metastatic stages, or inoperable or recurrent disease, but there is no standard of treatment after the first line of treatment.⁴ Staging can be modified after surgical treatment, mainly due to the limitation of the imaging studies and the amount of sample size for the histopathological study, conditioning a change in the prognosis and perhaps the treatment according to the extent of the disease and its degree of differentiation; in this case, the coexistence of two entities that increase morbidity in isolation and whose association does not have prognostic evidence, therapeutic options are limited.

PN was first described in adults in the 1940s, and 50 years later in children; In the United States, necrotizing pneumonia has been reported in 0.8%-7% of community-acquired pneumonia in tertiary care centers.⁵

PN is characterized by inflammation of the lung parenchyma with consolidation of peripheral necrosis and formation of multiple cavitated lesions. The necrotic

tissue alters the distribution of antibiotics to the affected tissue with progression of the infection that can be complicated by bronchopleural fistula. It has been described as a predictor of long hospital stay and with more severe clinical manifestations and a greater need for pleural drainage.⁶ In the case presented, a hydropneumothorax with collapsed lung lobe that required pleural drainage was presented, the culture of which showed the infectious etiology of one of the processes that conditioned the poor general condition of the patient, after which it presented greater deterioration.

CT is considered better for the evaluation of PN since radiography underestimates the destruction of the lung parenchyma; *Klebsiella pneumoniae*, *Pseudomonas aeruginosa* and *S. pneumoniae* have been described as main etiological agents, although the frequency of their etiology may differ according to the age and conditioning factors of the patient; thus factors associated with immunosuppression as in this patient may be associated with gram negative bacteria or isolation of more than one etiological agent.⁵

Long-term lung function decline (assessed by spirometry) has been evidenced in patients who have undergone PN and who have undergone surgical intervention, its association being less clear when surgical treatment is not performed. However, long-term follow-up of patients who had PN is suggested since children with a history of PN appear to have a mild alteration in lung function.⁷

The surgical treatment of necrotizing pneumonia is a subject of debate due to the high mortality of patients due to sepsis and it is suggested to stabilize them prior to surgical treatment that can be approached by percutaneous drainage, thoracoscopy/open surgery, to perform decortication, resection with/without debridement, segmentectomy, lobectomy/pneumonectomy; however, surgical treatment is limited to specific complications such as significant and persistent hemoptysis, abscess, empyema, and pulmonary gangrene.⁸ The surgical treatment chosen in this patient was based on the limitation of the tumor disease that was later corroborated in the biopsy, and the presence of complications of PN with pneumothorax with persistent fistula and the progressive deterioration of the general condition.

CONCLUSION

Thymoma and PN 2 rare entities that increase morbidity. Treatment of stage I, II thymoma and, in selected cases,

Masaoka stage III is surgical. However, surgical indication for PN is less clear and is usually reserved for complications, with poorly defined prognosis. In patients with a state of immunosuppression they can increase mortality and determine a therapeutic challenge.

Funding: No funding sources

Conflict of interest: None declared

Ethical approval: Not required

REFERENCES

1. Rioja P, Ruiz R, Galvez-Nino M, Lozano S, Valdiviezo N, Olivera M et al. Epidemiology of thymic epithelial tumors: 22-years experience from a single-institution. *Thorac Cancer*. 2021;12(4):420-5.
2. Benveniste MFK, Betancourt Cuellar SL, Carter BW, Strange CD, Marom EM. Thymic Epithelial Neoplasms. *Radiol Clin North Am*. 2021;59(2):183-92.
3. Huang J, Detterbeck FC, Wang Z, Loehrer PJ. Standard outcome measures for thymic malignancies. *Zhongguo Fei Ai Za Zhi*. 2014;17(2):122-9.
4. Scorsetti M, Leo F, Trama A, D'Angelillo R, Serpico D, Macerelli M et al. Thymoma and thymic carcinomas. *Crit Rev Oncol Hematol*. 2016;99:332-50.
5. Krutikov M, Rahman A, Tiberi S. Necrotizing pneumonia (aetiology, clinical features and management). *Curr Opin Pulm Med*. 2019;25(3):225-32.
6. Seo H, Cha S-I, Shin K-M, Lim J-K, Yoo S-S, Lee J et al. Clinical relevance of necrotizing change in patients with community-acquired pneumonia. *Respirology*. 2017;22(3):551-8.
7. Bover-Bauza C, Osona B, Gil JA, Peña-Zarza JA, Figuerola J. Resultados a largo plazo de la neumonía necrotizante. *An Pediatr*. 2020;S1695-4033(20)30292-7.
8. Reimel BA, Krishnadasen B, Cuschieri J, Klein MB, Gross J, Karmy-Jones R. Surgical Management of Acute Necrotizing Lung Infections. *Can Respir J*. 2006;13(7):369-73.

Cite this article as: Nieves-Condoy JF, Acuña-Pinzón CL, Narváez-Fernández S, Chavarría-Chavira JL, Crocco-Quirós B, Rivera-Márquez DA. Coexistence of thymoma and necrotizing pneumonia: a case report with a fatal outcome. *Int Surg J* 2021;8:2776-9.