

Research Article

Olecranon bone grafting in neglected forearm fractures

Ashish Kumar Jose*, Surendher Kumar R.

Department of Orthopaedics, Mahatma Gandhi Medical College, Pillaiyarkuppam, Pondicherry, India

Received: 10 September 2015

Revised: 21 September 2015

Accepted: 07 October 2015

*Correspondence:

Ashish Kumar Jose,

E-mail: joseashish@yahoo.co.in

Copyright: © the author(s), publisher and licensee Medip Academy. This is an open-access article distributed under the terms of the Creative Commons Attribution Non-Commercial License, which permits unrestricted non-commercial use, distribution, and reproduction in any medium, provided the original work is properly cited.

ABSTRACT

Background: Autogenous bone grafts are widely used to augment union in fractures. Of all the available donor sites, the iliac bone grafts are the most commonly used. Olecranon bone grafts are rarely used to augment union in long bone fractures along with plate osteosynthesis.

Methods: Twenty patients of which 18 were male and 2 were female with 9 injuring their right side and 11 injuring their left side, were treated in Mahatma Gandhi Medical College, Pillaiyarkuppam, Pondicherry, India, during the period from January 2012 to December 2014. The fractures were classified as neglected if the duration was more than 4 weeks after the injury. The reason for delay in seeking treatment was indigenous treatment by native bone setters.

Results: All had complete union at an average of 3 months (2 and half - 4 months). All had complete range of elbow and wrist flexion and extension by 1 month. No patient complained of bone graft donor site pain. The outcome was excellent and all the fractures united at an average time of 3 months. There was no donor site morbidity.

Conclusions: Despite lack of popularity, olecranon bone grafts are an excellent option for augmenting union in fractures of the forearm as these grafts are easily obtained and cause no donor site complications.

Keywords: Olecranon bone graft, Forearm fracture

INTRODUCTION

Skeletal healing is a biological process that depends on cellular response. Despite the vast progress in fracture fixation techniques, the methods of bone grafting still remain the same as Phemister described more than half a century ago.¹ Autogenous cancellous bone grafts have been traditionally used to augment union in various fractures of upper and lower extremities. The donor sites are iliac crest, greater trochanter of the femur, femoral condyle, proximal tibial metaphysis, medial malleolus of the tibia, olecranon and distal radius. With the use of bone substitutes and the donor site morbidity associated with iliac crest site, the enthusiasm in autogenous iliac cancellous bone graft as an augment is dwindling.^{2,3} In fractures of the upper extremity, olecranon grafts can be used as it is advantageous compared to other donor sites

and bone substitutes. There are only a few reports on the use of olecranon bone grafting in upper extremity fracture. We prospectively studied the use of olecranon bone grafts in neglected diaphyseal fractures of both bones of forearm in terms of clinical and radiological outcome and also the complications associated with the harvesting and use of olecranon bone grafts.

METHODS

During the period from January 2012 to December 2014, 20 patients with neglected forearm fractures (both bones) were treated in our hospital (Figure 1). For the purpose of the study, the fractures were classified as neglected if the duration was more than 4 weeks after the injury. The reason for delay in seeking treatment was indigenous treatment by native bone setters. All the patients were

treated with open reduction and internal fixation using 3.5 mm dynamic compression plate (DCP) and augmentation by olecranon bone grafting (Figure 2).

Of the 20 patients, 18 were male and 2 were female with 9 injuring their right side and 11 injuring their left side. The mechanism of injury was road traffic accident in 12 patients and fall from height in 8 patients.

Shoulder pendulum exercises & elbow and wrist flexion and extension exercises were started from the next day of surgery. The patients were given intravenous antibiotics for 24 hours postoperatively. Wound inspection and dressing was done on 2nd and 5th post-operative days. Sutures were removed on the 12th post-operative day. All the patients were serially followed up at 6 weeks, 3 months and 6 months.

The patients were allowed light activities once the callus formation was noticed in the radiograph and slowly progressed to their pre-injury level at approximately 3 months, when complete union of fracture was noticed.

Surgical technique

The patients were given regional block, either interscalene or supra-clavicular. The radius was approached by the anterior Henry's approach and the ulna was exposed subcutaneously. The fracture was identified, the ends debrided, reduction achieved and fixed with DCP. Then the olecranon graft was harvested from the ipsilateral upper extremity. The olecranon was approached by a 4 cm incision posteriorly and the bone was exposed directly. An oval window was made in the posterior cortex of the olecranon and the graft was harvested. The graft thus harvested was applied at the fracture site. The quantity of graft was found to be adequate in all the patients. The periosteum was sutured back to prevent irregular callus formation.

RESULTS

The patients were followed up regularly at 6 weeks, 3 months and 6 months initially and thereafter once every 6 months. All had complete union at an average of 3 months (2 and half - 4 months). All had complete range of elbow and wrist flexion and extension by 1 month. No patient complained of bone graft donor site pain. No infections were encountered in any of these patients either in fracture site or graft donor site. 1 patient had weakness of thumb extension post operatively which spontaneously recovered after 3 months.

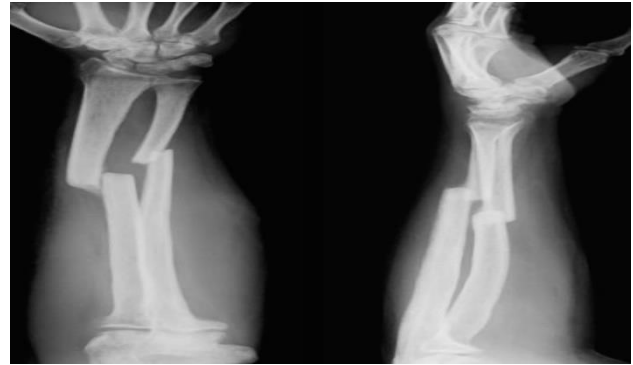


Figure 1: Pre-operative X-Ray.

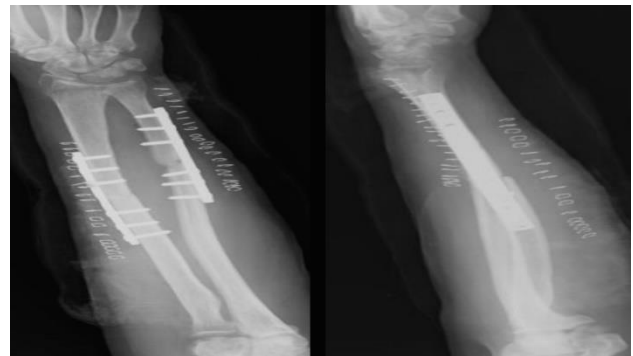

Figure 2: open reduction and fixation with 3.5mm DCP and augmentation by olecranon bone graft.

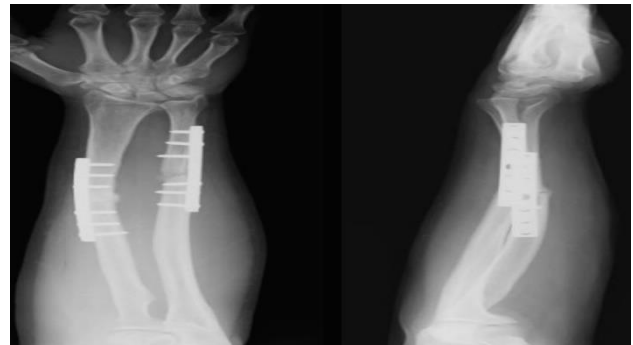


Figure 3: 6 weeks post-operative x-ray.

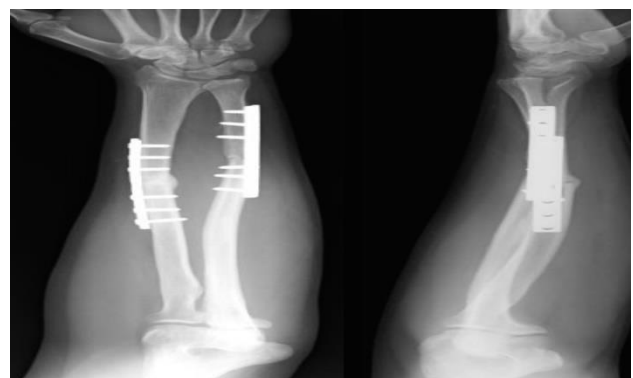


Figure 4: 3 Months post-operative x-ray.

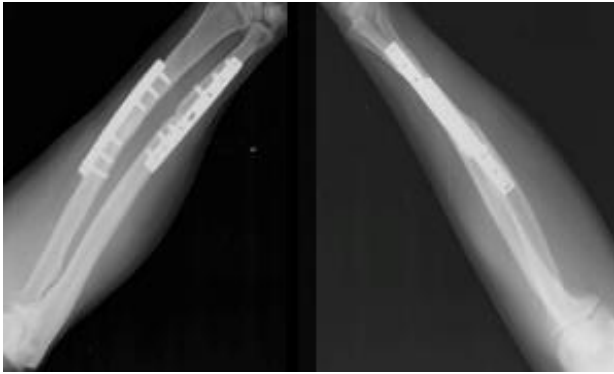


Figure 5: 3 Months post-operative x-ray.

DISCUSSION

Autogenous bone grafts are commonly used for various fractures and non-union as an augmentation along with open reduction and internal fixation. The donor sites are iliac crest, greater trochanter of the femur, femoral condyle, proximal tibial metaphysis, medial malleolus of the tibia, olecranon, and distal radius. The advantages of the iliac cancellous bone grafting include the abundant quantity of cancellous grafts with maximum osteogenic potential and availability of cortico-cancellous bone graft. The disadvantages are many such as pain at the donor site, infection, cosmetic deformity, discomfort in wearing the lower garments, injury to ilio-inguinal nerve and lateral femoral cutaneous nerve, arterial injury, hernia due to incomplete closure and the altered gait in some patients. The olecranon bone grafts are advantageous in that they have no pain at the donor site and can be harvested from the same upper extremity. Thus the whole procedure can be done with a single anesthetic block in the upper extremity. The limitations being paucity of graft and theoretical possibility of fracture. They also have the benefit of rapid re-vascularization.⁴ There are very few reports about the use of olecranon bone grafts.^{5,6} We prospectively studied the patients with neglected fracture of both bones of forearm treated with open reduction and internal fixation and olecranon bone grafts. We had excellent outcome in all the patients and encountered no donor site morbidity.

CONCLUSION

The outcome of treating neglected forearm fractures with olecranon bone grafts was very good. The fractures

united within an average time of 3 months and all the patients progressed to their pre-injury level of function. The main advantage of olecranon graft is that it can be done under one regional anesthetic procedure such as inter-scalene or axillary block. Despite lack of popularity, olecranon bone grafts are an excellent option for augmenting union in fractures of the forearm as these grafts are easily obtained and cause no donor site complications.

ACKNOWLEDGEMENTS

We acknowledge the support of our colleagues from the department of Orthopaedic Surgery and all the patients who participated in the study.

Funding: No funding sources

Conflict of interest: None declared

Ethical approval: Not required

REFERENCES

1. Phemister DB. Treatment of ununited fractures by onlay bone grafts without screw or tie fixation and without breaking down of the fibrous union. J Bone Joint Surg. 1947;29-A or B:946-60.
2. Arrington ED, Smith WJ, Chambers HG, Bucknell AL, Davino NA. Complications of iliac crest bone graft harvesting. Clin Orthop Relat Res. 1996;329:300-9.
3. Goulet JA, Senunas LE, DeSilva GL, Greenfield ML. Autogenous iliac crest bone graft. Complications and functional assessment. Clin Orthop Relat Res. 1997;339:76-81.
4. Mersa B, Ozcelik IB, Kabakas F, Sacak B, Aydin A. Olecranon bone graft: revisited. Tech Hand Up Extrem Surg. 2010;14(3):196-9.
5. Ozcelik IB, Kabakas F, Mersa B, Purisa H, Sezer I, Ertürer E. Treatment of non unions of the distal phalanx with olecranon bone graft. J Hand Surg Eur. 2009;34(5):638-42.
6. Babushkina A, Edwards S. Cortico cancellous olecranon autograft for metacarpal defect reconstruction: a case report. HAND. 2012;7(4):457-60.

Cite this article as: Jose AK, Kumar S. Olecranon bone grafting in neglected forearm fractures. Int Surg J 2015;2:620-2.