

## Case Report

# Hydatid disease with pseudo-aneurysm formation of the descending thoracic aorta: a case report

Ruqia Mushtaq<sup>1</sup>, Fatima Rauf<sup>1\*</sup>, Muhammad Hanif<sup>2</sup>, Aqsa Ameer<sup>3</sup>

<sup>1</sup>Department of General Surgery, Benazir Bhutto Hospital, Rawalpindi, Pakistan

<sup>2</sup>Department of Surgery, Benazir Bhutto Hospital, Rawalpindi, Pakistan

<sup>3</sup>Rawalpindi Medical University, Rawalpindi, Pakistan

**Received:** 21 June 2021

**Accepted:** 06 August 2021

### \*Correspondence:

Fatima Rauf,

E-mail: fatimarauf005@gmail.com

**Copyright:** © the author(s), publisher and licensee Medip Academy. This is an open-access article distributed under the terms of the Creative Commons Attribution Non-Commercial License, which permits unrestricted non-commercial use, distribution, and reproduction in any medium, provided the original work is properly cited.

## ABSTRACT

Cystic echinococcosis, also known as hydatid disease, rarely occurs in aorta. In this article, we report a rare case of pseudo-aneurysm of the lower descending thoracic aorta communicating with the hydatid cyst; surgical excision was performed with primary repair of aorta. This report emphasizes the need for early diagnosis of hydatid cyst with high index of suspicion in endemic areas, particularly if in the vicinity of a major vessel and aggressive investigations followed by subsequent early treatment before disabling and life-threatening complications occur.

**Keywords:** Hydatid cyst, Aorta, Surgery, Case report

## INTRODUCTION

Human cystic echinococcosis, also known as hydatid disease, is a zoonotic disease endemic in many sheep-raising regions of the world. The cysts of the parasite, *Echinococcus granulosus*, usually develop in the livers and lungs of the normal intermediate hosts (most commonly sheep and goats).

Humans may become infected accidentally, by ingesting eggs of the cestode excreted by the final hosts (usually dogs and foxes).<sup>1,2</sup> Hydatid cysts mostly affect the liver and lung. Nevertheless, some larvae may pass these filtering organs and reach the systemic circulation localizing any organ including the brain, heart, and bone. Developed hydatid cysts are rarely found in the aortic wall, mostly involving the thoracic or abdominal aorta. First case of hydatid cyst involving abdominal aorta was reported in 1985 by Pardal et al.<sup>3</sup>

Only a few isolated clinical cases have been reported since then and there are no statistical data regarding aortic involvement so far. The clinical presentation of hydatid

cyst in vascular tree is variable, ranging from rupture of hydatid cyst presenting as acute arterial embolization to mild symptomatic pain regionally as in our patient.

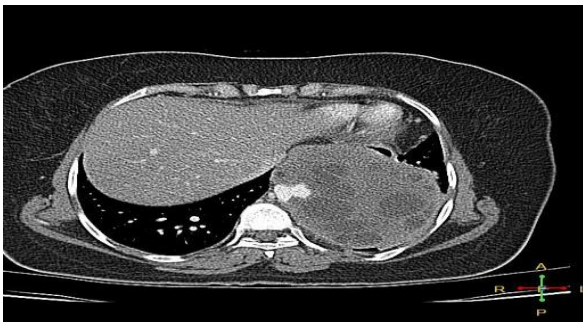Diagnosis was based on serological and radiological investigations and treatment is primarily surgical as described in previous case reports. We presented a case of hydatid pseudo-aneurysm of thoracic aorta, its diagnostic workup, surgical management and per-operative findings and post-operative course.

## CASE REPORT

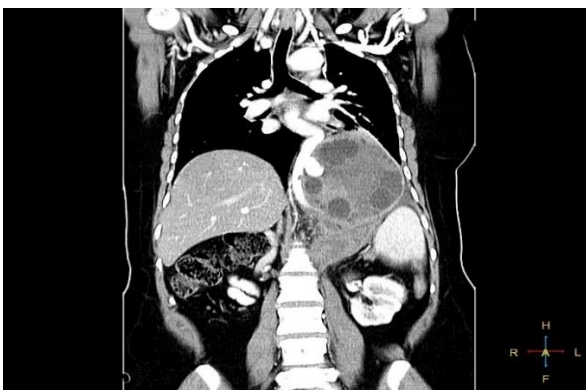
We present a case of a 32 years old female who presented to the accident and emergency department with complaints of left hypochondrium pain for 2 weeks. It was mild in intensity, intermittent in nature with occasional radiation to lumbar region and back. There were no other associated symptoms. Clinical examination was unremarkable for any palpable mass. Her blood complete picture, liver function tests, renal function tests and serum electrolytes were normal. Abdominal ultrasound showed a complex echogenic mass with peripheral cystic areas and central hyper-echoic area in the perisplenic area measuring

12.3×9.7 cm. A provisional diagnosis of hydatid disease was made and ELISA for anti-echinococcus igg antibodies was done. Anti-echinococcus igg antibodies were found to be 38.4 U/ml (reference values are more than 11 U/ml).

Computed tomographic thoraco-abdominal scan was done which showed a large well defined multi-locular cystic lesion measuring 12.5×9.2×11 cm (CC×TR×AP) in the left sub-phrenic retro-crural region displacing the diaphragm antero-superiorly causing reduced left lung volume, displacing the stomach anteriorly and abutting the inferior surface of left lobe of liver. Descending thoracic aorta showed tortuous course due to mass effect of the cystic lesion partially encasing the descending aorta with a contrast filled blind ending out-pouching measuring 16×21 mm extending into mass lesion. Abdominal aorta also showed a kink just below the origin of aneurysmal sac causing focal narrowing (measuring 7 mm) at the level of T9 vertebra (Figure 1 and 2).

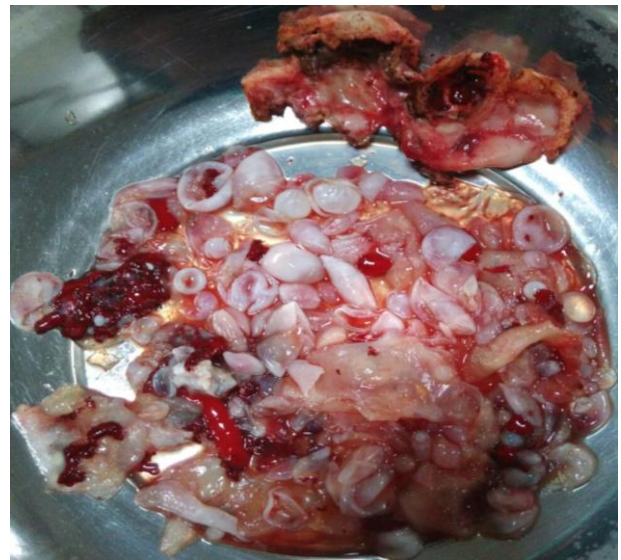

**Figure 1: CT scan (axial view) showing multi-locular cystic lesion in the left sub-phrenic retro-crural region displacing the diaphragm anterosuperiorly. Also, few intra-parenchymal atelectatic bands seen displacing stomach anteriorly and abutting the inferior surface of left lobe of the liver.**



**Figure 2: CT scan (coronal view) showing tortuous course of descending thoracic aorta due to mass effect of the cystic lesion partially encasing descending aorta with a contrast filled blind ending out pouching measuring 16×21 mm extending into mass lesion. Abdominal aorta also showed a kink just below the origin of aneurysmal sac causing focal narrowing at the level of T9 vertebra.**

A diagnosis of hydatid disease was made and oral albendazole, 200 mg BD was started for 14 days before the operative procedure was undertaken. Under general anesthesia, left thoracoabdominal incision was given. Per-operatively a huge saccular aneurysm (25×15 cm) was found to be arising from the descending thoracic aorta, 10 cm above the diaphragmatic opening. Diaphragm was divided circumferentially around the cyst, proximal and distal control of aorta was achieved, cystic wall of the hydatid pseudo-aneurysm was incised and hypertonic saline was first used as a solicialidal agent. Contents were evacuated meticulously to avoid any anaphylactic reaction and wall of the cyst was excised (Figure 3).



**Figure 3: Evacuated contents of the hydatid cyst (daughter cysts).**

Primary rent in the aorta was repaired. Contents of the cyst and the excised wall were sent for histopathology. Histopathology report later confirmed the diagnosis of hydatid disease. Patient was shifted to intensive care unit post-operatively. Bilateral lower limb pulses were confirmed by hand held Doppler ultrasound. Unfortunately, patient developed ventilator associated pneumonia which progressed to sepsis and end organ failure. Tracheostomy was done on 10th post-operative day. Despite treatment, patient could not be revived and died on 25<sup>th</sup> post-operative day.

## DISCUSSION

The arterial wall is an unusual site for hydatid cysts even in endemic countries. Only a few studies have reported this kind of location and are limited to case reports. The disease may be associated with life-threatening complications such as anaphylactic or hemorrhagic shock, systemic emboli, arterial insufficiency, and dissemination of the infection.<sup>4,5</sup> Many hypotheses have been proposed to explain arterial- especially aortic- localization. Some authors suggest hydatid cysts in adjacent tissues being the cause of erosion of arterial wall, and some believe that the

parasite localizes primarily in the aortic wall, in such cases with coexisting aneurysm or an endothelium defect in the vessel.<sup>6</sup> Others propose that the arrival of the parasite in the vessel is via the vasa vasorum.<sup>7</sup> There is as yet no definitive surgical treatment for arterial hydatidosis due to the rarity of this disease. Surgical treatment by excision with local repair with a Dacron patch and resection coupled with graft interposition has been successful in all reported cases.<sup>7,8</sup> The role of benzimidazoles before surgery is controversial. The proponent view is that preoperative use of benzimidazoles softens the cysts and reduces the intra-cystic pressure simplifying its removal and reducing the risk of secondary hydatidosis and recurrences. Benzimidazoles also significantly reduce the viability of the protoscolex. Recent evidences on the other hand advocates that the preoperative use of benzimidazoles should be avoided in larger lung cysts due to the risk of rupture. However, postoperatively, all patients should receive albendazole (10 mg/kg per day) for period of 6-8 weeks to prevent recurrence of the disease.<sup>9</sup>

## CONCLUSION

In conclusion, the aorta is an exceptional location for primitive hydatidosis. Although it is a benign parasitic disease, it can be responsible for serious complications such as arterial, systemic, or multivisceral dissemination. No standard surgical technique has been recommended regarding the management of patients with arterial hydatid cysts. Excision with primary repair and resection with graft interposition have been used as major surgical modalities in all reported cases.

*Funding: No funding sources*

*Conflict of interest: None declared*

*Ethical approval: Not required*

## REFERENCES

1. Brunetti E, Kern P, Vuitton DA. Expert consensus for the diagnosis and treatment of cystic and alveolar echinococcosis in humans. *Acta Tropica*. 2010;114(1):1-16.
2. Larrieu EJ, Frider B. Human cystic echinococcosis: contributions to the natural history of the disease. *Ann Trop Med Parasitol*. 2001;95(7):679-87.
3. Pardal HC, Orus MJM, Dominguez F, Ortega CLE, Ingelmo A, Alonso MMJ, et al. Hydatid mesoarteritis in the abdominal aorta: case report. *Angiology*. 1985;36(12):889-94.
4. Pulathan Z, Cay A, Güven Y, Sarihan H. Hydatid cyst of the abdominal aorta and common iliac arteries complicated by a false aneurysm: a case report. *J Pediatr Surg*. 2004;39(4):637-9.
5. Karapinar K, Ergül Z, Keskin A, Bugra O, Düzgün C, Zengin M. Hydatid cyst of the abdominal aorta and bilateral common iliac arteries. A case report. *J Cardiovasc Surg*. 1999;40(4):583-5.
6. Volpe P, Dalainas I, Ruggieri M, Nano G, Paroni G. Endovascular treatment of the descending thoracic aorta in a patient with a hydatid pseudoaneurysm. *J Vasc Surg*. 2006;44(5):1097-100.
7. Biglioli P, Spirito R, Roberto M, Parolari A, Agrifoglio M, Pompilio G, et al. False hydatid aneurysm of the thoracic aorta. *Ann Thorac Surg*. 1995;59(2):524-5.
8. Harris DG, Van VWM, Augustyn J, Rossouw GJ. Hydatid cyst fistula into the aorta presenting with massive hemoptysis. Case report and literature review. *J Cardiovasc Surg*. 2001;42(4):565-7.
9. Yilmaz M, Akbulut S, Kahraman A, Yilmaz S. Liver hydatid cyst rupture into the peritoneal cavity after abdominal trauma: case report and literature review. *Int Surg*. 2012;97(3):239-44.

**Cite this article as:** Mushtaq R, Rauf F, Hanif M, Ameer A. Hydatid disease with pseudo-aneurysm formation of the descending thoracic aorta: a case report. *Int Surg J* 2021;8:2780-2.