

## Case Report

# Case report of a giant inguinal hernia causing intestinal obstruction

R. Sanjay\*, Farukh Khan, Shalu Gupta, Prashant, Aakash

Department of General Surgery, Sawai Mansingh Medical College and Hospital, Jaipur, Rajasthan, India

**Received:** 16 June 2021

**Accepted:** 19 July 2021

**\*Correspondence:**

Dr. R. Sanjay,

E-mail: sanjay888r@gmail.com

**Copyright:** © the author(s), publisher and licensee Medip Academy. This is an open-access article distributed under the terms of the Creative Commons Attribution Non-Commercial License, which permits unrestricted non-commercial use, distribution, and reproduction in any medium, provided the original work is properly cited.

### ABSTRACT

Inguinal hernia is one of the ancient diseases that haunted the humanity from its very beginning to the modern times. Giant inguinal hernia is defined as an inguinal hernia that extends below the midpoint of inner thigh when the patient is in standing position. A 43 years old healthy male was affected by long standing, progressively enlarging right sided inguinal hernia for the past 21 years. His symptoms of abdominal discomfort and pain in lower abdomen after meal had worsened over time and he had lost 13 kg of weight in past 2 years. He had difficulty in micturition and gave history of constipation. Giant inguinal hernia is a type of hernia with massive contents inside the hernia sac and limited domain of abdominal cavity. The surgeon's decision regarding the prevention of intra-abdominal hypertension is a crucial stage of overall management. Giant inguinal hernia is a very rare. It is defined as hernia sac extending below mid inner thigh in the standing position. Surgical repair is very challenging and has significant morbidity and mortality due to increased intra-abdominal pressure and abdominal compartment syndrome.

**Keywords:** Giant inguinal hernia, Abdominal compartment syndrome, Treatment

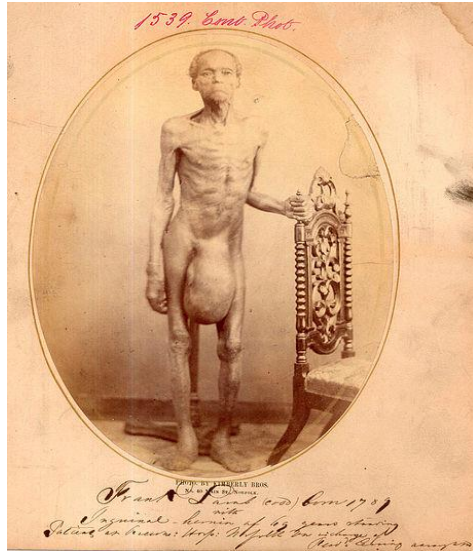
### INTRODUCTION

Inguinal hernia is one of the ancient diseases that haunted the humanity from its very beginning to the modern times (Figure 1). The currently used term 'hernia' comes directly from ancient Greek word 'kele/hernios' that means bud or off-shoot. Groin hernia repair has been referenced in medical writings as far back as 1500 BC in the Edwin Smith Surgical Papyrus (Figure 2).<sup>1</sup>

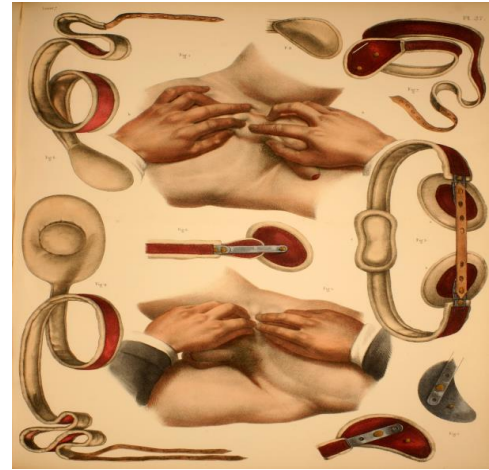
Although the natural course of the disease is relatively slow it eventually reaches the size that severely impairs the patient ability to perform daily activities. The mainstay of treatment remained the use of different types of inguinal belts that were supposed to maintain the hernia sac inside the body cavity. To successfully apply the hernia belt, hernia was first manually reduced and the belt custom made for patient was applied (Figure 3 and 4). Surgery is the only definitive treatment for this condition, and hundreds of repairs have been described in the literature. The most recent one is the concept of tension free repair which remains popular among surgeons today. It is interesting to note that numerous literatures have been

published on this disease in the small anatomical space despite its simplicity. Since the past decade most publications focused on laparoscopic surgery and different types of prosthetic mesh.


Giant inguinal hernia, however, is more unusual and significantly challenging in terms of surgical management. It is defined as an inguinal hernia that extends below the midpoint of inner thigh when the patient is in standing position.<sup>2</sup> No treatment has been adopted as standard procedure for this uncommon disease and several repair techniques are suggested by published articles and case reports. Further, the absence of large-scale comparative study is expected to continue due to relatively low number of cases. As a result, choosing a surgical procedure is made difficult and the decision must be made intra-operatively. This article is an examination of a very rare case of giant right inguinal hernia containing appendix, cecum, right side of colon, right ureter and greater omentum. This was corrected by right orchidectomy followed by Lichtenstein tension free mesh hernioplasty. Various surgical techniques reported in previous publications are discussed below as well.



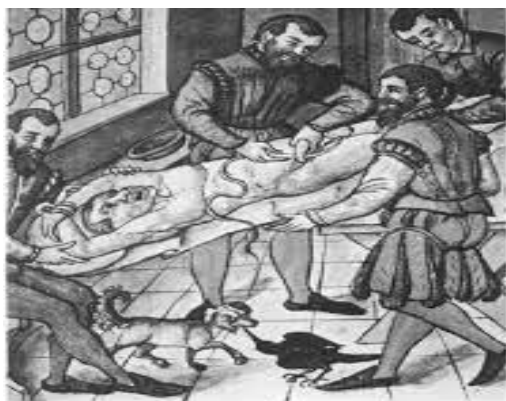**Figure 1: Hernia belts from ancient literature.**



**Figure 4: Hernia belts from ancient literature.**



**Figure 2: Edwin Smith surgical papyrus depiction of the first surgery for groin hernia.**



**Fig. 1. Contemporary presentation of an inguinal hernia operation, performed by Caspar Schenck (approximately 1530-1580), who was a German leather-surgeon. The base of the hernial sac is purse-string-ligated with a curved needle [3].**

**Figure 3: Manual reduction.**

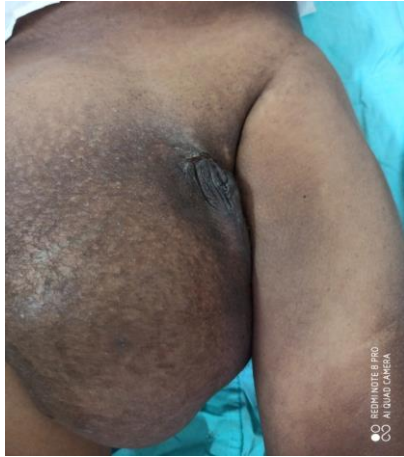**CASE REPORT**

A 43 years old healthy male was affected by long standing, progressively enlarging right sided inguinal hernia for the past 21 years. His symptom of abdominal discomfort and pain in lower abdomen after meal has worsened over time and he had lost 13 kg of weight in past 2 years. He has difficulty in micturition and gave history of constipation. He complained of multiple episodes of vomiting. Physical examination revealed pallor, scaphoid abdomen and a large irreducible right sided inguinal hernia extending to the level of lower thigh with tenderness on palpation (Figure 5). His X-ray of abdomen in erect position showed dilated bowel loops and his ct scan of abdomen showed a large hernial defect through which omentum and bowel was protruding out. An attempt at reduction with help of pressure bandage was tried (Figure 6). This right inguinal hernia measured around 55 cm vertically and 35 cm horizontally. It was crossing the mid of inner thigh on right side and hence comes under the classification of giant inguinal hernia.

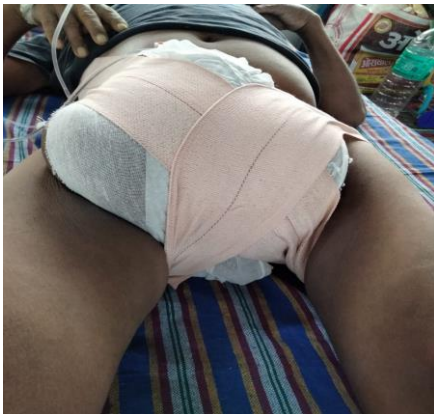General anesthesia was used for the surgery. A L-shaped incision in the right inguinal region reaching upto the scrotum was used. Hernia sac was identified and separated from the spermatic cord on the right side. After the hernial sac was opened, cecum, appendix, ascending colon, greater omentum, terminal ileum and right ureter were found inside the sac (Figure 7). When traction on spermatic cord was given the right testis also ascended into the sac. Right orchidectomy was performed. Manual reduction at this point was attempted, but it failed due to massive size of the contents. Here, lateral extension of internal ring was done and then manual reduction was attempted again. But this time the content of the hernia sac was reduced successfully. Internal ring was repaired with interrupted Prolene 2-0 suture. Lichtenstein’s tension free mesh hernioplasty was done with polypropylene mesh (Figure 8). Hemostasis was attained. As the raw surface was large a vacuum suction drain no.14 size was placed to prevent seroma formation and mesh infection (Figure 9). Patient was extubated and he had an uneventful post-



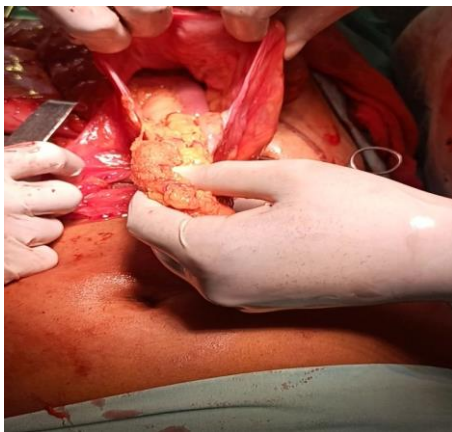operative recovery. Patient was advised laxatives from third post-operative day. He was allowed to take semisolid diet from fourth day. The vacuum drain had minimum serous content and hence was removed on the eighth post-operative day and patient was discharged the next day. Patient was able to eat and gradual weight gain was witnessed in routine follow ups.



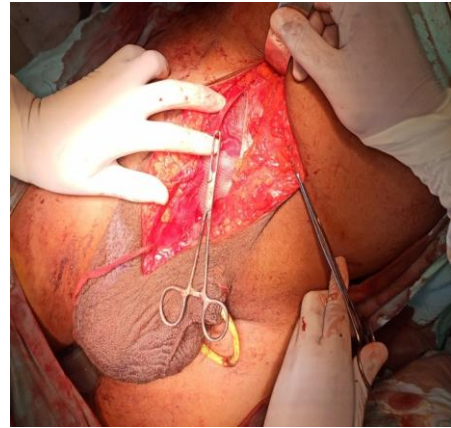**Figure 5: Giant inguinal hernia.**



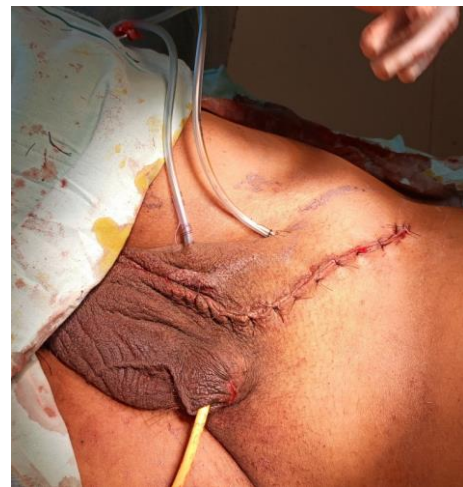**Figure 6: A preoperative attempt at manual reduction was made but failed as the hernia was too large.**



**Figure 7: Contents of the hernia sac.**



**Figure 8: Lichtenstein tension free mesh hernioplasty.**



**Figure 9: Vacuum suction drain was kept.**

## DISCUSSION

### *Key factors in the management of giant inguinal hernia*

Pre-operative colonic evaluation should be considered although the correlation between colon cancer and inguinal hernia is not clearly identified. Statistics indicates that colon cancer is detected by preoperative barium enema in 1.8-2.5% of patients who are older than 40 years and have undergone inguinal hernia repair.<sup>3-5</sup> Moreover, as colonic resection may be required as a part of treatment of giant inguinal hernia, it is recommended that the patient is given a preoperative colonic evaluation.

Barium enema is more preferred than colonoscopy for the reason that colonoscopy in the colon within hernial sac, is associated with high risk of colonic perforation.<sup>6</sup> But, in this case as patient presented with acute obstruction barium enema could not be done and the patient was evaluated on the basis of CT scan with contrast enhancement alone. Bowel preparation should be considered in all cases, especially the ones where hernial sac extends beyond the imaginary line between superior borders of patellar bone. Colonic resection may be

necessary as a part of the treatment. Enema was given to the patient preoperatively in this case.

Attempts must be made to prevent excessive intra-abdominal and intrathoracic pressure caused by reduction of massive contents into limited domain of abdominal cavity.

Spermatic cord can be easily stretched as a result of long-standing of hernia. In some cases, the spermatic cord is twisted, causing testicular atrophy. Therefore, preoperative testicular examination should be performed in all patients and orchidectomy may be needed to prevent undesirable events. Right orchidectomy was done in this case as the size of sac was large and the contents were irreducible. Scrotal hematoma is commonly found after the surgery. Dense adhesion is usually detected due to the chronicity of the disease.

Extensive lysis of adhesion can cause hematoma. Given these circumstances, a closed drainage system should be implemented. It is important to note, though, that such system cannot always prevent postoperative hematoma. Meticulous hemostasis and close observation are the most important steps towards prevention and early detection. Closed suction drain was kept in the raw area in this case and it was removed on the eighth post-operative day. An informed consent is needed to cover all possible operative procedures because final decision will be made intraoperatively. All of these options must be explained to the patient as well as their family members. Well informed consent regarding the need for orchidectomy and remote possibility for stoma formation (colostomy/ileostomy) was taken pre-operatively.

### ***Intra-abdominal hypertension and abdominal compartment syndrome***

Intra-abdominal hypertension can develop because of the disproportion of abdominal domain and the large amount of content in the hernial sac. The high rate of mortality is clearly observed following forced reduction of giant inguinal hernia.<sup>7</sup> Intra-abdominal hypertension can immediately develop after reduction of contents or later in the postoperative period due to ileus of the bowel. To prevent this in this case continuous Ryles tube suctioning was done and the patient was put on laxatives from the third post-operative day.

Excessive increase of intra-abdominal pressure generally affects regional blood flow in abdominal cavity, other organs outside abdomen, as well as the cardiovascular and respiratory systems. Intrathoracic pressure is raised as a result of cephalic displacement of diaphragm through the increase of intra-abdominal pressure.<sup>8</sup> Venous return, cardiac output and blood pressure are decreased by this phenomenon. Moreover, increase of intrathoracic pressure causes increase of inspiratory rate and mean airway pressure, while tidal volume and pulmonary compliance are reduced.<sup>8</sup> Therefore, vital signs and urine output should

be closely monitored. Respiratory support may be needed until ileus starts to resolve.<sup>9</sup>

### ***Surgical aspects***

#### *Resection of contents*

Giant inguinal hernia is a type of hernia with massive contents inside the hernia sac and limited domain of abdominal cavity. The surgeon's decision regarding the prevention of intra-abdominal hypertension is a crucial stage of overall management. Forced reduction is feasible in cases with mild form of this disease (type I) Resection or debulking of the contents is an option to prevent intra-abdominal hypertension, with resected organs usually being the colon, the small bowel, or the omentum. The benefit is that it is a single-stage operation. The limitations are rate of the failure of anastomosis, the changing of bowel function and the infection of prosthesis from resection of the bowel.

#### *Intra-abdominal volume increase procedure*

Loss of domain in the abdominal cavity is one of the main problems in the management of giant inguinal hernia. Forced reduction and simple hernioplasty may not be appropriate procedure for moderate and severely enlarged giant inguinal hernia [type II and III (Figure 10)] Several techniques were proposed to avoid bowel resection, including preoperative progressive pneumoperitoneum and lengthening of the abdominal wall by mesh or rotation of viable tissue.

#### *Pre-operative progressive pneumoperitoneum*

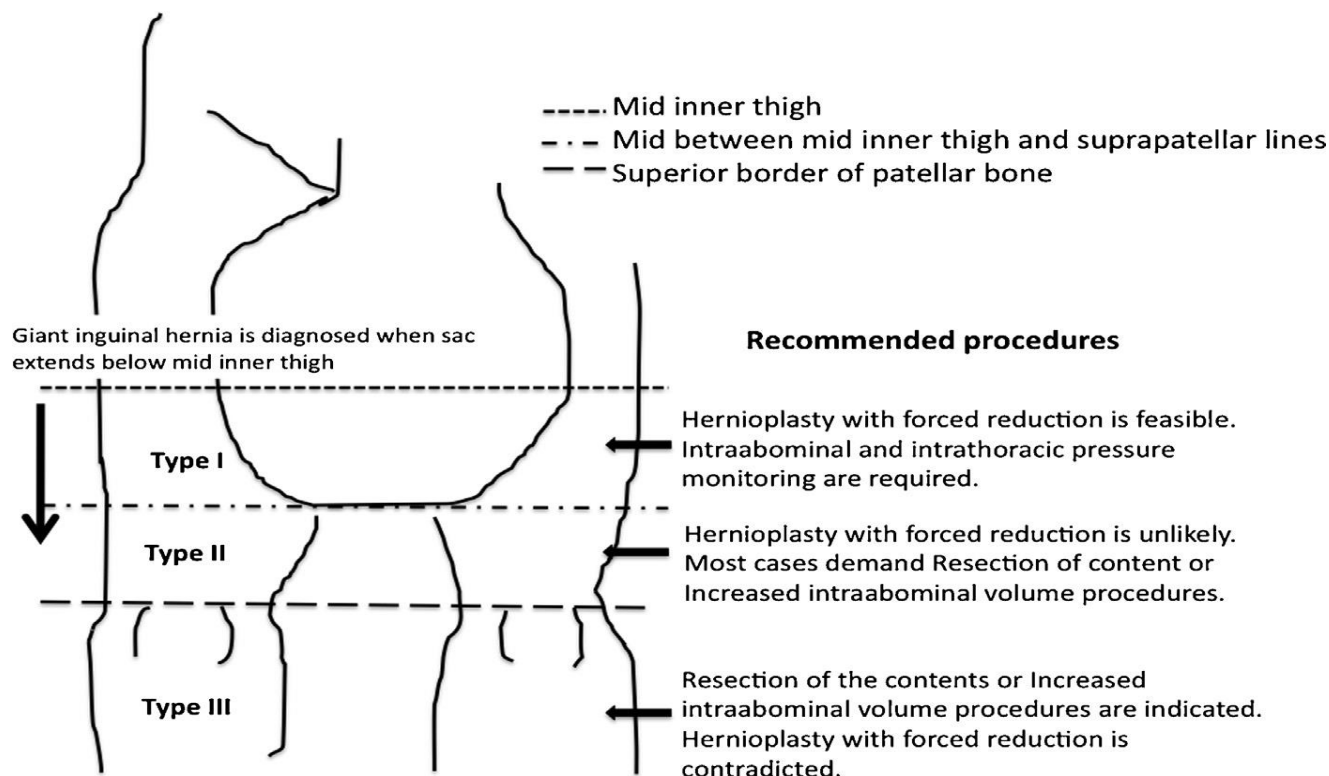
Moreno first reported the application of preoperative progressive pneumoperitoneum to ventral hernias and this technique was subsequently applied to giant inguinal hernia repair.<sup>12,13</sup> The concept is to preoperatively ensure adequate room in abdominal cavity by pneumoperitoneum before reduction of the hernial contents. This technique involves gradually insufflating the gas into abdominal cavity via placed catheter in situ, usually in increments from 500 cc to 2000 cc per day over 7–14 days.<sup>7,14</sup> From previous literatures, gas choices include natural ambient air, oxygen, carbon-dioxide and nitrous oxide.<sup>7,15</sup> The contraindications are abdominal infection, decompensated cardiac conditions, small neck of the hernia and strangulation.<sup>7</sup> The limitations of this technique are prolonged preoperative hospitalization, spread of air into hernial sac and technical unsuccessful.

#### *Rotation of viable tissue*

Rotation of viable tissue is the other technique to increase intra-abdominal volume by increasing surface of the abdominal wall. Several techniques have been proposed in the literatures. For scrotal skin flap, midline anterior abdominal defect was created to increase space of abdominal cavity.<sup>11,16</sup> Inguinal hernia orifice and midline

anterior abdominal wall defect was repaired by prosthetic mesh, then cover the midline mesh with myocutaneous scrotal flap. A modification was proposed by using hernia sac as peritoneal flap and cover with mesh on top at anterior midline defect.<sup>17</sup> Similarly, tensor fascia latae musculocutaneous flap was alternatively used to cover

mesh at anterior abdominal wall defect.<sup>9</sup> Component separation technique is one used to advanced rectus muscle by freeing external oblique from internal oblique muscle.<sup>10</sup> The advantage of rotation of viable tissue is that it is a single-stage procedure but surgical expertise is required to prevent complications.



**Figure 10: Classification of giant inguinal hernia.**

## CONCLUSION

Giant inguinal hernia is very rare. It is defined as hernia sac extending below mid inner thigh in the standing position. Surgical repair is very challenging and has significant morbidity and mortality due to increased intra-abdominal pressure and abdominal compartment syndrome. Giant inguinal hernias are categorized into 3 types depending on location and choice of surgery. Surgical techniques, in addition, to forced reduction with simple hernioplasty, are resection of contents and intra-abdominal volume increase procedure with repair of hernia. Here in this scenario as patient presented with acute obstruction simple Lichtenstein tension free mesh hernioplasty with lateral extension of deep inguinal ring and reduction of contents and right orchidectomy was done. This could have put the patient in serious jeopardy as he could have developed intra-abdominal hypertension and abdominal compartment syndrome. But the situation demanded for immediate surgery as he presented with acute obstruction. The decision of when to operate and which surgical technique to ply are taken after weighing out the benefit risk ratio alone which only the operating surgeon can understand better.

*Funding: No funding sources*

*Conflict of interest: None declared*

*Ethical approval: Not required*

## REFERENCES

1. Komorowski AL, History of the inguinal hernia repair. *World J Surg.* 2014.
2. Hodgkinson DJ, McIlrath DC. Scrotal reconstruction for giant inguinal hernias. *Surg Clin North Am.* 1984;64(2):307-13.
3. Terezis LN, Davis WC, Jackson FC. Carcinoma of the colon associated with inguinal hernia. *N Engl J Med.* 1963;268:774-6.
4. Maxwell JW, Davis WC, Jackson FC. Colon carcinoma and inguinal hernia. *Surg Clin North Am.* 1965;45(5):1165-71.
5. Day T, Ferrara JJ. Preoperative barium contrast enema in patients with inguinal hernia. *South Med J.* 1986;79(11):1339-41.
6. Leisser A, Delpre G, Kadish U. Colonoscope incarceration: an avoidable event. *Gastrointest Endosc.* 1990;36(6):637-8.

7. Barst HH. Pneumoperitoneum as an aid in the surgical treatment of giant herniae. *Br J Surg.* 1972;59(5):360-4.
8. Papavramidis TS, Marinis AD, Pliakos I, Kesisoglou I, Papavramidou N. Abdominal compartment syndrome- Intra-abdominal hypertension: Defining, diagnosing, and managing. *J Emerg Trauma Shock.* 2011;4(2):279-91.
9. Mehendal FV, Taams KO, Kingsnorth AN. Repair of a giant inguinoscrotal hernia. *Br J Plast Surg.* 2000;53(6):525-9.
10. Valliattu AJ, Kingsnorth AN. Single-stage repair of giant inguinoscrotal hernias using the abdominal wall component separation technique. *Hernia.* 2008;12(3):329-30.
11. Ek EW, Ek ET, Bingham R, Wilson J, Mooney B, Banting SW, Burt J. Component separation in the repair of a giant inguinoscrotal hernia. *ANZ J Surg.* 2006;76(10):950-2.
12. Moreno IG. Chronic eventrations and large hernias; preoperative treatment by progressive pneumoperitoneum; original procedure. *Surgery.* 1947;22(6):945-53.
13. Connolly DP, Perri FR. Giant hernias managed by pneumoperitoneum. *JAMA.* 1969;209(1):71-4.
14. Mayagoitia JC, Suarez D, Arenas JC, Díaz de León V. Preoperative progressive pneumoperitoneum in patients with abdominal-wall hernias. *Hernia.* 2006;10(3):213-7.
15. Piskin T, Aydin C, Barut B, Dirican A, Kayaalp C. Preoperative progressive pneumoperitoneum for giant inguinal hernias. *Ann Saudi Med.* 2010;30(4):317-20.
16. Merrett ND, Waterworth MW, Green MF. Repair of giant inguinoscrotal inguinal hernia using marlex mesh and scrotal skin flaps. *Aust N Z J Surg.* 1994;64(5):380-3.
17. Dessouki NI. Preperitoneal mesh hernioplasty in giant inguinoscrotal hernias: a new technique with dual benefit in repair and abdominal rooming. *Hernia.* 2001;5(4):177-81.

**Cite this article as:** Sanjay R, Khan F, Gupta S, Prashant, Aakash. Case report of a giant inguinal hernia causing intestinal obstruction. *Int Surg J* 2021;8:2463-8.