

Case Report

A rare case of caudate lobe liver abscess

Neetha V.^{1*}, Rajesh B. M.², Varsha S.¹

¹Department of General Surgery, ²Department of Surgical Gastroenterology, Rajarajeswari Medical College, Bangalore, Karnataka, India

Received: 18 June 2021

Revised: 23 July 2021

Accepted: 29 July 2021

***Correspondence:**

Dr. Neetha V.,

E-mail: neethavinayak27@gmail.com

Copyright: © the author(s), publisher and licensee Medip Academy. This is an open-access article distributed under the terms of the Creative Commons Attribution Non-Commercial License, which permits unrestricted non-commercial use, distribution, and reproduction in any medium, provided the original work is properly cited.

ABSTRACT

Indian subcontinent has high incidence of both amoebic and pyogenic liver abscess. Currently most of the liver abscesses are managed with interventional radiology based percutaneous drainage (either ultrasound or CT guided). Caudate lobe liver abscess is both a rare and at a peculiar location for such intervention as well as carries a high risk of rupture posing a great challenge for the surgeon in planning the appropriate management. In view of vicinity to vascular structures and viscera near liver hilum and difficult approach by laparoscopic technique, open surgical drainage seems to be a feasible option.

Keywords: Pyogenic abscess, Caudate lobe

INTRODUCTION

Liver abscess is either due to amoebiasis (extraintestinal manifestation) or pyogenic in origin.¹ Indian subcontinent has high incidence of both pyogenic and amoebic liver abscess.² Many factors have been implicated for the same like prevalence of poor hygiene, low socioeconomic factors, diabetes mellitus and immunocompromised state. A Diabetic can have 3.6-fold greater risk for developing pyogenic liver abscess compared to general population.³ This abscess can be in any location of the liver, either in right lobe, left lobe, caudate lobe or multilobar.⁴ Advances in imaging have allowed early diagnosis and management. Currently most of these are managed with the help of interventional radiology based percutaneous drainage (either ultrasound or CT guided). Many studies have discussed factors affecting the failure of percutaneous aspiration of liver abscess like multiple abscesses with multiple loculations, large abscess (>5 cm) containing thick pus with necrotic tissue, issues directly linked to the drainage catheter (blockage, slippage).⁵ Surgical treatment is commonly offered after failure of percutaneous drainage which causes economic burden and increases morbidity to patient by delaying

therapy. There can be several factors for failed percutaneous approach as mentioned above, location of abscess being one such important factor.⁶ Caudate lobe is both a rare and peculiar location in view of vicinity to vascular structure and difficult percutaneous and laparoscopic approach.

CASE REPORT

A 78 years old female patient presented to us with the complaints of intermittent mild non-radiating upper abdominal pain associated with nausea and decreased appetite for past 3 months. There were also few episodes of low-grade fever subsided with self-medication. She is a known case of type 2 DM since 10 years on oral hypoglycaemics.

There were no positive findings on general physical examination.

Abdominal examination revealed tenderness in the right hypochondriac region and epigastrium, liver span was normal and there was no palpable mass.

Blood investigations were within normal limits except for neutrophilic leucocytosis.

USG abdomen revealed a well-defined hetero-echoic lesion measuring about 5.4x6 cm in the right lobe of the liver involving segment 7 and 8 with no evidence of internal vascularity. Multiple GB calculi noted largest measuring 6.2 mm.

To further characterise the liver lesion, a CT abdomen was done which showed a well-defined peripherally enhancing hypodense lesion in the caudate lobe of liver measuring 5.9x6.3x5.5 cm in size with an appropriate volume of 110 cc very highly suspicious of hepatic abscess and a rare possibility of hydatid cyst. The lesion was found to be compressing intrahepatic IVC and causing indentation of portal vein bifurcation.

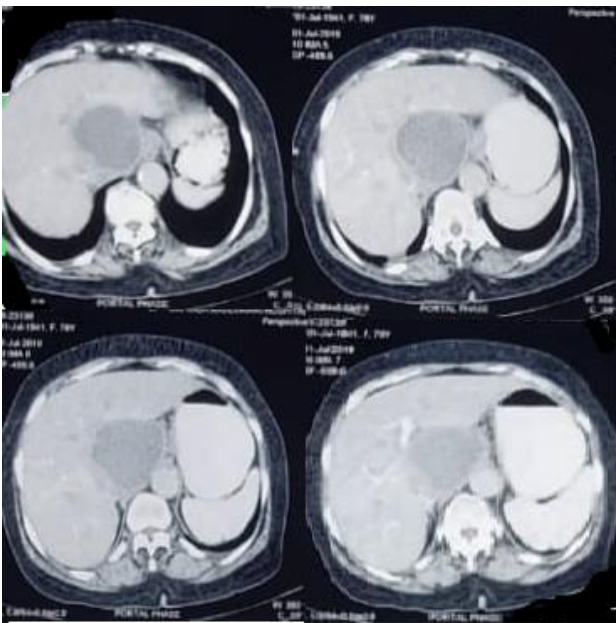


Figure 1: CT abdomen of well peripherally enhancing hypodense lesion, noted in segment 1 of liver (caudate lobe).

IgG ELISA for hydatid was found to be negative. After all work up and anaesthesia fitness patient was posted for surgery.

Surgery

Under GA, right subcostal incision made, lesser sac entered, and the lesion was confirmed to be in the caudate lobe. the lesion was around 6x8 cm size and the content were found to be pus on careful needle aspiration. A small incision was made and about 150 ML of purulent material was drained. Abscess cavity was thoroughly irrigated and, an 18 F drain was placed in the abscess cavity. Abscess wall was sent for biopsy. Rest of the liver was found to be normal. Cholecystectomy was done in the same setting. Post-operative period was uneventful

and patient was put-on broad-spectrum iv antibiotics for 5 days.

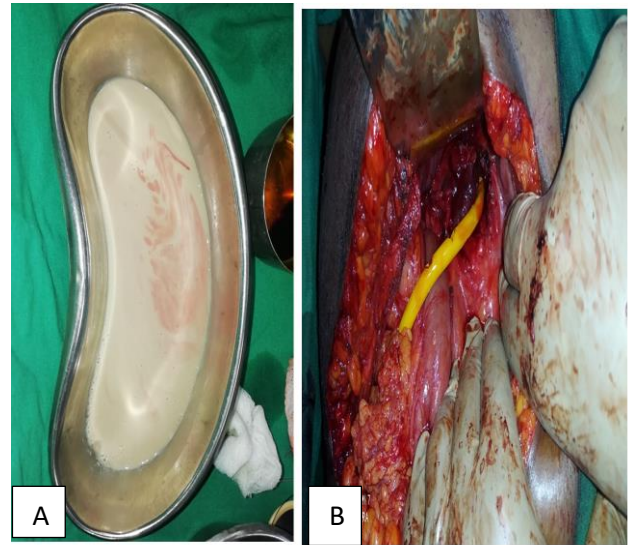


Figure 2 (A and B): Intra operative finding after drainage of pus with drain placement.

Histopathology section showed fragments of fibro collagenous and fibroadipose tissue with granulation tissue and haemorrhage. No liver tissue, parasite, bacteria or granuloma seen with features consistent with pyogenic abscess.

Pus culture revealed no growth.

DISCUSSION

Pyogenic liver abscess carries high incidence of morbidity and mortality up to (19%).⁷

The incidence is high in immunocompromised patients. Diabetics are more prone to develop pyogenic liver abscess which is 3.6 times higher when compared to the general population.⁷

As our patient was diabetic, the risk of pyogenic liver abscess was increased.

Large scale studies have found the three common etiologies for pyogenic liver abscess to be cryptogenic, biliary, or hematogenous origin.⁸

The most common site for this abscess is the right lobe (postero-superior segment) in view of anatomical and vascular pre-dilection, but they can occur in left lobe 20% of times, or in both or in caudate lobe.

Caudate lobe with its own independent arterial supply and venous drainage is only rarely affected. In our case it was in caudate lobe which is a rare and peculiar location. It is situated posteriorly and is close to hilum, portal vein

and IVC, making such abscess prone to vascular and biliary complications.⁹

Ultrasonography can be useful as a screening tool but CECT is definitive for diagnosis and to rule out complications such as spontaneous rupture and involvement of vasculature. The sensitivity of USG is 80-95% and that of CT scan is found to be 95-100%.¹⁰

In recent years percutaneous drainage is the favoured approach for management but has a failure rate of 15-36% and has to be either repeated or supplemented with surgery.¹¹

An abscess of the caudate lobe may remain silent until it leaks into lesser sac, where it can present as painful epigastric swelling or rupture into the biliary tract, extension into vasculature or pseudoaneurysm formation asking for a cautious approach to any interventional therapy be it percutaneous/surgical.

In addition to the special location that puts a risk of failure for percutaneous drainage of caudate lobe liver abscess there are growing opinions now recommending surgical open drainage as a front line of treatment. This is based on the idea that delay or failure of adequate drainage would increase morbidity and mortality (published overall mortality rate of 6-14%).¹²

Recently a low mortality rate of 4.5% has also been reported by Tan et al who managed patients with pyogenic liver abscess >5 cm in size by open surgical drainage as first line of treatment.¹³ In our case too open surgical drainage was carried out with all due precautions and patient was discharged uneventfully.

CONCLUSION

Caudate lobe liver abscess is a rare entity which may not be picked in routine USG. Open surgical drainage can be considered in view of risk of rupture into the abdominal cavity and its proximity to the vessels. Also delay or failure of adequate drainage by percutaneous technique would increase morbidity and mortality.

Funding: No funding sources

Conflict of interest: None declared

Ethical approval: Not required

REFERENCES

1. Sarada AK, Mittal R, Basra BK, Mishra A, Talwar N. Three cases of amoebic liver abscess causing inferior vena cava obstruction, with a review of literature. *Korean J Hepatol.* 2011;17:71-5.
2. Sharma MP, Sarin SK. Amoebic liver abscess in a north Indian hospital-current trends. *Brit J clin prac.* 1987;41(6):789-93.
3. Alkofer B, Dutay C, Parienti JJ. Are pyogenic liver abscesses still a surgical concern? A western experience. *HPB Surg.* 2012;(2012):316013.
4. Sonsuz A, Basaranoglu M, Senturk H. Amoebic abscess of the caudate lobe with spontaneous rupture into the biliary tract. *J clin Gastroenterol.* 1998;26:355-6.
5. Chung YF. Pyogenic liver abscess predicting failure to improve outcome. *Neth J Med.* 2008;66:183-4.
6. Soyer P, Heddadi M, Sihassen C. Amoebic abscess of the caudate lobe. An uncommon topographic form. *J Radiol.* 1992;73(2):121-2.
7. Thomsen RW, Jepsen P, Sorensen HT. Diabetes mellitus and pyogenic liver abscess: risk and prognosis. *Clin infec dis.* 2007;44(99):1194-201.
8. Cheng HC, Chang WL, Chen WY, Kao AW, Chuang CH, Shev BS. Long term outcome of pyogenic liver abscess recurrence. *J Clin Gastroenterol.* 2008;42:1110-5.
9. Lal H, Thakral A, Sharma ML. Liver abscess with venous extension-rare complication of a common problem. *Turk J Gastroenterol.* 2014;25(1):223-8.
10. Halvorsen RA, Korobkin M, Foster WL, Silverman PM, Thompson WM. The variable CT appearance of hepatic abscesses. *AJR Am J Roentgenol.* 1984;142:941-6.
11. Dhir U, Ghuman SS, Singhri S. Caudate lobe liver abscess: Early surgical drainage. *J Liver Reb Disord.* 2018;4(11):49-51.
12. Yu SC, Ho SS, Lau WY, Yeung DT, Yuen EH, Lee PS, Metreweli C. Treatment of pyogenic liver abscess: Prospective randomized comparison of catheter drainage and needle aspiration. *Hepatology.* 2004;39:932-8.
13. Tan YM, Chung AY, Chow PK, Cheow PC, Wong WK, Ooi LL et al. An appraisal of surgical and percutaneous drainage of pyogenic liver abscess longer than 5 cm. *Ann Surg.* 2005;241:485-90.

Cite this article as: Neetha V, Rajesh BM, Varsha S. A rare case of caudate lobe liver abscess. *Int Surg J* 2021;8:2823-5.