

## Case Report

# Enterobius vermicularis infestation causing terminal ileal gangrene

T. Mohamed Rizwan<sup>1\*</sup>, Mithun Raju<sup>2</sup>, Rupesh George<sup>3</sup>

<sup>1</sup>Department of Surgery, <sup>2</sup>Department of Anesthesiology, <sup>3</sup>Department of Cardiology, Amala Institute of Medical Sciences, Amala Nagar, Thrissur, Kerala, India

**Received:** 16 June 2021

**Accepted:** 16 July 2021

### \*Correspondence:

Dr. T. Mohamed Rizwan,

E-mail: [drizwanmohamed@gmail.com](mailto:drizwanmohamed@gmail.com)

**Copyright:** © the author(s), publisher and licensee Medip Academy. This is an open-access article distributed under the terms of the Creative Commons Attribution Non-Commercial License, which permits unrestricted non-commercial use, distribution, and reproduction in any medium, provided the original work is properly cited.

## ABSTRACT

*Enterobius vermicularis* is one of the most common nematode infestations seen worldwide. This condition is commonly seen in children. Although asymptomatic, they present with symptoms of perianal itching commonly at night with perianal excoriations. In this case report we present a case of a 79 year old man with multiple co-morbidities who presented with non-bilious vomiting and severe abdominal pain. Emergency laparotomy was performed during which terminal ileal gangrene was noted. Ileo-caecal wall revealed multiple parasites (*enterobius*).

**Keywords:** *Enterobius vermicularis*, *Enterobius*, Gangrene, Necrosis

## INTRODUCTION

*Enterobius vermicularis*, also called pinworm or threadworm, is one of the most common nematode infections in the world.<sup>1-3</sup> Humans are the only natural source of infection. Pinworm infestation is commonly seen in young children. Risk factors for infection include poor hygiene, eating after touching contaminated items and living with egg positive individuals. It most commonly infects children less than 18 years of age. Female predominance is seen between 5-14 years of age.<sup>4</sup> Infection occurs via self-inoculation by transferring eggs to the mouth with hands that have scratched the perianal area due to itching or through exposure to eggs in the environment (e.g. contaminated surfaces, clothes, bed linens, etc) or even during sexual contact.<sup>1,2</sup> Infections are generally asymptomatic. While the cure rate is high, recurrences are rather common.<sup>1</sup> Occasionally, tiny thread like worms may be visible to the naked eye in the perianal region.<sup>4</sup>

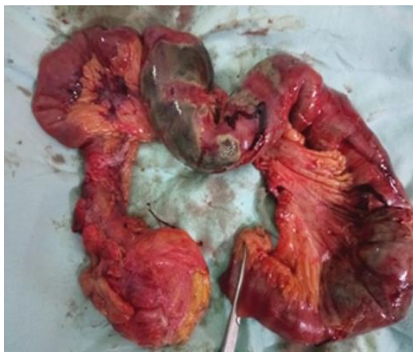*Enterobius* may be diagnosed though a cellophane tape test or a pinworm paddle test where an adhesive tape like material is applied to the perianal region and then visualized under the microscope. Examination may show characteristic ova about 30 microns in size with a flattened surface on one side or may reveal the worms itself. Such

an examination is done in the early morning to receive a higher yield. If the examination is negative for five consecutive mornings, then the diagnosis is ruled out. Examination of stool is not helpful as the worms are only occasionally excreted in the stool. We present a case of Terminal Ileal gangrene caused by *Enterobius vermicularis* infestation in a 79 year old man.

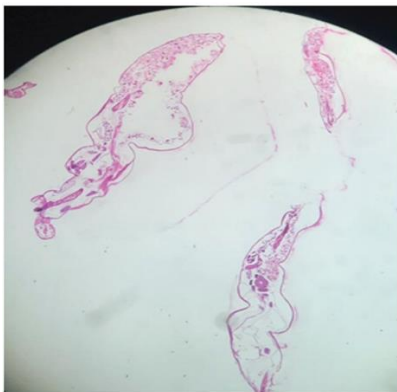## CASE REPORT

A 79-year-old male who is a known case of Atrial fibrillation (patient was on warfarin therapy), old cerebrovascular accident, chronic liver disease with portal hypertension, COPD, essential hypertension and benign prostatic hyperplasia was presented at the Emergency Department with complaints of non-bilious vomiting and severe abdominal pain for a duration of one day. There was no history of fever, altered bowel habits, dysuria, hematemesis, malaena, jaundice or hematochezia. On examining, abdomen was distended with severe tenderness over the right ileo-lumbar region along with severe abdominal guarding. There was no abdominal rigidity and bowel sounds were not heard on auscultation. USG of abdomen showed multiple dilated small bowel loops and the distal part of ileal bowel loops showed edematous wall with poor enhancement with mild free fluid in the

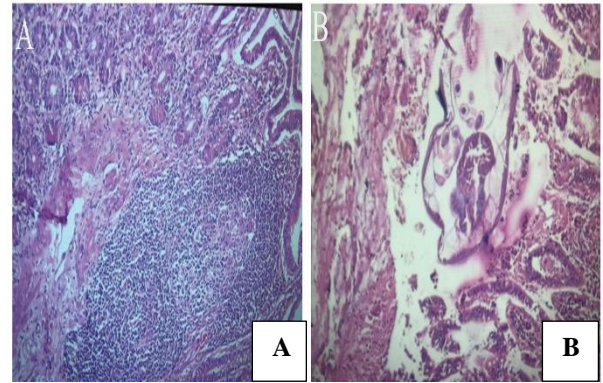
abdomen and pericardial space. After attaining high risk consent, he was taken up for emergency exploratory laparotomy under general anesthesia with concomitant perioperative optimization with four units of fresh frozen plasma, one-unit PRBC transfusions and vitamin K injections along with other supportive measures. Intraoperatively, terminal ileum was found to be gangrenous for a length of about 70 cm along with foul smelling seropurulent free fluid in the peritoneal cavity. The unhealthy segment was resected along with caecum, and ileo-transverse side-to-side anastomosis was done. The specimen was sent for histopathological examination. There was no evidence of bowel perforation. Liver was found to be fibrotic, firm and contracted. Rest of the bowel, bladder and other solid organs were found to be normal. Ileo-caecal wall revealed multiple parasites (enterobius). Abdomen was closed with a 32F drain in situ. Gross examination of the specimen revealed congested, thinned out and gangrenous bowel wall with no viable mucosa within the ileum (Figure 1). Cut section of the caecum and ileo-caecal junction showed multiple worms (Figure 2). Microscopy showed ileal wall with inflammatory infiltrate, ulcerated mucosa and coagulative necrosis involving up to the muscularis propria (Figure 3). Patient had an uneventful post-operative period. He passed stools on post-operative day 3 and started on normal diet on post-operative day 6. He was discharged on post-operative day 10. He was started on tablet albendazole 400 mg for three times at weekly intervals.



**Figure 1: Gross specimen showing congested, thinned out and gangrenous bowel wall.**



**Figure 2: Whole worms.**



**Figure 3: Photomicrographs of caecum and ileo-caecal junction (A) inflammatory infiltrate is predominantly lymphocytes along with plasma cells and few scattered eosinophils; and (B) parasite and intestinal wall with mucosal necrosis.**

## DISCUSSION

*Enterobius vermicularis* infections are generally asymptomatic. While the cure rate is high, recurrences are rather common.<sup>1-3</sup> *E. vermicularis* primarily lives in the ileum and cecum. Symptoms are rather unlikely when confined to the ileocecal area. The female adult worms and ova migrate at night time to the anal region and deposit thousands of eggs in the perianal area. This migration is the cause of pruritus. Eggs hatch near the anal area causing perianal pruritus. This leads to contamination of the fingers and results in ingestion of the eggs (autoinfection) and restarting of the life cycle of the worm. Occasionally, the larvae migrate back into the rectum and to the small intestine and begin the life cycle (retro infection). The most typical symptom is perianal pruritus, commonly at night, which may lead to excoriations along with bacterial superinfection.<sup>1-2</sup>

Occasionally, invasion of the female genital tract can occur causing vulvovaginitis. Pelvic or peritoneal granulomas have also been noted.<sup>2</sup> Other symptoms include, teeth grinding, enuresis, insomnia, anorexia, irritability and abdominal pain, which can mimic appendicitis. *E. vermicularis* larvae are often found within the appendix on appendectomy, but the role of this nematode in appendicitis remains controversial. Very rare instances of eosinophilic colitis associated with *E. vermicularis* larvae have been reported.<sup>3</sup> Treatment is usually done with the use of antihelminthic medications, most commonly a single dose of 400 mg of Albendazole taken on an empty stomach followed by a repeat dose two weeks later. Another alternative is administering a single dose of 100 mg of Mebendazole followed by a repeat dose two weeks later.<sup>1,4</sup>

In conclusion, *E. vermicularis* infestation can present itself in rather unexpected ways. Despite being common in children where it may present with perianal itching and occasionally with appendicitis, it too can present in the

elderly population with ileocolitis, enterocutaneous fistulas, urinary tract infections, mesenteric abscesses and as seen in this case, with ileal gangrene.

#### ACKNOWLEDGEMENTS

Authors gratefully acknowledge the help of Dr. Ajith T. A., Professor of Biochemistry, Amala Institute of Medical Sciences during the preparation of the case report.

*Funding: No funding sources*

*Conflict of interest: None declared*

*Ethical approval: Not required*

#### REFERENCES

1. Centres for Disease Control and Prevention. Parasites- Enterobiasis, 2001. Available at:

<http://www.cdc.gov/parasitespiepi.html>. Accessed on 09 June 2021.

2. Georgiev V. Chemotherapy of enterobiasis (oxyuriasis). Expert Opin Pharmacother. 2001;2(2):267-75.
3. Jong MD, Baan J, Lommerse E, Gool T. [Severe diarrhea and eosinophilic colitis attributed to pinworms (*Enterobius vermicularis*). Ned Tijdschr Geneesk. 2003;147(17):813-5.
4. Rawla P, Sharma S. *Enterobius Vermicularis*. Treasure Island, FL: StatPearls Publishing; 2021.

**Cite this article as:** Rizwan TM, Raju M, George R. *Enterobius vermicularis* infestation causing terminal ileal gangrene. Int Surg J 2021;8:2477-9.