

## Research Article

# Pyramidal lobe, an embryologic remnant in thyroidectomy under loupe magnification: a hospital based cross-sectional study in a tertiary care centre

Induprabha Yadev Prabhakaran\*, Gejoe George

Department of general surgery, Government medical college, Trivandrum, Kerala, India

**Received:** 12 August 2015

**Revised:** 24 August 2015

**Accepted:** 07 October 2015

### \*Correspondence:

Dr. Induprabha Yadev Prabhakaran,  
E-mail: [dryadev@gmail.com](mailto:dryadev@gmail.com)

**Copyright:** © the author(s), publisher and licensee Medip Academy. This is an open-access article distributed under the terms of the Creative Commons Attribution Non-Commercial License, which permits unrestricted non-commercial use, distribution, and reproduction in any medium, provided the original work is properly cited.

## ABSTRACT

**Background:** Pyramidal lobe, an embryological remnant is often encountered during thyroidectomy, and its removal is important to prevent the incidence of recurrence. In this context, we evaluated the use of magnifying surgical loupe in increasing the identification rate of pyramidal lobe and levator glandulae thyroideae.

**Methods:** This hospital-based cross-sectional study was conducted in the department of surgery, government medical college, Trivandrum from February 2015 to July 2015. Data were collected from randomly selected patients posted for total thyroidectomy. Demographic variables like age, sex and outcome variables like presence of pyramidal lobe and levator glandulae thyroideae together, its attachment to thyroid, pathology in the thyroid lobe and in the pyramidal lobes were assessed. This study was approved by the institutional ethics committee. Statistical analysis was done with R statistical programming software version 3.2.0.

**Results:** Number of patients included in the study was 45. The median age was 41 years (range 22-57). There were 9 (20%) males and 36 (80%) females. Pyramidal lobes were dissected out in 37(82%) of the patients. These were found attached to left lobe in 27 (71%) of the thyroidectomies. The mean length of pyramidal lobe and levator glandulae thyroideae was  $32.5 \pm 15.06$  mm. Pyramidal lobe was found normal on pathological examination in 76% of the specimens.

**Conclusions:** This study showed that pyramidal lobe and levator glandulae thyroideae can be dissected out in more than 80% of the patients if done under loupe magnification. The adoption of a surgical loupe in the routine operative workflow could potentially reduce thyroid recurrences.

**Keywords:** Loupe magnification, Pyramidal lobe, Thyroidectomy, Cross-sectional study, Embryological remnant

## INTRODUCTION

Pyramidal lobe of thyroid is an embryological remnant of thyroid lobes, attached to left lobe of thyroid or to the isthmus. These remnants arise as a result of variation in the regression of thyroglossal duct, resulting in levator glandulae thyroideae and pyramidal lobe.<sup>1,2</sup> Its prevalence is reported in literature as varying from 12% to 80%.<sup>3,4</sup> Removal of these embryological remnants is important to avoid residual thyroid left behind in thyroidectomy and to

reduce the chances of recurrence.<sup>5</sup> Hence total thyroidectomy, including removal of the embryological remnants is considered to be the operative procedure of choice at present.<sup>6</sup> Leaving behind these remnants results in recurrence.<sup>7</sup> In addition, removal of all thyroid tissue is important for the post-operative radioiodine scanning in patients with papillary or follicular carcinoma thyroid.<sup>3,8</sup>

Use of a magnification loupe was advised in thyroidectomy in the literature as a method to reduce

complication and to improve the outcome in thyroidectomy.<sup>9-11</sup> Thyroidectomy done under loupe magnification could result in increased chance of detection of pyramidal lobe and levator glandulae thyroideae. However, no previous study has investigated the use of a surgical loupe in identification and dissection of these embryological remnants like pyramidal lobes.

This study was undertaken to find out the prevalence and identification rate of pyramidal lobes in thyroidectomy done under loupe magnification.

## METHODS

This hospital based cross-sectional study was conducted in the department of surgery government medical college Trivandrum from February 2015 to May 2015. This study is a part of a large study on embryological remnants of thyroid encountered during thyroidectomy under loupe magnification. Sample size was calculated using standard statistical equation, and we recruited all eligible patients satisfying the inclusion and exclusion criteria randomly from the computerized admission registry. Informed consents were taken from all patients willing to take part in the study. The patients were aged between 13 to 90 years, admitted to the department of surgery with various indications for thyroidectomy. The exclusion criteria were recurrent thyroid disease, patients admitted for completion thyroidectomy, anaplastic carcinoma and those with tracheal infiltration in the preoperative ultrasound or clinical examination.

Thyroidectomy was done as per the technique described by Delbridge.<sup>7</sup> All the operative steps were performed in standardized steps with the aid of a surgical loupe of magnification 2.5 manufactured by Heine. All participants were operated under general anesthesia. Skin incision was made two-finger breadth above the sternal notch, preferably in a skin crease. Skin flaps were elevated in the subplatysmal plane with surgical diathermy in cutting mode at 30 w. Mid line was opened between the strap muscles. After mobilizing the lobes, the external laryngeal nerves are identified in the cricothyroid space, and superior thyroid vessels were individually ligated or clipped. Recurrent laryngeal nerves are encountered starting the dissection high on the surface of the thyroid and tackling the tertiary branches of the inferior thyroid artery with bipolar cautery. Parathyroid and its vascular supply were identified and saved. Parathyroid transplantation was done selectively. Zuckerkandl tubercles and thyrothymic rests were identified and removed along with thyroidectomy specimen. Wound was closed after attaining complete haemostasis with a drain.

The pyramidal lobes and its connecting tracts were dissected out completely, and length measured in mm using a stainless steel caliper. In addition, the lobe from which pyramidal lobe arose was documented. Data was collected in a well-structured case report form with the

help of residents duly trained for the data collection.

The outcome variables observed were the presence or absence of pyramidal lobe and levator glandulae thyroideae, its length, attachment to the thyroid and pathology in the pyramidal lobe and levator glandulae thyroideae. The main baseline variables were common demographic variables, preoperative diagnosis, fine-needle aspiration needle aspiration biopsy results and pathology in the thyroid as per the histopathological reports. The study was approved by the institutional ethics committee and was conducted conforming to the declaration of Helsinki.

Outcome data are summarized as proportion and percentage of pyramidal lobes identified. The length of pyramidal lobe and its connecting stalk together was summarized with mean and standard deviation in millimetre. Operative time is summarized in minutes in mean and standard deviation. Statistical analysis was done with R statistical programming software version 3.2.0. Age and sex difference in the relative proportion of the pyramidal lobe were assessed, and statistical significance were tested with  $p < 0.05$  taken as the level of significance. Mean, median, standard deviation and prevalence proportion were calculated. Association between the presence or absence of pyramidal lobe and its connection and between baseline and other covariates were studied with chi square or Fischer's exact test for categorical variables. Continuous data were compared with student t-test. Linear and logistical regression modelling was used for exploration of association between variables.

## RESULTS

**Table 1: Baseline characteristics of patients and presence of pyramidal lobes.**

Patient characteristics	Total (N=45)	Pyramidal lobe present Count (Percentage)	Pyramidal lobe absent Count (Percentage)
Age < 50	36	29(80.6)	7(19.4)
Age > 50	9	8(88.9)	1(13.4)
Sex			
Female	36	30(83.3)	6(16.7)
Male	9	7(77.8)	2(22.2)
Ultrasound			
Negative	42	34(81)	8(19)
positive	3	3(100)	0

There were 45 thyroidectomies included in the study. We conducted this study in 2005. The median age was 41 years (range 22-57). The total number of males were 9(20%) and females 36 (80%) (Figure 1). Pyramidal lobe and its fibrous attachment were identified in 37 (82%, CI 67 to 91) patients and absent in 8 (18%) patients. However preoperative ultra-sonogram was positive in only 3 (7%, CI 1.7-19) of patients and negative in 42 (93%) 95% CI 80.6-98.2 participants (Table 1). Per

operatively pyramidal lobe was found attached to the left lobe of thyroid in 27 (71%) thyroidectomies, to the isthmus in 8 (21%) and to the right lobe of thyroid gland in 3 (8%) of patients. Pyramidal lobes were found to be normal in 25 (76%) patients. Colloid goitre was reported in 5 (15%) specimens and thyroiditis in 3 (9.3%) of cases. The mean length of pyramidal lobe and levator glandulae thyroideae together was  $32.5 \pm 15.06$  mm. There were missing data for 8 cases and those were not included in the relevant analysis.

In patients with pyramidal lobes identified, pathology was normal in 76% of the patient, but thyroid showed pathology in 84% of patients (Table 2 and Table 3). Mean length of pyramidal lobes identified in patients aged less than 50 years was 29.97 (13.76) cm and in patients, more than 50 years was 42.3 (16.8) but was not statistically significant. There were 29 (85.3%) females in the below 50 category whereas there were 7 (63.6%) females in the above 50 age group. There was no significant association between age and pyramidal lobe. The odds' ratio was 0.99 (CI 0.91 to 1.08) (Figure 2).

**Table 2: Pathology in the pyramidal lobe.**

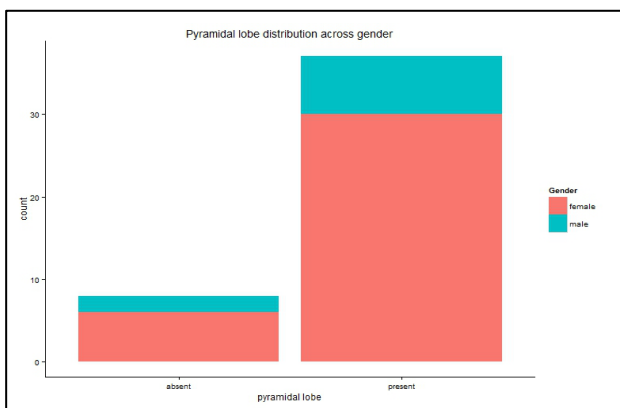
Pathology in the lobe	Pyramidal lobe Present in numbers	Percentage
Colloid goitre	5	15.2%
normal	25	75.8%
thyroiditis	3	0.09%

**Table 3: Pathology in the thyroid.**

Pathology in the thyroid	Pyramidal lobe present	Percentage
colloid	31	83.8%
follicular	2	5.4%
Papillary carcinoma	1	2.7%
thyroiditis	3	8.1%

**Table 4: Age wise comparison of variables.**

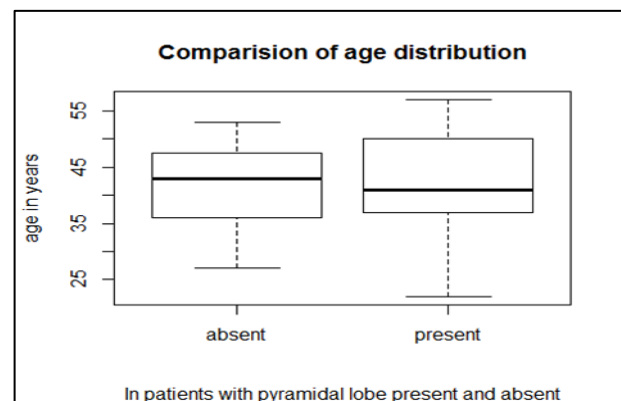
	Less than fifty years Mean(SD)/count(percentage)	More than fifty years Mean(SD)/count(percentage)
Length of pyramidal lobe in mm	29.69 ( 14.14)	40.6 (15.4)
Age in years	37.7 (7.06)	52.81(2.4)
Female	29 (85.3%)	7(63.6)
Male	5 (14.7)	4(36.4%)
Pyramidal lobe absent	7 (19.4)	1 ( 11.1)
Pyramidal lobe present	29 (80.6)	8 (88.9)



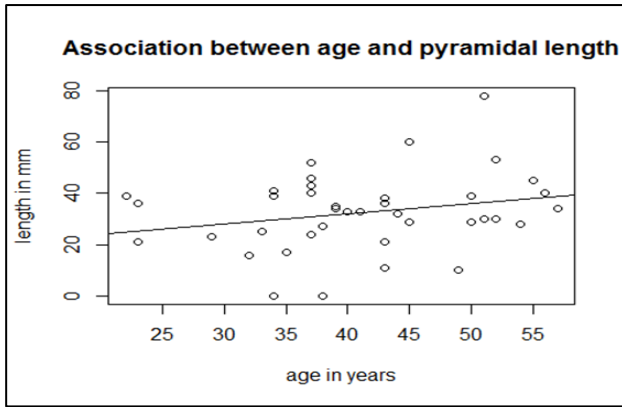
**Figure 1: Pyramid lobe distribution across gender.**

There was no correlation between length of pyramidal lobe and age (Figure 3). The correlation coefficient was only 0.24 (CI -0.07 to 0.51). Linear regression analysis showed that length of pyramidal lobes changes by 0.4 (CI -0.13 to 0.93) for every one-year increase in age and was statistically not significant. Statistical analysis of sex and length of pyramidal lobe and its connections showed that

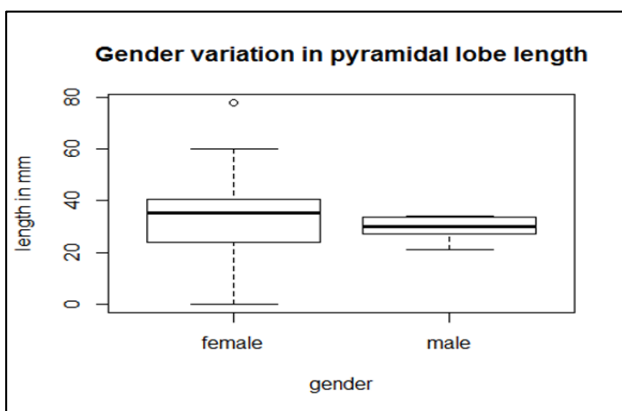
compared to females, lengths of pyramidal lobe in males are 3.7 (CI-16.5 to 9.1) mm shorter and was not statistically significant (Figure 4). There was no association between gender and presence or absence of pyramidal lobe. The odds ratio was 0.7 (CI 0.13 to 5.46).



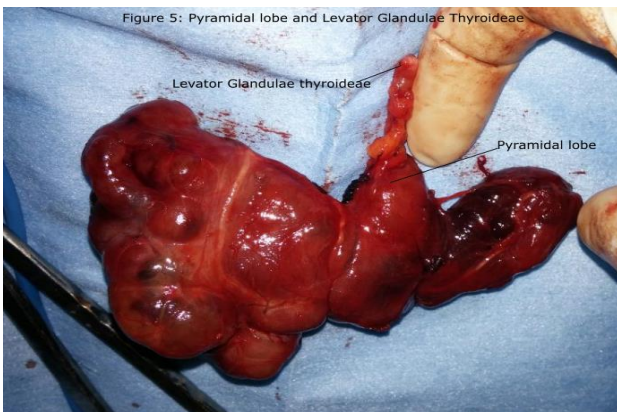
**Figure 2: Comparison of age distribution.**



**Figure 3: Association between age and pyramidal lobe length.**



**Figure 4: Gender variation in pyramidal lobe length.**



**Figure 5: Thyroidectomy specimen with pyramidal lobe.**

## DISCUSSION

This study showed that in more than 80% of the patients, we can dissect out pyramidal lobe and its fibrous connection with the help of surgical loupes. The occurrence of pyramidal lobe is more in females and 70% of the lobe, and fibrous tissue arises from the left side. The pyramidal lobe was found to be longer in female compared to male in our study, but statistically not

significant. In 76% of the patients histology report was normal in the pyramidal lobe whereas the histological report of the thyroidectomy showed colloid in 80% of the cases.

The prevalence of pyramidal lobes in our result compares with that of Foster et al. Other studies show varying results like Cicekcibasi et al 60-65%, Hunt et al 41%; Filho et al 50.7%; Sturniolo et al; 25.5% and Geraci et al 12%.<sup>3,4,12-14</sup> The increased detection rate in our study could be due to the peroperative use of magnifying loupe and following a standardized approach with specific attention to dissection of embryological remnants like pyramidal lobe. Another reason for the increased detection rate could be dissection and removal of pyramidal and its attaching fibrous stalk together. In our study, there was no statistically significant difference between the prevalence rates of pyramidal lobes between sexes. This contrasts with literature.<sup>15</sup> This could be due to a difference in geographical population. Another possible explanation could be relatively fewer numbers of men in our study.

The preponderance of pyramidal lobes attached to left side agrees with other studies.<sup>4,5,12,16,17</sup> However, in our study the proportion of pyramidal lobe arising from the left is more than those reported in other studies. One of the studies agreed with our study.<sup>3</sup> It could be due to a difference in the populations. There are variations in the length of the pyramidal lobe by sex in different parts of the world. As per the studies by suckeci blaci sutlana and harjeet et al pyramidal lobes is longer in males.<sup>18-20</sup> Our study is in consistent with the results of Alnajjar et al and Mu et al.<sup>21,22</sup> These differences could be due to geographical reasons or difference in the populations.<sup>20,21</sup> The preoperative detection rate of pyramidal lobes by ultrasound examination in our study was only 7% (CI 1.7 to 19) where as in literature it ranges from 50 to 60 percent.<sup>23,24</sup>

There are at least three limitations for this study. One of the limitations of the study was that it was designed as a hospital-based descriptive study. The second limitation of the study was the missing values of some of the variables so that it could have influenced the result. The third limitation of the study is that the number of patients in this study was relatively small. In future, we intend to conduct a comparative study of dissection of pyramidal lobes with and without the aid of magnification with surgical loupe.

The present study was undertaken to assess the prevalence and detection rate of pyramidal lobes. The findings from this study suggest that dissection of pyramidal lobes under loupe magnification will result in increased detection rate of pyramidal lobe during thyroidectomy. An implication of this study is that adoption of routine use of a surgical loupe by the surgeon could potentially reduce the chances of leaving behind the pyramidal lobe and future recurrence. Further studies



in the form of multicentric randomized studies are recommended.

## ACKNOWLEDGEMENTS

We are obliged to Dr. Ambareesh Dutta of Asian Institute of public health for his guidance in the analysis of data in R software. We extend our sincere gratitude to our colleague Dr. Meer chisthi and our residents Dr. Parimal and Dr. Sreeraj for helping us take photographs of the operative procedures. We would like to thank Dr. Krishna Kumar for his constant encouragement.

*Funding: No funding sources*

*Conflict of interest: None declared*

*Ethical approval: The study was approved by the institutional ethics committee*

## REFERENCES

1. Ranade AV, Rai R, Pai MM. Anatomical variations of the thyroid gland: possible surgical implications. Singapore Med J. 2008;49:831-4.
2. Gunapriya R, Varsha S, Senthil Kumar B. Levator Glandulae Thyroideae with the absence of Pyramidal Lobe—A case report. International Journal of Anatomical Sciences. 2010;1:45-7.
3. Geraci G, Pisello F, Li Volsi F. The importance of pyramidal lobe in thyroid surgery. G Chir. 2008;29:479-82.
4. Blumberg NA. Observations on the pyramidal lobe of the thyroid gland. S Afr Med J. 1981;59:949-50.
5. Braun EM, Windisch G, Wolf G. The pyramidal lobe: clinical anatomy and its importance in thyroid surgery. Surg Radiol Anat. 2007;29:21-7.
6. Delbridge L. Total thyroidectomy: the evolution of surgical technique. ANZ journal of surgery. 2003;73:761-8.
7. Delbridge L, Reeve TS, Khadra M. Total thyroidectomy: the technique of capsular dissection. Aust N Z J Surg. 1992;62:96-9.
8. Rosário PW, Maia FFR, Cardoso LD. Correlation between cervical uptake and results of postsurgical radioiodine ablation in patients with thyroid carcinoma. Clinical nuclear medicine. 2004;29:358-61.
9. Pata G, Casella C, Mittempergher F. Loupe Magnification Reduces Postoperative Hypocalcemia after Total Thyroidectomy. Am Surg. 2010;76(12):1345-50.
10. Saber A, Rifaat M, Ellabban GM. Total thyroidectomy by loupe magnification: a comparative study. Totale Schilddrüsenresektion mit Lupenvergrößerung: eine Vergleichsstudie. 2011;43:49.
11. Testini M, Nacchiero M, Piccinni G. Total thyroidectomy is improved by loupe magnification. Microsurgery. 2004;24:39-42.
12. Hunt PS, Poole M, Reeve TS. A reappraisal of the surgical anatomy of the thyroid and parathyroid glands. Br J Surg. 1968;55:63-6.
13. Cicekcibasi AE, Salbacak A, Seker M. Developmental variations and clinical importance of the fetal thyroid gland. A morphometric study. Saudi medical journal. 2007;28:524-8.
14. Sturniolo G, Bonanno L, Gagliano E. The thyroid pyramidal lobe: frequency, morphological features and related diseases. Chir Ital. 2008;60:41-6.
15. Zivic R, Radovanovic D, Vekic B. Surgical anatomy of the pyramidal lobe and its significance in thyroid surgery. S Afr J Surg. 2001;49:110.
16. Marshall C. Variations in the form of the thyroid gland in man. Journal of anatomy and physiology. 1985;29:234.
17. Harjeet A, Sahni D, Jit I. Shape, measurements and weight of the thyroid gland in northwest Indians. Surg Radiol Anat. 2004;26:91-5.
18. Milojevic B, Tosevski J, Milisavljevic M. Pyramidal lobe of the human thyroid gland: an anatomical study with clinical implications. Rom J Morphol Embryol. 2013;54:285-9.
19. Patrizi G, Rocco GD, Giannotti D. The Pyramidal Lobe of the Thyroid, file.scirp.org, 2014.
20. Sultana S, Mannan S, Ahmed M. An anatomical study on pyramidal lobe of thyroid gland in Bangladeshi people. Mymensingh Med J. 2008;17:8-13.
21. Alnajjar SM. Evaluation of the importance of pyramidal lobe of thyroid gland anatomically in the surgical fields in Erbil.
22. Mu Z, Fatima N, Zaman U. Pyramidal lobe on 99m technetium thyroid scan: Incidence, origin and association with thyroid function. Saudi Surgical Journal. 2013;1:37.
23. Kim KS, Kim DW, Sung JY. Detection of thyroid pyramidal lobe by ultrasound versus computed tomography: a single-center study. J Comput Assist Tomogr. 2014;38:464-8.
24. Ryu JH, Kim DW, Kang T. Pre-operative Detection of Thyroid Pyramidal Lobes by Ultrasound and Computed Tomography. Ultrasound in Medicine & Biology. 2014;40:1442-6.

**Cite this article as:** Prabhakaran IY, George G. Pyramidal lobe, an embryologic remnant in thyroidectomy under loupe magnification: a hospital based cross-sectional study in a tertiary care centre. Int Surg J 2015;2:590-4.