

Case Series

Diaphragmatic eventration plication repair with minimal access techniques: a case series

Aditya C. Oak*, Vishakha R. Kalikar, Ankur K. Patel, Roy V. Patankar

Digestive Disease Centre, Zen Hospital, Mumbai, Maharashtra, India

Received: 08 June 2021

Revised: 07 July 2021

Accepted: 31 July 2021

*Correspondence:

Dr. Aditya C. Oak,

E-mail: dradityaoak@yahoo.com

Copyright: © the author(s), publisher and licensee Medip Academy. This is an open-access article distributed under the terms of the Creative Commons Attribution Non-Commercial License, which permits unrestricted non-commercial use, distribution, and reproduction in any medium, provided the original work is properly cited.

ABSTRACT

Diaphragmatic eventration is a rare pathological condition occurring in <0.05% individuals causing the diaphragm to permanently ascend into the chest due to partial or complete replacement of diaphragmatic musculature by fibroblastic tissue. Congenital diaphragmatic eventration rarely presents among adults with most patients remaining asymptomatic only to be diagnosed incidentally after chest radiography. Symptomatic patients can present with dyspnoea, orthopnoea, recurrent lower respiratory tract infections or gastrointestinal symptoms. Management varies according to symptoms with asymptomatic cases requiring no intervention and plication being the standard, well-described technique for symptomatic cases. Here we described two cases with eventration approached using different minimal access techniques.

Keywords: Diaphragm, Eventration, Plication, Laparoscopy, Thoracoscopy, Minimal access surgery

INTRODUCTION

Eventration of diaphragm is a rare pathological condition in which the diaphragmatic musculature is partially or completely replaced by fibroblastic tissue. This causes the diaphragm to permanently ascend up into the chest. This results in weakness in the diaphragm and inability to participate in active respiration. The normal attachments of the diaphragm to the sternum, the ribs and the dorsolumbar spine are generally maintained.

Eventration of diaphragm has an incidence of <0.05% with the commonest occurrence being in males. Eventration of diaphragm can either be unilateral or bilateral, but incidence of the left hemi diaphragm being involved is high.¹ Incidence is about 1:13000 in adult and 1:10000 in children.²

Eventration of diaphragm was first identified in 1774 during autopsy studies conducted by Jean Louis Petit.³ Bisgard was the first to record the difference between a diaphragmatic eventration and a diaphragmatic hernia in 1947.⁴ The unbroken continuity differentiates eventration from diaphragmatic hernia.

Diaphragmatic eventration can either be a congenital or an acquired condition. Congenital eventration is caused due to maldevelopment of the diaphragmatic musculature or absence of the phrenic nerves. Acquired eventration most commonly occurs due to an injury to the phrenic nerve during a traumatic birth or after a thoracic surgery.⁵ Congenital diaphragmatic eventration can rarely present among adults.

Most of the adult patients having a diaphragmatic eventration are asymptomatic. These are sometimes diagnosed incidentally after chest radiography. Among

the patients who are symptomatic, the most common symptom is dyspnoea, orthopnoea and recurrent lower respiratory tract infections. Gastrointestinal symptoms may be present including epigastric discomfort, heartburn, bloating, constipation and weight loss.^{6,7}

CASE SERIES

Case 1

A 56 year male patient presented with pain in abdomen since 1 year aggravated during lifting heavy weight. There was no history of trauma, vomiting, bloating of abdomen or constipation in the past. On examination there was decrease air entry on the left lower side of the chest with soft non-tender abdomen. His pre-operative blood investigations were within normal limit. His ECG showed T inversion in II, III, AVF and V1-6. Patient was also assessed with 2D echo and exercise stress test which were within normal limits. His pulmonary function test was also carried out which showed normal lung function. CT scan chest and abdomen was suggestive of the eventration of diaphragm with diaphragmatic hernia (Figure 1 A and B).

The entire left hemi diaphragm was severely thinned out and elevated. The stomach and spleen were also elevated. A 6x6 defect was noted in the central portion of the left hemi diaphragm. Herniation of the splenic flexure and mesenteric-omental fat was seen into the left hemi thorax.

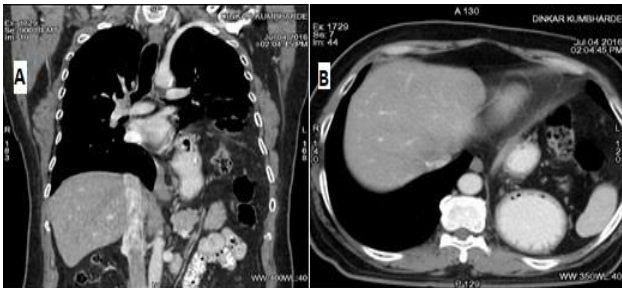


Figure 1: (A and B) CT image showing sagittal and axial view of left diaphragmatic eventration.

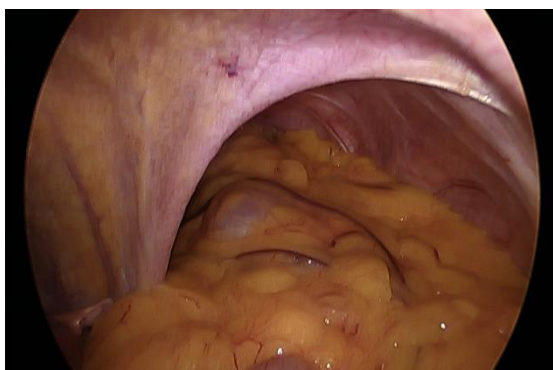

Figure 2: Laparoscopic view of left diaphragmatic eventration with contents reduced.

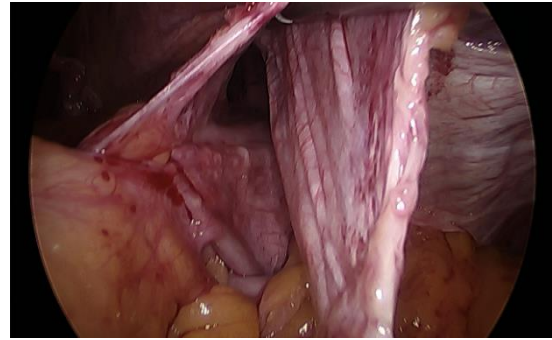


Figure 3: Laparoscopic view of left diaphragmatic musculature with laxity.

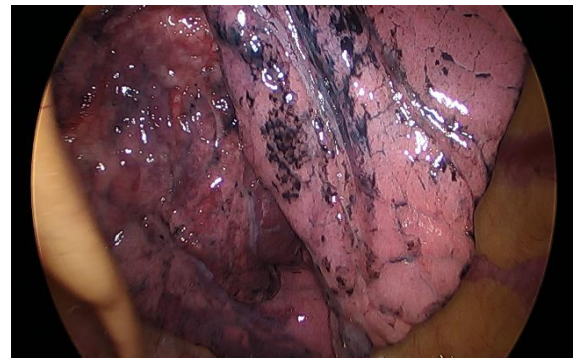

Figure 4: Laparoscopic view of left lung through the diaphragm.

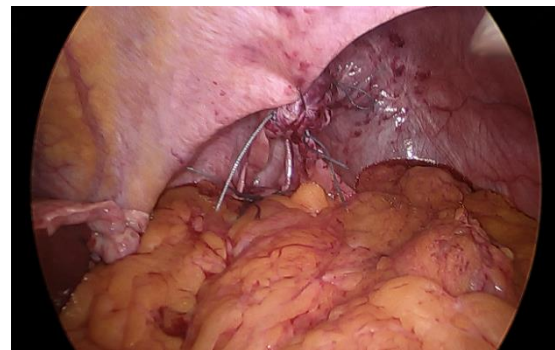


Figure 5: Laparoscopic view of left diaphragm after plication.

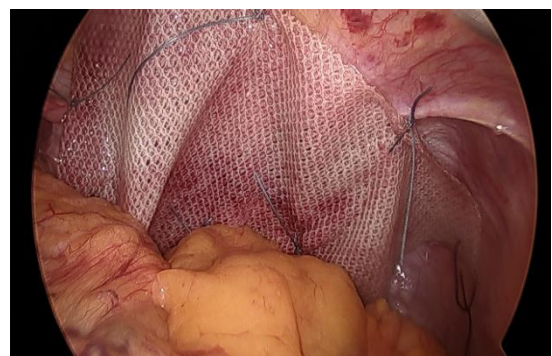


Figure 6: Laparoscopic view of left diaphragm after mesh placement.

Under general anesthesia, initially diagnostic laparoscopy was done which showed eventration of the hemi diaphragm with herniation of the abdominal contents. The contents of the hernia sac were part of the stomach, colon and spleen. The contents were reduced and the diaphragmatic defect noted (Figure 2 and 3).

The left lung was noted in the thoracic cavity once the laparoscope was introduced via the defect into the chest cavity (Figure 4).

The plication of the diaphragm was done in layers for eventration of the diaphragm along with closure of the diaphragmatic defect. A single 20×15 cm composite mesh was placed over the defect and sutured in place (Figure 5 and 6).

Patient was shifted to ICU in the post-operative period and his recovery was uneventful.

Case 2

A 43 year old female came to the OPD with orthopnoea, dyspnoea on exertion and recurrent lower respiratory tract infection. There was no history of trauma, vomiting, bloating of abdomen or constipation in the past. On examination there was decrease air entry on the left lower side of the chest with soft non-tender abdomen. X-ray of the chest showed elevation of the left diaphragm. A CT of the thorax revealed severe thinning out of the left hemi diaphragm and elevation cranially, with the spleen wandering into the left hemi thorax. Her pre-operative blood investigations were within normal limit. She was posted for left thoracoscopic plication of diaphragm.

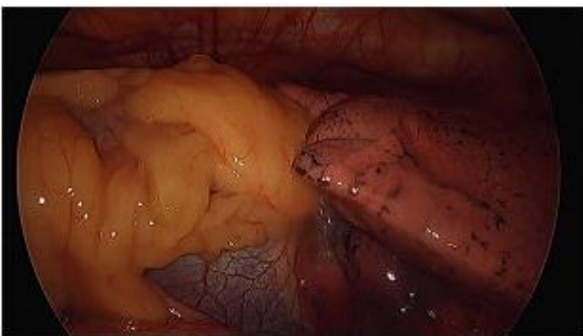

Figure 7: Thoracoscopic view of left diaphragm along with left lung.

On thoracoscopy, with single lung ventilation, the left hemi diaphragm was raised markedly into the left hemi thorax and was severely thinned out. The spleen could be identified as a bluish organ through the diaphragm (Figure 7 and 8).

The lax hemi diaphragm was plicated with multiple buttressing ethibond 2-0 sutures (Figure 9A). Complete lung expansion was achieved after the left lung was

inflated. A 32 number intercostal drainage tube was placed into the left hemithorax (Figure 9B).

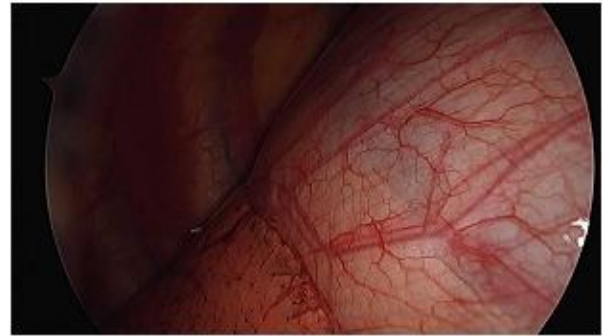

Figure 8: Thoracoscopic view of left diaphragm showing the laxity and splenic hue.

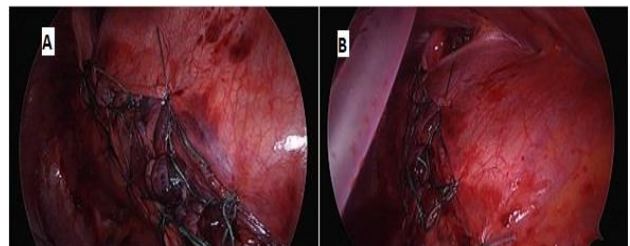


Figure 9: (A and B) Thoracoscopic view of left diaphragm after plication and ICD placement.

Patient was shifted to ICU post op and recovery was uneventful. Inter costal drainage tube was removed on post-op day 10.

Patient's symptoms had significantly reduced one month from surgery on post-operative follow up.

DISCUSSION

The management of diaphragmatic eventration varies according to the symptoms. Asymptomatic cases with minimal eventration required no intervention.⁸ Plication of the diaphragm was a standard, well-described technique for treatment of diaphragmatic eventration.⁹

Diaphragmatic plication can be done using open or minimal access approaches. Open transabdominal or open transthoracic plications were traditionally followed.

Most surgeons recommend diaphragm imbrications using a posterolateral thoracotomy for open transthoracic plication from the sixth, seventh or eighth intercostal space. Numerous techniques had been described which included the use of hand-sewn U stitches, running sutures (with or without pledgets), mattress sutures and stapling devices with or without mesh for additional reinforcement. Some had also advocated resection of the redundant diaphragmatic portion and suturing the tissue in overlapping layers.¹⁰

Open transabdominal plication can be done for unilateral or bilateral diaphragmatic eventration or paralysis.¹¹ Advantages of this approach was that a laparotomy was less morbid than a thoracotomy, single-lung ventilation was not necessary and it gave access to both sides of the diaphragm with the same incision. Disadvantages included the morbidity associated with an open approach and difficult access to the most posterior portion of the diaphragm.

Laparoscopic plication was first described by Hüttl et al.¹² In this, patient was in the supine position and the surgeon stood between the legs. Advantages of laparoscopic plication of the diaphragm were that the intercostal nerve pain during thoracotomy or thoracoscopy was eliminated, single-lung ventilation was not needed and there was an ample space for working with excellent visualization of all structures.

In the thoroscopic approach, the patient was in the lateral decubitus with the surgeon in front or behind of the patient. It can be performed using two ports (with a minithoracotomy), three ports or four ports. A number of plication techniques had been described, including use of continuous sutures, interrupted sutures and laparoscopic stapling devices.

Whatever the approach and technique was used, the basic principle was to make the diaphragm flat and taut in position of full inspiration avoiding abdominal visceral injury.

CONCLUSION

Our experience with these cases demonstrates that patients with recurrent respiratory infections should be investigated thoroughly to exclude rare causes such as eventration of diaphragm. Such patients with unilateral eventration if diagnosed early and treated surgically using minimal access techniques significantly benefit from diaphragmatic plication with minimum risk of morbidity and mortality.

Funding: No funding sources

Conflict of interest: None declared

Ethical approval: Not required

REFERENCES

1. Chin EF, Lynn RB. Surgery of eventration of the diaphragm. J Thorac Surg. 1956;32(1):6-14.

2. Sinha R, Dalal S, Sodhi K. A neonate with eventration of diaphragm. Open Acc Lib J. 2015;2(5):1547.
3. Petit JL: Traité des maladies chirurgicales et des opérations qui leur conviennent/Oeuvres posthumes de chirurgie, mises au jour par M Lesne [FDI. 3 vols. Paris: Prault. 1774;1:230.
4. Guzman JPS, Santos NCD, Baltazar EA, Baquir ATD. Congenital unilateral diaphragmatic eventration in an adult: a rare case presentation. Int J Surg Case Rep. 2017;35:63-7.
5. Shah SZA, Khan SA, Bilal A, Ahmad M, Muhammad G, Khan K, et al. Eventration of diaphragm in adults: eleven years' experience. J Ayub Med Coll Abbottabad. 2014;26(4):459-62.
6. Visouli AN, Mpakas A, Zarogoulidis P, Machairiotis N, Stylianaki A, Katsikogiannis N, et al. Video assisted thoracoscopic plication of the left hemidiaphragm in symptomatic eventration in adulthood, J Thorac Dis. 2012;4(1):6-16.
7. Srikrishna MR, Ravishankar NR, Raghavan J, Natarajan MK, Surgical repair of congenital diaphragmatic eventration in a septuagenarian lady, Braz J Cardiovasc Surg. 2010;25(1):115-7.
8. Mouroux J, Venissac N, Leo F, Alifano M, Guillot F. Surgical treatment of diaphragmatic eventration using video-assisted thoracic surgery: a prospective study. Ann Thorac Surg. 2005;79(1):308-12.
9. Gierada DS, Slone RM, Fleishman MJ. Imaging evaluation of the diaphragm. Chest Surg Clin North Am. 1998;8(2):237-80.
10. Groth SS, Andrade RS. Diaphragm plication for eventration or paralysis: a review of the literature. Ann Thorac Surg. 2010;89(6):2146-50.
11. Kizilcan F, Tanyel FC, Hicsonmez A, Buyukpamukcu N. The long-term results of diaphragmatic plication. J Pediatr Surg. 1993;28(1):42-4.
12. Hüttl TP, Wichmann MW, Reichart B, Geiger TK, Schildberg FW, Meyer G. Laparoscopic diaphragmatic plication: long term results of a novel surgical technique for postoperative phrenic nerve palsy. Surg Endosc. 2004;18(3):547-51.

Cite this article as: Oak AC, Kalikar VR, Patel AK, Patankar RV. Diaphragmatic eventration plication repair with minimal access techniques: a case series. Int Surg J 2021;8:2756-9.