

## Case Report

# Breast ovarian cancer syndrome

Abhirup H. R.<sup>1\*</sup>, Priyanka Kenchetty<sup>2</sup>, Aishwarya K. Chidananda<sup>3</sup>

<sup>1</sup>Department of General Surgery, <sup>2</sup>Department of Dermatology, <sup>3</sup>Department of Radio-Diagnosis, KVG Medical College and Hospital, Sullia, Dakshina Kannada, India

**Received:** 04 June 2021

**Revised:** 13 July 2021

**Accepted:** 20 July 2021

**\*Correspondence:**

Dr. Abhirup H. R.,

E-mail: [abhirup05@gmail.com](mailto:abhirup05@gmail.com)

**Copyright:** © the author(s), publisher and licensee Medip Academy. This is an open-access article distributed under the terms of the Creative Commons Attribution Non-Commercial License, which permits unrestricted non-commercial use, distribution, and reproduction in any medium, provided the original work is properly cited.

### ABSTRACT

BRCA1 and BRCA2, known as breast and ovarian cancer predisposition genes, were discovered in the 1990s. As part of a normal genetic structure, these genes are intrinsic to all human beings, but they are mutated in some individuals increasing the risk for breast and ovarian cancers development. BRCA1 is not only expressed in endocrine tissues but is also detected in other cells such as the neuroepithelial cells in the early stage of cell development. Like BRCA1, BRCA2 is also expressed in a wide variety of tissues and is observed with higher rates in the breast and thymus and with lower rates in the lung, ovary and spleen. We presented to you a case of 40 year old female admitted in surgical ward with lump in the left breast since 2 months with ipsilateral discrete axillary lymphadenopathy. Bilateral sonomammography showed BIRADS V lesion in left breasts with satellite nodules. Ultrasonography of abdomen and pelvis showed large left adnexal solid mass lesion and right sided ovarian cyst with retrocaval, preaortic lymphadenopathy. Patient underwent a diagnostic laparoscopy which was converted to a laparotomy. Total abdominal hysterectomy with bilateral salphingo-oophorectomy was done. For the breast lump, patient underwent left sided modified radical mastectomy. Gene testing for revealed BRCA1 positivity. Chemotherapy was given to cover both breast and ovarian carcinoma. Patient came back with abdominal distension after 9 months and was offered palliative care. Patient succumbed for disease after 1 year after diagnosis. We reviewed the literature for the same.

**Keywords:** Carcinoma breast, Ovarian cancer, BRCA1, BRCA2

### INTRODUCTION

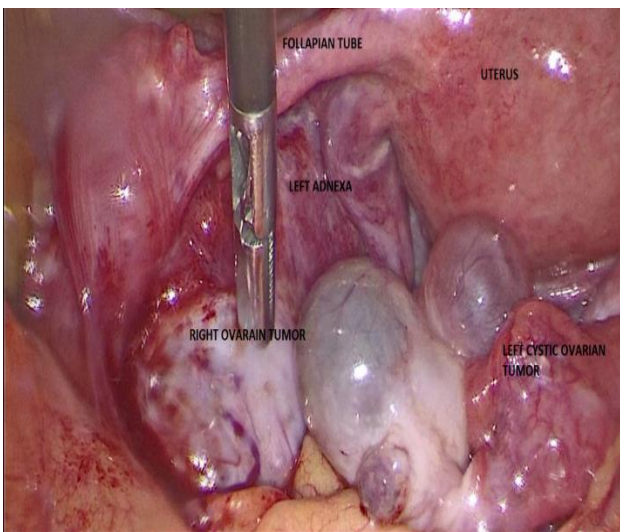
BRCA1 and BRCA2, known as breast and ovarian cancer predisposition genes, were discovered in the 1990s. As part of a normal genetic structure, these genes are intrinsic to all human beings, but they are mutated in some individuals increasing the risk for breast and ovarian cancers development.<sup>1,2</sup> BRCA1 is not only expressed in endocrine tissues, but is also detected in other cells such as the neuroepithelial cells in the early stage of cell development. Like BRCA1, BRCA2 is also expressed in a wide variety of tissues and is observed with higher rates in the breast and thymus and with lower rates in the lung, ovary and spleen.<sup>3,4</sup> BRCA1 is located

on the chromosome 17q21 and has 24 exons. BRCA2 is located on chromosome 13q12 and consists of 27 exons. Mutations in exon 13 of BRCA1 and in exon 11 of BRCA2 gene have been associated with ovarian cancer.<sup>5,6</sup>

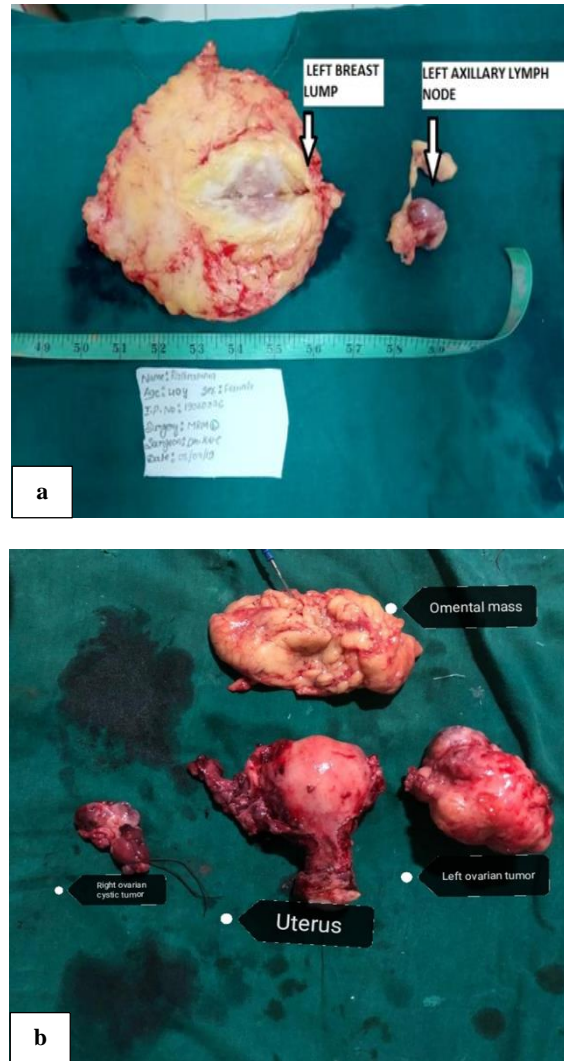### CASE REPORT

Patient was a 40 year old female admitted in surgical ward with lump in the left breast since 2 months. No positive risk factors like early menarche, late conception, abortions, late menopause, OCP use. No co-morbidities were there. No significant past or familial history. Patient was P2L2 with regular cycles. Breast examination revealed a solitary lump measuring 6×5 cms felt in the lower inner quadrant of left breast, non-tender with

irregular borders and surface, hard in consistency, lack of intrinsic mobility and was not fixed to over lying skin or underlying muscle. Left discrete axillary lymph node was palpable of size 2.0×1 cms, non-tender. Opposite breast and supraclavicular area were normal. Systemic examination revealed no positive findings. All routine investigations were within normal limit. Chest X-ray was normal. Bilateral sono-mammography showed BIRADS V lesion in left breasts with satellite nodules. Tru-cut biopsy of lump on left breast showed invasive ductal carcinoma of left breast. USG abdomen and pelvis showed left adnexal solid mass lesion from which left ovary was not separated, multiple enlarged lymph nodes seen in the portal, peripancreatic, retrocaval, preaortic region with right ovarian cyst. Ca 125 levels were >600 IU/ml. Patient underwent a diagnostic laparoscopy which was converted to a laparotomy. Intraoperatively left adnexal mass of size 6×6 cm was noted and mass was found to be adherent to the sigmoid colon and rectum. Cystic mass of size 4×4 cm was noted in right adnexa with loss of contour (Figure 1). Both ovaries distinctly were not visualized. Total abdominal hysterectomy with bilateral salpingo-oophorectomy was done. For the breast lump, patient underwent left sided modified radical mastectomy. Histopathology of breast specimen showed invasive carcinoma breast with ductal carcinoma *in situ* (comedo type). Estrogen receptor (ER)-negative, progesterone receptor (PR)-negative. Histopathology of left ovary showed malignant surface epithelial tumour, grade-III probably endometrioid type and left fallopian tube was positive for tumour infiltration. Gene testing for revealed BRCA 1 positivity. Chemotherapy was given to cover both breast and ovarian carcinoma. Patient came back with abdominal distension after 9 months and was offered palliative care. Patient succumbed from disease after 1 year after the diagnosis.



**Figure 1: Left adnexal mass of size 6×6 cm was noted and mass was found to be adherent to the sigmoid colon and rectum; cystic mass of size 4×4 cm was noted in right ovary.**



**Figure 2: Breast with solitary axillary lymph node; bilateral ovaries with fallopian tubes along with uterus.**

## DISCUSSION

BRCA syndromes only 0.1-0.2% of the general population are carriers of BRCA1 and BRCA2 mutations. BRCA1 and BRCA2 mutations are detected in 2-3% of all breast cancer cases. Families with frequent BRCA mutations are those with early-age breast cancer cases and ovarian cancers occurring at any age. Some populations like Ashkenazi Jews, carry BRCA gene mutations with higher rates.<sup>7</sup> However our patient was a native Indian woman. BRCA1-related breast cancers are usually diagnosed with higher histologic grade, proliferative rate and show a predominance of triple negative pathology compared with sporadic tumors. This triple negative phenotype of BRCA1-related breast cancers was further characterized by a basal-like gene expression profile.<sup>8</sup> Our patient also had triple negative status with invasive ductal carcinoma *in situ*. Serous adenocarcinoma is the main type of cancer in ovarian cancer patients carrying BRCA1/2 mutations, whereas other cancers such as endometrioid and clear-cell

carcinomas occur with a frequency comparable to that of sporadic cases.<sup>9</sup> Our patient also had malignant surface epithelial tumour, grade III probably endometrioid type of the ovary. Breast cancer occurs at an earlier age than the general population in both BRCA1 and BRCA2 families. BRCA2 mutation carriers also present an increased risk of ovarian cancer but the risk is not as high as for the carriers of BRCA1 mutations. The data for the use of chemo-preventive agents such as tamoxifen and raloxifen, in BRCA carriers is controversial. Risk reducing salpingo-oophorectomy and mastectomy are protective surgical interventions that can only be recommended for suitable cases in conjunction with genetic counselling. These surgical procedures enable protection from cancer development with rates of 96% for mastectomy and 90% for salpingo-oophorectomy. The breast cancer risk was also reduced by approximately 50% with salpingo-oophorectomy.<sup>10-15</sup> Our patient underwent total abdominal hysterectomy with bilateral salpingo-oophorectomy was done. For the breast lump, patient underwent left sided modified radical mastectomy.

## CONCLUSION

Finally, the reasons why mutations in BRCA genes lead to the development of breast and ovarian cancers are not clearly understood. Elucidation of the precise molecular functions of BRCA genes is expected to improve our understanding of hereditary as well as sporadic mammary carcinogenesis.

## ACKNOWLEDGEMENTS

This research was partially supported by my parents (H. S. Ramu and K. Parimala) and Dr. K. V. Chidananda (professor in department of general surgery, KVG medical college and hospital).

*Funding: Biocell Pharmaceuticals Pvt Ltd, Chandigarh*

*Conflict of interest: None declared*

*Ethical approval: Not required*

## REFERENCES

- Baretta Z, Mocellin S, Goldin E, Olopade OI, Huo D. Effect of BRCA germline mutations on breast cancer prognosis: a systematic review and meta-analysis. *Medicine (Baltimore)*. 2016;95(40):4975.
- Hughes DJ, Ginolhac SM, Coupier I, Corbex M, Bressac-de-Paillerets B, Chompret A, et al. Common BRCA2 variants and modification of breast and ovarian cancer risk in BRCA1 mutation carriers. *Cancer Epidemiol Biomarkers Prev* 2005;14(1):265-7.
- Xu K, Yang S, Zhao Y. Prognostic significance of BRCA mutations in ovarian cancer: an updated systematic review with meta-analysis. *Oncotarget*. 2017;8(1):285-302.
- Nanda R, Schumm LP, Cummings S, Fackenthal JD, Sveen L, Ademuyiwa F, et al. Genetic testing in an ethnically diverse cohort of high-risk women: a comparative analysis of BRCA1 and BRCA2 mutations in American families of European and African ancestry. *JAMA*. 2005;294(15):1925-33.
- Chodosh LA. Expression of BRCA1 and BRCA2 in normal and neoplastic cells. *J Mammary Gland Biol Neoplasia*. 1998;3(4):389-402.
- Lane TF, Deng C, Elson A, Lyu MS, Kozak CA, Leder P. Expression of BRCA1 is associated with terminal differentiation of ectodermally and mesodermally derived tissues in mice. *Genes Dev*. 1995;9:2712-22.
- O'Quinn C, Steele P, Ludman MD, Kieser K. Hereditary breast ovarian cancer syndromes in the Maritimes. *J Obstet Gynaecol Can*. 2010;32(2):155-9.
- Hanna NN, Mentzer RM. Molecular genetics and management strategies in hereditary cancer syndromes. *J Ky Med Assoc*. 2003;101(3):100-7.
- Neri A, Rabinerson D, Kaplan B, Levani H. Hereditary ovarian cancer. *Isr J Med Sci*. 1995;31(2-3):172-5.
- Casey MJ, Synder C, Bewtra C, Narod SA, Watson P, Lynch HT. Intra-abdominal carcinomatosis after prophylactic oophorectomy in women of hereditary breast ovarian cancer syndrome kindreds associated with BRCA1 and BRCA2 mutations. *Gynecol Oncol*. 2005;97(2):457-67.
- Piek JM, vanDiest PJ, Zweemer RP, Jansen JW, Poort-Keesom RJ, Menko FH, et al. Dysplastic changes in prophylactically removed Fallopian tubes of women predisposed to developing ovarian cancer. *J Pathol*. 2001;195(4):451-6.
- Lee YJ, Lee SW, Kim KR, Jung KH, Lee JW, Kim YM. Pathologic findings at risk-reducing salpingo-oophorectomy (RRSO) in germline BRCA mutation carriers with breast cancer: significance of bilateral RRSO at the optimal age in germline BRCA mutation carriers. *J Gynecol Oncol*. 2017;28(1):3.
- Leeper K, Garcia R, Swisher E, Goff B, Greer B, Paley P. Pathologic findings in prophylactic oophorectomy specimens in high-risk women. *Gynecol Oncol*. 2002;87(1):52-6.
- Schlosshauer PW, Cohen CJ, Penault-Llorca F, Miranda CR, Bignon Y, Dauplat J, et al. Prophylactic oophorectomy: a morphologic and immunohistochemical study. *Cancer*. 2003;98(12):2599-606.
- Barakat RR, Federici MG, Saigo PE, Robson ME, Offit K, Boyd J. Absence of premalignant histologic, molecular or cell biologic alterations in prophylactic oophorectomy specimens from BRCA1 heterozygotes. *Cancer*. 2000;89(2):383-90.

**Cite this article as:** Abhirup HR, Kenchetty P, Chidananda AK. Breast ovarian cancer syndrome. *Int Surg J* 2021;8:2454-6.