

## Case Report

# An incidental concurrence causing gastric outlet obstruction

Abhirup H. R.<sup>1\*</sup>, Priyanka Kenchetty<sup>2</sup>, Aishwarya K. Chidananda<sup>3</sup>

<sup>1</sup>Department of General Surgery, <sup>2</sup>Department of Dermatology, <sup>3</sup>Department of Radio-Diagnosis, KVG Medical College and Hospital, Sullia, Dakshina Kannada, India

**Received:** 04 June 2021

**Revised:** 10 June 2021

**Accepted:** 20 June 2021

**\*Correspondence:**

Dr. Abhirup H. R.,

E-mail: [abhirup05@gmail.com](mailto:abhirup05@gmail.com)

**Copyright:** © the author(s), publisher and licensee Medip Academy. This is an open-access article distributed under the terms of the Creative Commons Attribution Non-Commercial License, which permits unrestricted non-commercial use, distribution, and reproduction in any medium, provided the original work is properly cited.

### ABSTRACT

Phytobezoar which is described as an undigested or incompletely digested food. It is an odd cause of gastric outlet obstruction (GOO). The aim of this study is to present and discuss a case of GOO caused by cicatrised duodenal ulcer with a phytobezoar. 71-year-old male, presented with abdominal pain and vomiting (non-bilious) since 3 days with peptic ulcer disease for 4 years. Examination and investigations revealed a bezoar requiring emergency surgical intervention. An exploratory laparotomy was conducted. A bezoar was palpated in the stomach and removed through posterior gastrotomy. Vagotomy with Posterior Gastrojejunostomy was done as drainage procedure for cicatrised Duodenal ulcer. GOO caused by phytobezoar can co-exist in patients with previous history of peptic ulcer disease and cicatrised duodenal ulcer. Urgent laparotomy may be indicated.

**Keywords:** Gastric outlet obstruction, Bezoar, Acid peptic disease, Carcinoma stomach

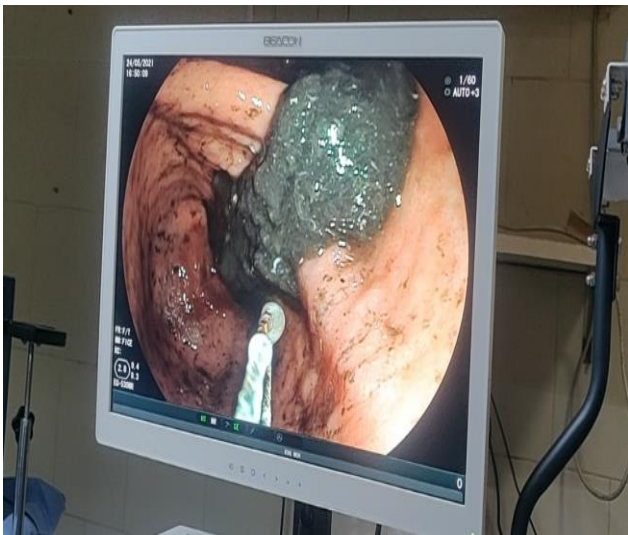
### INTRODUCTION

Phytobezoar causing GOO is a rare disease. Phytobezoar is described as an impacted indigested or incompletely digested vegetable and fruit fibres. Phytobezoar is an infrequent late complication of a previous gastrointestinal operation.<sup>1</sup> Hypoacidity and gastric motility disorders after operation of the stomach are the basis of bezoar formation. These result in compromised gastric emptying even gastroparesis and/or dwindling acid production.<sup>2</sup> Depending on the location and size, signs and symptoms of gastrointestinal bezoars vary, such as abdominal distension, abdominal pain, anaemia or even upper gastrointestinal bleeding-or signs and symptoms of intestinal obstruction because of large intestinal bezoars.<sup>3</sup> Bezoar is a rare cause of GOO. Being multiple and giant is even rarer.<sup>4</sup> The aim of this study is to report case of unusual GOO by a giant bezoar with cicatrised duodenal ulcer in line with SCARE guideline with a brief literature review.<sup>5</sup>

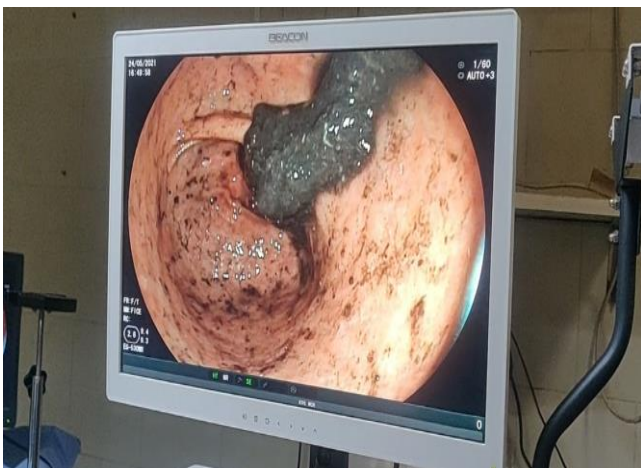
### CASE REPORT

A 71-year-old male brought to the emergency department with abdominal pain and vomiting (non-bilious) for 3-day duration. The character of the pain was colicky in nature associated with nausea. He had no oral intake for two days because of pain. He reported history of dyspepsia and heart burn for which he used to take irregular anti-acid medications for few years before presentation. The condition started to deteriorate in the last 3 days. Peptic ulcer disease present for 4 years and on irregular medication for the same. The patient was fully conscious, mildly dehydrated and was pale. No evidence of jaundice. Heart rate was 100 beats/minute, regular with good volume, blood pressure was 106/84 mmHg and respiratory rate was 20 cycles/minutes. Abdomen was soft on palpation with no palpable mass. Visible gastric peristalsis was present. Bowel sound was normal. Both rectum (by digital examination) and hernia orifices were empty. Laboratory findings demonstrated the followings: Hemoglobin:11 g/dl, packed cell volume: 36%; white

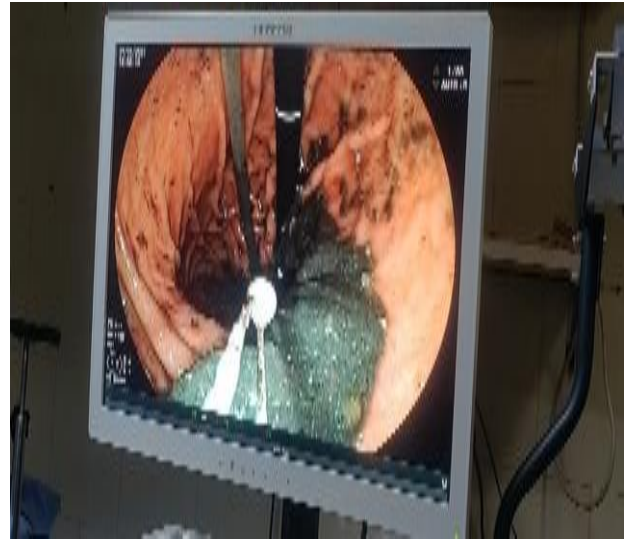blood cells:  $11 \times 10^9$  cells/l; erythrocyte sedimentation rate: 20 mm/hour; blood urea: 6.8 mmol/l; serum creatine: 1.0 mg/dl; serum potassium: 4.0 mmol/l; serum sodium: 136 mmol/l. Abdominal ultrasound displayed a heterogenous, mobile mass occupying body and pylorus of stomach. Esophago-gastro-duodenoscopy (EGD) discovered a soft, bezoar extending from the gastric fundus to the pylorus and entering into duodenum, with evidence of antral gastritis. The endoscope could not be negotiated further into duodenum. (Figure 1-3). The bezoar was soft in consistency but was failed to be retrieved out by the endoscope. Under general anaesthesia, in supine position, the patient under-went emergency laparotomy through a right para-median incision. There was a intra-gastric mass. The bezoar was pulled out through a posterior gastrotomy. Further, Vagotomy with posterior gastrojejunostomy was done. Oral feeding was commenced in the third postoperative day and the patient was discharged in the eighth post-operative day uneventfully. Postoperatively, he was put on oral analgesic and antibiotics for one week. He was followed up for 6 months, the wound was healthy.



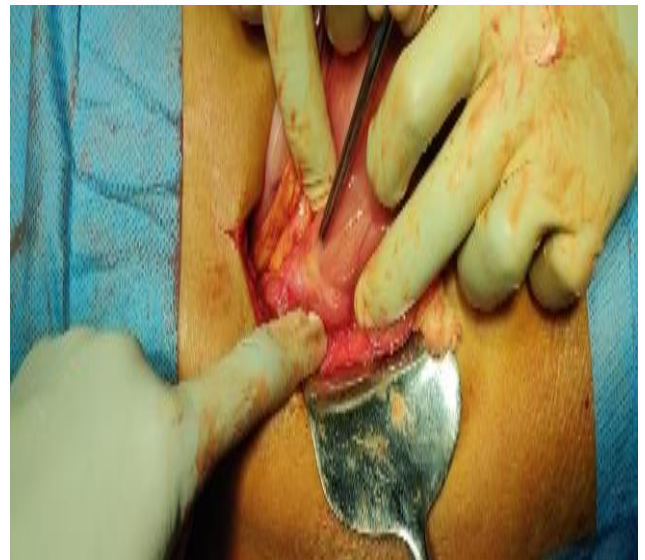**Figure 1: Phytobezoar in pylorus.**



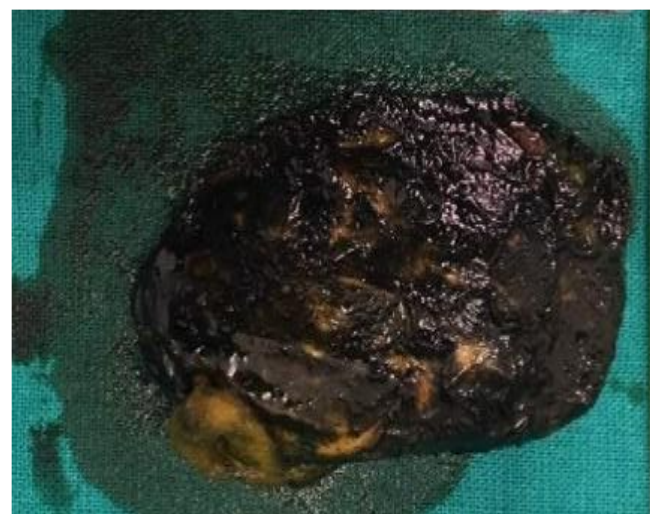**Figure 2: Phytobezoar along lesser curvature.**



**Figure 3: Phytobezoar in D1-duodenum.**



**Figure 4: Chronic cicatrised duodenal ulcer (D1).**



**Figure 5: Post-operative phytobezoar specimen.**

## DISCUSSION

GOO is a clinical syndrome implies to a disease that mechanically impedes gastric emptying. It may be benign or malignant diseases. Previously, a peptic ulcer was the most frequent cause of GOO, ranging up to 90% of cases. The incidence of same has declined with the discovery of the *Helicobacter Pylori* and proton pump inhibitors. At present, 50-80% of cases have been attributed to malignancy.<sup>6</sup> In a study by Samad and associates among 52 patients, they found malignancy in 35% of the cases.<sup>6</sup> The benign etiologies include gastric polyps, gall stone, pyloric stenosis, congenital duodenal webs and pancreatic pseudocysts<sup>7</sup>. Bezoar is regarded as rare benign cause of GOO.<sup>7</sup> Bezoars are categorized into four groups. Types of bezoars are intensive plant fibers (phytobezoar), milk curds (lactobezoar), swallowed hair (trichobezoar) and medications (pharmacobezoar).<sup>8,9</sup> Predisposing factors include delayed gastric emptying (in diabetic mellitus) vagotomy, partial gastrectomy, pyloroplasty, peptic ulcer, chronic gastritis, Crohn's disease, and carcinoma of the gastrointestinal tract.<sup>4</sup> Our case had phytobezoar with cicatrised Duodenal ulcer. In general, patients with bezoar can have vomiting, nausea, and/or symptoms of GOO.<sup>10</sup> Also, symptoms such as upper gastrointestinal bleeding, intestinal obstruction and GOO are rather infrequent.<sup>11</sup> Our patient had features of GOO with the vomiting immediately after intake of non-liquid food and even with liquid food. GOO was confirmed by endoscopy. Bezoar was composed of grey, hard, food fibres. Definitive treatment options include conservative, where patients are prescribed prokinetic and enzymatic dissolvents like cellulose, papain, acetylcysteine and Coco-Cola or mechanical disruption such as endoscopic fragmentation, gastric lavage or extracorporeal lithotripsy.<sup>1</sup> Small bezoar could be treated conservatively.<sup>12,13</sup> Endoscopic approach with fragmentation is needed if the size of bezoar 3 cm, followed by extraction of those fragments which are larger than one centimetre to prevent the risk of intestinal obstruction. Larger gastric bezoars, when uncomplicated, endoscopic removal can be applied.<sup>12,14</sup> A study by Ugenti et al showed a 10-cm bezoar in a 76-year-old male causing pressure ulcer, in which they successfully fragmented the foreign body.<sup>15</sup> A study conducted by Mohammed and colleagues, showed mucosal erosion with subsequent esophagitis and gastritis, as a complication by endoscopic retrieval of bezoar.<sup>9</sup> They even reported a case of intestinal obstruction resulted from a phytobezoar after chemical dissolution for a large phytobezoar in the stomach.<sup>16</sup> Surgical exploration is selected as the initial therapy for patients with GOO, because gastric bezoars presenting with GOO are generally too large to be retrieved cause acute electrolyte imbalance.<sup>17,18</sup> Although it is evident from most of the previous reports that conservative treatment could be safe and effective for bezoars, Surgical consideration can rule out the advancement of serious complications should be considered for multiple giant bezoars with gastric outlet obstruction.<sup>19</sup> The recurrence rate of gastric bezoars has

been documented to be around 14% .<sup>19</sup> Hence, prevention of reformation of the bezoar can be achieved by restricting intake of particular fibres in food especially citrus, persimmon fruits and vegetable fibres. One should grind bolus perfectly, use prokinetics medications like metoclopramide for patients with gastrointestinal dysmotility and behavioural therapy plus selective serotonin receptor inhibitor or tricyclic antidepressants treatment for trichotillomania vegetable fibers.<sup>20</sup>

## CONCLUSION

GOO caused by phytobezoar can co-exist in patients with previous history of peptic ulcer disease and cicatrised duodenal ulcer. Phytobezoar can manifest in patients without history of previous gastric surgery or diabetes mellitus, and should not be underestimated. Early diagnosis and treatment are essential to save the patient life. Alternatively, pharmacotherapy (chemical resolution) and endoscopy are the excellent treatment modalities, surgical approach (laparoscopy and laparotomy) plays an important role in most circumstances.

## ACKNOWLEDGEMENTS

This research was partially supported by Dr. K. V. Chidananda (Professor in Dept of General Surgery, KVG Medical College and Hospital).

*Funding: Biocell Pharmaceuticals Pvt Ltd, Chandigarh*

*Conflict of interest: None declared*

*Ethical approval: Not required*

## REFERENCES

1. Silva FG, Goncalves C, Vasconcelos H, Cotrim I. Endoscopic and enzymatic treatment of gastric bezoar with acetylcysteine. *Endoscopy*. 2002;34:845.
2. Williams RS. The fascinating history of bezoars. *Med J Aust*. 1986;145(1986):613-4.
3. Kurguzov. Bezoars as a cause for acute small intestinal obstruction, *Khirurgiia (Mosk)*. 2004;(12):18-21.
4. Tan F, Mo H, He X, Pei H. *Gastroenterology Report*. 2020;67:154-6.
5. Agha RA, Borrelli MR, Farwana R, Koshy K, Fowler A, Orgill DP. For the SCARE Group, The SCARE 2018 statement: updating consensus surgical Case Report (SCARE) guidelines. *Int J Surg*. 2018;60:132-6.
6. Samad TW, Shoukat KI. Gastric outlet obstruction: change in etiology. *Pak J Surg Gynaecol Obstet*. 2007;23:29-32.
7. Kochhar R, Kochhar S. Endoscopic balloon dilation for benign gastric outlet obstruction in adults. *World J Gastrointest Endosc*. 2010;2:29-35.
8. Tan F, Mo H, He X, Pei H. An unusual case of gastric outlet obstruction caused by multiple giant

- persimmon bezoars. *Gastroenterol Rep (Oxf.)*. 2016;23:pii:gow042.
9. Mohammed AA, Arif SH, Qadir RH. Surgical extraction of a giant trichobezoar: a rare presentation. *Int J Case Rep Images*. 2018;9:1-4.
  10. Kramer SJ, Pochapin MB. Gastric phytobezoar dissolution with ingestion of diet coke and cellulase, *Gastroenterol Hepatol (N Y)*. 2012;8:770-72.
  11. Kaplan JM, Lelcuk IS. Persimmon bezoars as a cause of intestinal obstruction: pitfalls in their surgical management. *Br J Surg*. 1985;72:242-3.
  12. Chiarini BS, Marchegiani C, Corbellini L, Stella S. Endoscopic fragmentation of gastric bezoars as a valid alternative, in selected cases, to traditional surgery. *G Chir*. 1997;18:485-7.
  13. Kuo JY, Mo LR, Tsai CC, Chou CY, Lin RC, Chang KK. Nonoperative treatment of gastric bezoars using electrohydraulic lithotripsy. *Endoscopy*. 1999;31:386-8.
  14. Hung FC, Cho CY, Lo CC, Hwang JJ. Giant gastric phytobezoar successfully eradicated by oral intake plus endoscopic injection of coca-cola. *J Internal Med Taiwan*. 2009;20:2.
  15. Travaglio UE, Lagouvardou E, Caputi Iambrenghi O, Martines G. Successful endoscopic treatment of gastric phytobezoar: a case report, *Int. J.Surg. Case Rep*. 37 (2017) 45–47.
  16. Ha SS, Lee HS, Jung MK. Acute intestinal obstruction caused by apersimmon phytobezoar after dissolution therapy with Coca-Cola. *Korean J Int Med*. 2007;22:300-03.
  17. Mohammed AA, Benmoussa AA, Imeghaiseeb I. Gastric outlet obstruction. *Hepato gastroenterol*. 2007;54:2415-20.
  18. Robles R, Parrilla P, Escamilla C, Lujan JA, Torralba JA, Liron R. Gastrointestinal bezoars. *Br J Surg*. 1994;81:1000-1001.
  19. Hall JD, Shami VM. Rapunzel's syndrome: gastric bezoars and endoscopic management. *Gastrointest Endosc Clin N Am*. 2006;16:111-9.
  20. Pitiakoudis M, Tsaroucha A, Mimidis K. Esophageal and small bowel obstruction by occupational bezoar: report of a case. *BMC Gastroenterol*. 2003;3:13.

**Cite this article as:** Abhirup HR, Kenchetty P, Chidananda AK. An incidental concurrence causing gastric outlet obstruction. *Int Surg J* 2021;8:2505-8.