

## Case Report

# En-block resection of a giant retroperitoneal lipoma presented as huge abdominal swelling: a case report

Rajendra Bagree, Rishab Agrawal, Sweta Gupta\*,  
Pradeep Panwar, Veena Shukla, R. Sanjay

Department of General Surgery, SMS Medical College and Hospital, Jaipur, India

**Received:** 05 June 2021

**Accepted:** 02 July 2021

### \*Correspondence:

Dr. Sweta Gupta,

E-mail: [sweta.gupta31172@gmail.com](mailto:sweta.gupta31172@gmail.com)

**Copyright:** © the author(s), publisher and licensee Medip Academy. This is an open-access article distributed under the terms of the Creative Commons Attribution Non-Commercial License, which permits unrestricted non-commercial use, distribution, and reproduction in any medium, provided the original work is properly cited.

## ABSTRACT

Retroperitoneal lipomas are an extremely rare entity with only less than 20 cases described in the literature so far. They can attain immoderate size due to space provided in the retroperitoneum and cause abdominal symptoms like abdominal pain, swelling and obstipation due to mass effect. Case presented here as of 53 years old male with complaint of abdominal swelling that had been progressive for the last 1 year. On computed tomography (CT) it revealed giant retroperitoneal mass? liposarcoma? occupying the space immensely. Intraoperatively, two giant retroperitoneal tumours were found which did not show any features of infiltration to nearby structures, therefore the sole tumour annihilation was achieved, which was diagnosed as benign lipoma on histopathology report later. The most important differential diagnosis is the well differentiated liposarcoma, which could only be confirmed after resection and histopathological assessment. Retroperitoneal lipomas are clearly not distinguishable from well differentiated liposarcomas on CT guided and USG guided biopsy and thus it could be misleading. Hence surgical resection with negative margins along with histopathological confirmation is treatment of choice with regular follow up to diagnose early recurrence if any.

**Keywords:** Retroperitoneal lipoma, Well differentiated liposarcoma, En-bloc resection, Tumour, Histopathology

## INTRODUCTION

Lipomas are one of the most common benign mesenchymal neoplasm composed of matured adipocytes.<sup>1</sup> Most of the lipomas are encountered in the sub dermal location in the upper half of the body particularly trunk and neck.<sup>2,3</sup> However deep seated lipomas are particularly those originating in the retroperitoneal space are unusual.<sup>4</sup> The etiology of lipomas is still indecisive. Lately a positive adipocyte stem cell turnover has been supposed to be the proposed mechanism.<sup>5</sup>

Many case reports emphasised on the large size of these benign tumours due to potential space available for the tumour growth before they gain clinical attention. The

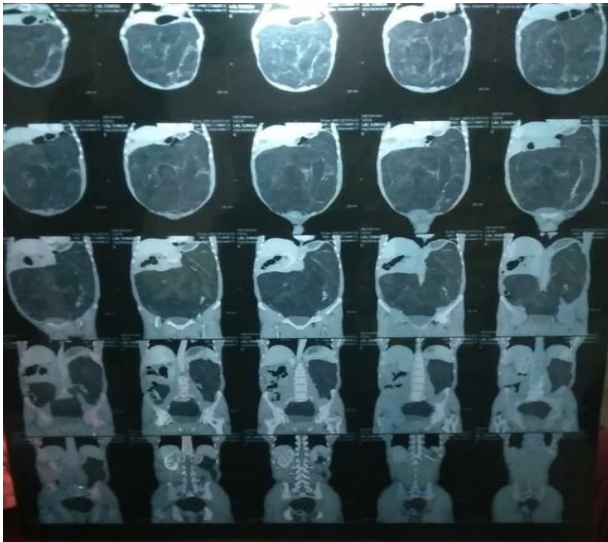
pressure exerted by their exorbitant size on adjacent structures lead to symptoms like pain, protrusion and obstipation.

Liposarcoma are one of the most common sarcomas in the retro peritoneum hence it is the most important differential diagnosis for this case. It is quite difficult to differentiate low grade liposarcoma from benign lipoma solely based on CT and MRI findings, heterogeneity, areas of enhancement or necrosis, irregular margins are often seen on the CT scan of liposarcoma.<sup>6</sup>

Most lipoma are well defined and the presence of fat can be detected on preoperative CT scan and MRI.<sup>4</sup> Histopathological analysis play the role in the confirmatory diagnosis of the case, it assess the mitotic

activity, cellular atypia, necrosis and invasion of the tissue.

We presented here the case of a 53 year old male with a giant retroperitoneal lipoma occupying great parts of the abdomen and measuring 30×22×16 cm and 30×20×11 cm (Figure 1).



**Figure 1: CT scan (Sagittal section) showing giant retroperitoneal lipoma.**

While retroperitoneal lipomas are themselves very rare, and only few retroperitoneal lipomas of such greater size have been reported in the literature.

### CASE REPORT

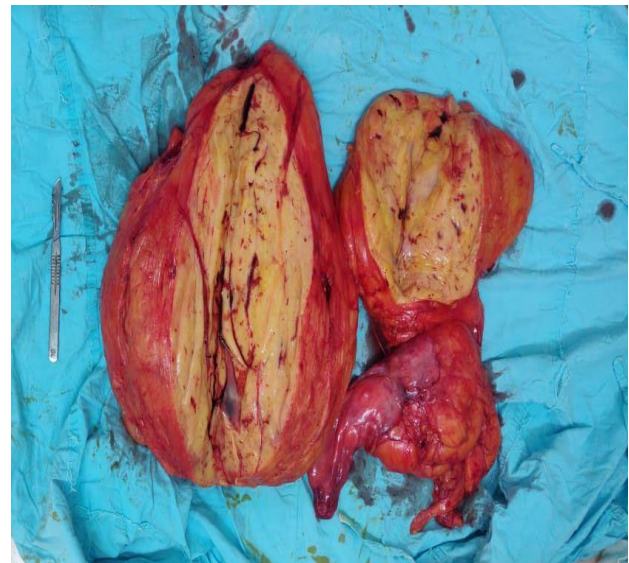In this case report, we presented a case of 53 year old male who was presented with complaint of significant abdominal swelling associated with nausea and feeling of fullness in abdomen with loss of appetite. Swelling was painless and progressively increasing in size since 1 year.

On per abdominal examination the patient's abdomen was hugely distended, occupying all four quadrants of abdomen uniformly and non-tender on palpation.

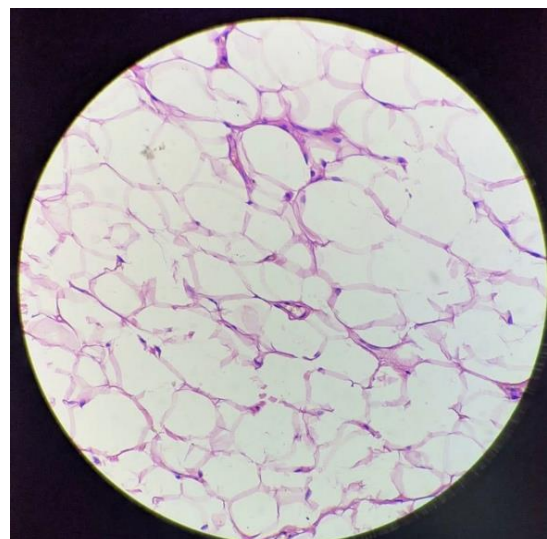
Routine blood investigations including CBC, RFT, LFT, universal marker, RT-PCR for COVID-19, electrolytes, electrocardiogram, X-ray chest revealed no significant pathologies.

A contrast enhanced computerized tomography (CECT) scan revealed a large heterogeneous density lesion predominantly fatty extending from epigastric region to pelvis, it was also extending up to perisplenic region and anterior to stomach and pancreas, abutting left kidney displacing it posteromedial, it was displacing bowel loops on right side. Size of lesion was 278×180×362 mm, suggestive of large mesenteric retroperitoneal mass? liposarcoma? (Figure 2). After detailed interdisciplinary

discussion and evaluation, exploratory laparotomy was planned and performed with aim to either dissect whole tumour or at least debulk the tumour to relieve patient's discomforting symptoms. Intraoperative, we came across two giant retroperitoneal fat tissue masses. One was occupying whole of the right upper and lower quadrants of the abdomen, pushing all the hollow visceral organs, pancreas, right kidney and right ureter to the left and another mass occupying the left retroperitoneal region. Adhesiolysis was done from retroperitoneal soft tissue fat. Feeding vessels identified and ligated. En-bloc dissection was done without injury to other structures and an intra-abdominal drain was put in situ for postoperative vigilance.



**Figure 2: Gross and cut section specimen giant retroperitoneal lipoma.**



**Figure 3: Histopathological image of retroperitoneal lipoma-microscopy showing mature adipose tissue surrounded by thin fibrous capsule; individual fat cells show clear cytoplasm (fat) with eccentric nucleus.**

Patient was monitored for two post-operative day which was uneventful. Intra-abdominal drain was removed after second post-operative day as the drain output was insignificant. Specimen was sent for histopathological examination. Histopathology report suggested two giant specimens consisting of single grey yellow mass measuring right 30×22×16 cm and 30×20×11 cm with weighing 10 kg and 8 kg, respectively.

External surface was smooth and cut surface greyish yellow. Histopathological examination suggestive of well circumscribed lesion composed of mature adipose tissue, consistent with lipoma (Figure3).

## DISCUSSION

Lipomas are composed of adipose tissue and are most common of the benign neoplasm seen in fifth/sixth decade of life. These can be both sporadic and inherited.<sup>6</sup> The origin of these cells is from mesenchymal primordial fat tissue cells, not the adult fat cells.<sup>1</sup> Retroperitoneal lipomas are uncommon which constitutes 2.9% of all primary neoplasm, reportedly 85% of all retroperitoneal tumours are malignant. The incidence of soft tissue sarcomas known to be 4 cases per 100,000 in a year.<sup>7</sup>

Liposarcoma is very common among the soft tissue sarcomas known and located in one third of the cases in the retroperitoneum.<sup>8</sup>

Very often these lesions are found in adults rather than children. Lipomas are generally well encapsulated but deep seated ones may be poorly encapsulated leading to recurrence or relapse, however even with malignant nature these tumours rarely present with features of invasion or obstruction.<sup>9</sup>

Growth of these lipomas are very slow and massive retroperitoneal space allows them to reach enormous size before they show any sign of abdominal swelling or symptoms arising from the pressure effects on adjacent structures until the patient reaches 40-50 years of age.<sup>10</sup>

Diagnosis is based on magnetic resonant imaging or CT scans but both cannot exclude a well differentiated liposarcoma. There are controversies regarding whether it is lipoma or liposarcoma, especially giant lipomas (which by definition should be at least 10 cm in diameter or 1000 gms by weight).<sup>11</sup>

Diagnosis between lipoma and liposarcoma cannot be made preoperatively therefore, judgement about the complete resection with negative margins (R0) is crucial for patient's prognosis especially if it is liposarcoma. Therefore a wide excision should be carried out if infiltrative growth is suspected or if there is any doubt about diagnosis.<sup>12</sup>

In this case lipoma was well encapsulated and clearly circumscribed without any infiltration of adjacent

structures so sole extirpation of the tumour was performed.

Since the clinical and experimental data on the recurrence of tumour and progression was lacking, therefore patient was indicated to be on every one month follow up for a period of six months.

## CONCLUSION

Giant retroperitoneal lipomas are very rare. This case clearly states that a retroperitoneal lipoma can present with such enormous size and cause clinically significant symptoms and, even if massively enlarged are resectable with good clinical outcome. Further research is required to completely understand the underlying etiology and genetic mechanism. Well differentiated liposarcoma appears to be the most important differential diagnosis, hence oncological resection is to be considered in doubtful cases.

*Funding: No funding sources*

*Conflict of interest: None declared*

*Ethical approval: Not required*

## REFERENCES

1. Terada T. Giant fibrolipoma of the spermatic cord. *Pathol Int.* 2010;60(4):330-2.
2. Harrington AC, Adnot J, Chesser RS. Infiltrating lipomas of the upper extremities. *J Dermatol Surg Oncol.* 1990;16(9):834-7.
3. Weiss SW. Lipomatous tumors. *Monogr Pathol.* 1996;38:207-39.
4. Macarenco RS, Erickson-Johnson M, Wang X, Folpe AA, Rubin BP, Nascimento AG, et al. Retroperitoneal lipomatous tumors without cytologic atypia: Are they lipomas? A clinicopathologic and molecular study of 19 cases. *Am J Surg Pathol.* 2009;33(10):1470-6.
5. Suga H, Eto H, Inoue K, Aoi N, Kato H, Araki J, et al. Cellular and molecular features of lipoma tissue: comparison with normal adipose tissue. *Br J Dermatol.* 2009;161(4):819-25.
6. Leffell DJ, Braverman IM. Familial multiple lipomatosis: report of a case and a review of the literature. *J Am Acad Dermatol.* 1986;15:275-9.
7. Casali PG, Jost L, Sleijfer S, Verweij J, Blay JY, ESMO Guidelines Working Group. Soft tissue sarcomas: ESMO clinical recommendations for diagnosis, treatment and follow up. *Ann Oncol.* 2008;19(2):89-93.
8. Dalal KM, Antonescu CR, Singer S. Diagnosis and management of lipomatous tumors. *J Surg Oncol.* 2008;97(4):298-313.
9. Mauro SD, Salibra M, Filippone GF, Trovato P, Sferlazzas G, Pasquale MCD. Clinical comments on a case of retroperitoneal lipoma. *Chir Ital.* 1985;37(1):80-92.

10. Hinman F. *The Principles and Practice of urology.* Philadelphia: WB Saunders Co; 1935.
11. Chander B, Krishna M, Thakur S, Mahajan N, Vij A, Diwakaran J. Extremely rare giant fibrolipoma: a case report. *J Cancer Res Ther.* 2012;8(2):314-6.
12. ESMO/European Sarcoma Network Working Group. Soft tissue and visceral sarcomas: ESMO

clinical practice guidelines for diagnosis, treatment and follow-up. *Ann Oncol.* 2012;23(7):92-9.

**Cite this article as:** Bagree R, Agrawal R, Gupta S, Panwar P, Shukla V, Sanjay R. En-block resection of a giant retroperitoneal lipoma presented as huge abdominal swelling: a case report. *Int Surg J* 2021;8:2484-7.