

Case Report

Main pulmonary artery swing back for univentricular heart

Jecco Ani Babu*, Swaminathan Vaidyanathan, Neville Solomon, Janeel Musthafa

Department of Cardiothoracic surgery, Apollo Children's hospital, Chennai, Tamil Nadu, India

Received: 25 May 2021

Revised: 03 July 2021

Accepted: 30 July 2021

***Correspondence:**

Dr. Jecco Ani Babu,

E-mail: jecco5@yahoo.co.in

Copyright: © the author(s), publisher and licensee Medip Academy. This is an open-access article distributed under the terms of the Creative Commons Attribution Non-Commercial License, which permits unrestricted non-commercial use, distribution, and reproduction in any medium, provided the original work is properly cited.

ABSTRACT

Left pulmonary artery (LPA) surgical arterioplasty done for juxtaductal pulmonary artery coarctation is a challenging technique that has often produced unsatisfactory outcomes because of poor outcome later and incomplete understanding of the evolution of structural changes in these vessels. We report a unique technique for LPA plasty involving main pulmonary artery (MPA) swing back, in a toddler who presented with history of increased work of breathing, cyanosis and failure to thrive since birth, where the MPA was detached and was swung back cranially to be anastomosed to LPA. This technique can be done, especially in univentricular heart (future Fontan candidate), since MPA needs to be interrupted. The patient had heterotaxy syndrome, left atrial isomerism, hypoplastic pulmonary valve with severe sub-valvar stenosis, duct dependent pulmonary circulation, good sized confluent branch pulmonary arteries with LPA narrowing at ductal insertion site, interrupted IVC with hemiazygous continuation and left SVC draining into coronary sinus. Initially underwent right modified Blalock taussig (BT) shunt, atrial septectomy, LPA plasty and PDA ligation at 6 months of age. Upon follow up after a year, diagnostic angiogram confirmed good flow in BT shunt and LPA restenosis with malpositioned great arteries. Redo sternotomy and Kawashima procedure was performed. BT shunt and MPA stump were divided. To conclude, the detached MPA segment was swung cranially and anastomosed to LPA (end to end) inferiorly and left SVC-LPA anastomosed superiorly onto this by end to side fashion. The early outcome was satisfactory, however long-term outcome needs to be followed up

Keywords: Swing back, Arterioplasty, Left pulmonary artery, Univentricular heart, Kawashima

INTRODUCTION

Left pulmonary artery surgical arterioplasty is a challenging technique that has often produced unsatisfactory outcomes. The relationship between stenosis of the left PA and the ductus arteriosus is well known and is referred to as juxtaductal pulmonary artery coarctation.¹ Ductal tissue in a PA and PA stenosis frequently appear together in many congenital heart diseases. It is therefore likely that branch PA stenosis is related to the ductus arteriosus insertion site, which should thus be an important technical consideration when performing surgery. The operative technique usually includes arterioplasty of the ductus insertion site at the time of complete repair.² LPA plasty is one of the

challenging procedures mainly because of the poor outcome in the longer run. LPA stenosis may occur as an isolated finding or in conjunction with other cardiac malformations; it may be congenital or acquired postoperatively.

High-risk situations for the development of postoperative LPA stenosis exist in small infants with hypoplastic branch PA's after a conotruncal procedure, after duct ligation, after shunt insertion, after PA band placement, after pulmonary arteriotomies or anastomoses of any kind.³ Knowledge of the natural history of isolated stenosis of the pulmonary artery branches and an understanding of the evolution of structural changes in these vessels is yet incomplete.⁴ We reported a new operative technique for

LPA plasty involving MPA swing back, where the MPA was detached and was swung back cranially to be anastomosed to LPA. Our technique can be done, especially in univentricular heart (future Fontan candidate), since MPA needs to be interrupted.

CASE REPORT

1 year 6 months old female toddler born to a non-consanguineous parent had history of increased work of breathing, cyanosis, recurrent LRTI and failure to thrive since birth. She was diagnosed to have situs ambiguous, heterotaxy syndrome, left atrial isomerism, hypoplastic PV with severe subvalvar stenosis, duct dependent pulmonary circulation, good sized confluent branch PA's with LPA narrowing at ductal insertion site, anterior aorta from right ventricle, large inlet perimembranous VSD with outlet extension, hypoplastic LV, interrupted IVC with hemiazygous continuation and bilateral SVC with LSVC draining into coronary sinus. She underwent right modified BT shunt, atrial septectomy, LPA plasty and PDA ligation at 6 months of age. Upon follow up by age of 1 year 6 months she was asymptomatic, saturating 70% on bilateral upper limbs and 65% on bilateral lower limbs. Diagnostic angiogram confirmed the above diagnosis. Good flow in BT shunt was noted and LPA re-stenosis with malpositioned great arteries, that is anterior aorta from RV (Figure 1). Kawashima procedure with left lung recruitment was performed. The operation is performed through a redosternotomy. Dense adhesions over RPA and LPA upto the hilum, RSVC, LSVC and MPA stump released. CPB established with aortic, RA and LSVC cannulation with cooling down to 32°C. BT shunt was clipped, divided and sutured. MPA stump divided and cardiac end sutured with running 6-0 polypropylene sutures. Side biting clamp applied to LPA just above hilum and RPA snugged. Narrowed region of LPA excised out.

Detached MPA segment swung cranially and anastomosed (Figure 2) to LPA end to end inferiorly and LSV-LPA anastomosed superiorly onto this by end to side fashion using 7-0 polypropylene sutures (Kawashima procedure). Child was doing well at 6 months follow up, CT showed (Figure 3) good flow in the LPA and Kawashima shunt.

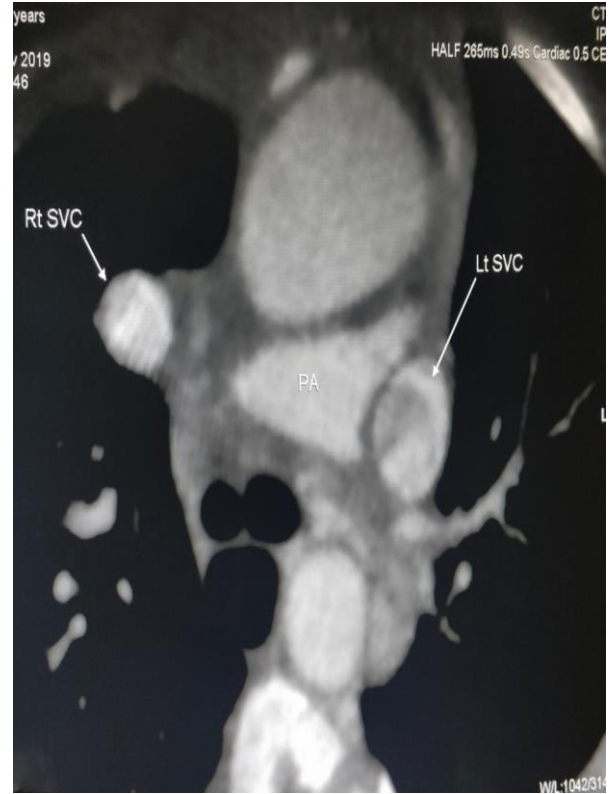

Figure 1: Scan showing patent LPA restenosis after first surgery.

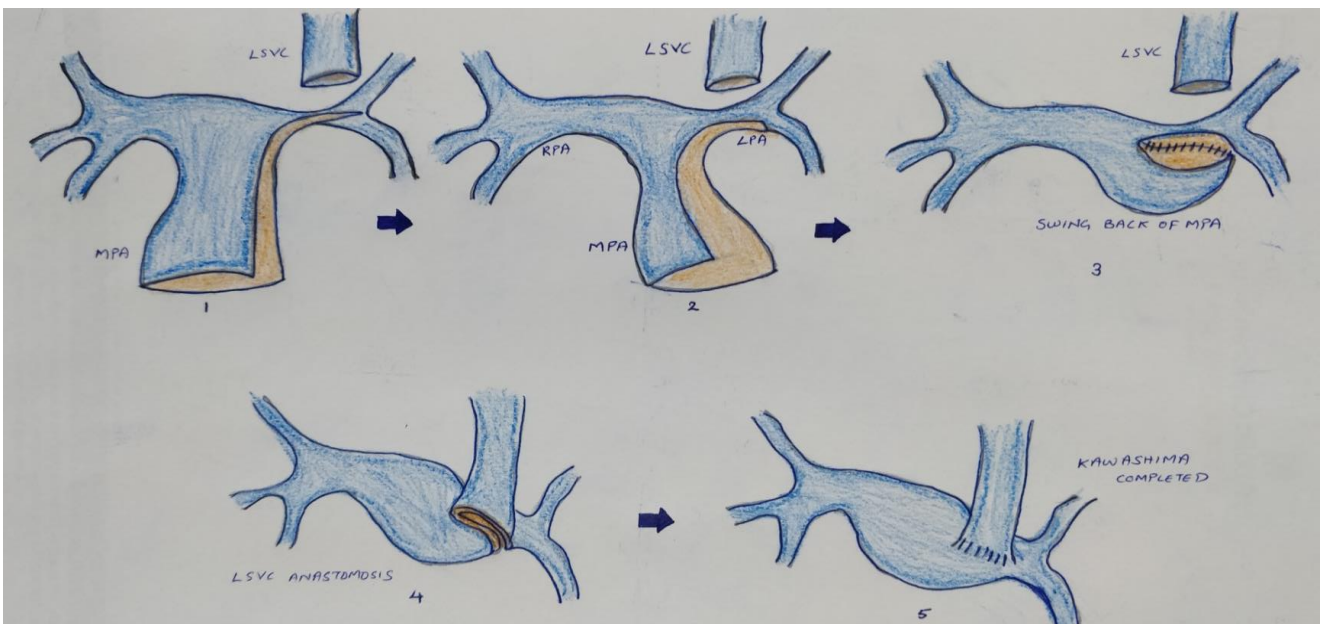


Figure 2: Step by step depiction of MPA swing back plasty.

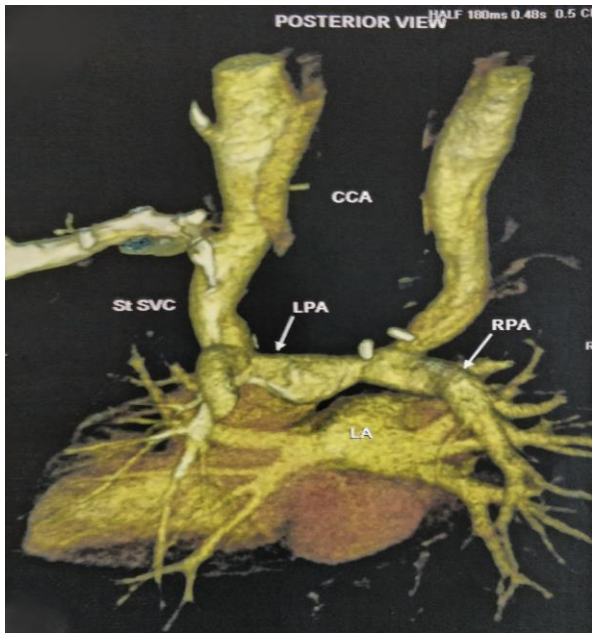


Figure 3: Scan showing patent LPA after MPA swing.

DISCUSSION

LPA plasty is a surgical nightmare to congenital heart surgeons, not because of the procedure per se but because of the long-term patency. It has often produced unsatisfactory outcomes. We believe that this operative technique that involves translocation and pulling back of MPA leads to better patency than pericardial patch plasty. But if the stenotic portion is a long segment, the MPA pull back technique is not suitable because of overstretching. The ideal anatomy for this technique is for patients having a large enough MPA sufficient for translocation.

Classical methods describe an off-pump LPA plasty using a pericardial patch. But this was not possible in our cases as there was no intrinsic lumen. As postulated by Kalangos et al only one of the pulmonary artery branches has the same anatomical direction as the main stem of the PA, either the right or the left pulmonary artery.⁵ This particular feature is important because it can directly affect the surgical outcome; therefore, the patch enlargement (classical technique) must be performed in accordance to the anatomy of the pulmonary arch in each individual case.

In most of the cases a single transannular patch enlargement extending into the LPA is sufficient to repair stenosis of the origin of the LPA when it has the same axis as the main PA. Although a pericardial patch enlargement of the left pulmonary artery coarctation is easily accomplished, recurrent stenosis often develops because of the redundancy or shrinkage of the patch. If the stenosis is localized with biventricular morphology, we prefer the extended end-to-end anastomosis, or 'the sliding technique' (alternative technique) to give enough continuity of the pulmonary arterial tissue than a conventional patch enlargement.⁶ However, if the

stenotic portion is a long segment or completely separated, the sliding technique is not suitable because of overstretching.

Intra-operative pulmonary artery stenting (hybrid technique) is the hybrid approach which is technically difficult, but achievable in small children, especially in patients with small, fragile pulmonary arteries, which are difficult to correct with patch augmentation. In spite of varied techniques, native tissue might be more superior as the material for augmentation than tanned or untanned autologous pericardial patch because of the greater growth potential of the pedicled flap. Distal migration of the stent can occur and may lead to future reintervention.⁷

Yoshida et al reported two patients who had undergone LPA plasty using MPA similar to our technique, but in our case the MPA is transected and the distal stump is translocated to the distal left pulmonary artery.⁸ Oshima et al reported operative approach involving a modification of end-to-end anastomosis, providing a widely patent and nonredundant anastomosis.⁶

CONCLUSION

In our unique technique that we have employed for LPA plasty in an univentricular heart, where we decided to detach the main pulmonary artery segment, swung it cranially and anastomose it to the left pulmonary artery in an end to end fashion. Short term outcome is satisfactory, as demonstrated by postoperative CT pulmonary angiogram. However long-term follow up is needed.

Funding: No funding sources

Conflict of interest: None declared

Ethical approval: Not required

REFERENCES

1. Elzenga NJ, Suylen RJ, Mulder I, Essed CE, Bos E, Quaegebeur JM. Juxtaductal pulmonary artery coarctation. An underestimated cause of branch pulmonary artery stenosis in patients with pulmonary atresia or stenosis and a ventricular septal defect. *J Thorac Cardiovasc Surg.* 1990;100(3):416-24.
2. Hennein HA, Mosca RS, Urcelay G, Crowley DC, Bove EL. Intermediate results after complete repair of tetralogy of Fallot in neonates. *J Thorac Cardiovasc Surg.* 1995;109(2):332-42.
3. Bacha EA, Kreutzer J. Comprehensive management of branch pulmonary artery stenosis. *J Interv Cardiol.* 2001;14(3):367-75.
4. Franch RH, Gay BB. Congenital Stenosis of the pulmonary artery branches. A Classification, With Postmortem Findings In Two Cases. *Am J Med.* 1963;35:512-29.
5. Faidutti B, Christenson JT, Beghetti M, Friedli B, Kalangos A. How to diminish reoperation rates after initial repair of tetralogy of Fallot? *Ann Thorac Surg.* 2002;73(1):96-101.

6. Oshima Y, Yoshiro D, Shimazu C, Misaki T. Left pulmonary arterioplasty--extended end-to-end anastomosis. *Ann Thorac Surg.* 2005;79(5):1795-6.
7. Chakraborty B, Hagler D, Burkhart HM, Dearani JA. Intraoperative hybrid left pulmonary artery stenting. *Ann Pediatr Cardiol.* 2013;6(1):43-5.
8. Yoshida M, Oshima Y, Shimazu C, Matsuhisa H, Higuma T, Okita Y. Main pulmonary artery

translocation for left pulmonary stenosis. *J Thorac Cardiovasc Surg.* 2007;133(4):1100-1.

Cite this article as: Babu JA, Vaidyanathan S, Solomon N, Musthafa J. Main pulmonary artery swing back for univentricular heart. *Int Surg J* 2021;8:2799-2802.