

Research Article

Retrospective study of upper digestive tract foreign bodies in central India

Yamini Gupta*, Govind Gourh, R. K. Mundra

Department of Otorhinolaryngology, MYH Hospital and MGM Medical College, Indore, Madhya Pradesh, India

Received: 30 June 2015

Accepted: 11 July 2015

***Correspondence:**

Dr. Yamini Gupta,

E-mail: dryamini10@gmail.com

Copyright: © the author(s), publisher and licensee Medip Academy. This is an open-access article distributed under the terms of the Creative Commons Attribution Non-Commercial License, which permits unrestricted non-commercial use, distribution, and reproduction in any medium, provided the original work is properly cited.

ABSTRACT

Background: Variety of foreign bodies may enter the digestive tract accidentally. Many pass spontaneously, but some become impacted, causing symptoms of obstruction. The cricopharynx and esophagus are the most common site of impaction. Nearly, all impacted objects can be removed endoscopically but, occasionally open surgery may be required. Objectives: This study was conducted on 228 patients with the aim to describe age-sex incidence, socioeconomic and geographical distribution, types of foreign body ingested and management strategy.

Methods: Retrospective study was conducted in tertiary care hospital of Central India on 228 patients who had undergone rigid endoscopic removal of digestive tract foreign body from January 2007 to January 2014.

Results: Foreign body ingestion was found most commonly in the age group of 1-3 year. (133; 58.33%) with male predominance. 180 patients (78.94%) belonged to lower socioeconomic status. Out of them 160 patients came from rural areas. Definitive history was found in (212; 92.98%) patients with dysphagia to solid as the most common presenting symptom. Most of the foreign bodies were detected by plain X-rays (203; 89.03%). Coin was found to be the most commonly ingested foreign body (67.54%). Cricopharynx was the most common site of impaction (86.4%). Rigid endoscopic removal under general anesthesia was successful in all 228 patients.

Conclusions: Higher incidence of ingestion of foreign body is in toddlers. The most common site of lodgement was at the cricopharynx and upper third of esophagus. Early detection and rigid endoscopic removal can prevent from morbidity associated with the complications of foreign body impaction.

Keywords: Foreign body, Coin, Cricopharynx, Endoscopic removal

INTRODUCTION

Majority of the foreign body ingestions occur in patient between age of 6 months and 6 years.¹ They have high propensity for placing every objects in their mouth. Incomplete dentition and immature swallowing coordination may also play a role, tendency to cry, laugh & play during eating add to this.² Coin is the most commonly ingested foreign body in paediatric population.² Meat impaction is the most common cause of oesophageal obstruction in adults, in which mutton or

chicken bone is the offending agent followed closely by artificial denture.³ Psychiatric disorder, alcohol intoxication, development delay and secondary gain seeking behaviour favours true foreign body ingestion (i.e., non-food objects) in adults.⁴

Most foreign body passes uneventfully through the gastrointestinal tract, but some may get impacted at any site in the oesophagus; post cricoid area and cricopharynx are the most frequent locations, followed by pylorus, duodenum, duodenojejunal flexure etc.

Radiographic evaluation including X-ray chest P-A view and X-ray Soft tissue neck lateral view can detect the location and type of foreign body and guides to plan removal strategy.

Rigid endoscopy under general anaesthesia is found to be safe and effective method. Here, we are presenting our experience of 228 cases of different types of FBs in upper digestive tract, their clinical presentations, site of impaction, management options and treatment outcomes.

METHODS

This retrospective study was done in department of otorhinolaryngology in tertiary care hospital of Central India from January 2007 to January 2014 on patients who were referred from various district hospitals and clinics. Data was collected from medical record section and analysed retrospectively. A total of 228 patients of digestive tract foreign body were taken and categorized according to age and sex incidence, socioeconomic status, geographical distribution, symptoms of presentation, radiographic evaluation, site of impaction, type of foreign body and removal method used.

All foreign bodies were removed by rigid endoscopy under general anaesthesia and postoperative period was uneventful.

RESULTS

Total 228 patients were analysed in our setting ranging from 1 to 60 years of age (Table 1). Most of the patients [133 (58.33%)] were from age group of 0 -3 year, due to their higher propensity to place every object in mouth.

Table 1: Distribution of patients according to age group.

Age group	Cases	Percentage
1-3 years	133	58.33
3-6 years	60	26.31
6-20 years	09	3.94
20-40 years	20	8.77
40-60 years	03	1.31
>60 years	03	1.31

Out of 228 patients male [148 (64.9%)] outnumbered the females [80 (35.08%)].

A higher number [180 (79.9%)] belonged to low socioeconomic status, and most of them came from rural areas [160 (70.01%)].

The most common presenting symptom was sudden onset dysphagia to solids [212 (92.98%)] followed by pain in throat and vomiting. Cough, dyspnea, stridor, and mild distress were found to be associated with large foreign bodies (Figure 1) which were impinging upon trachea and

therefore they were considered for emergent removal (Table 2).



Figure 1: Showing large atraumatic plastic cap removed from oesophagus.

Table 2: Distribution of patients according to presenting symptoms.

	Cases	Percentage
Sudden onset of dysphagia	212	92.98
Pain in throat	208	91.22
Vomiting	64	28.07
Epigastric pain	20	8.77
Cough	12	5.26
Dyspnea	8	3.50
Distress	4	1.75
Stridor	3	1.31

Most of the foreign bodies were detected by plain X-ray chest AP and soft tissue neck lateral view (Figure 2). X-ray barium swallow was used for radiolucent vegetative foreign bodies, plastic objects and mutton piece without bone.

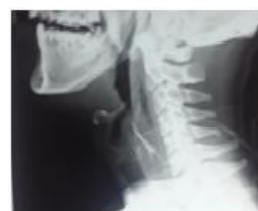

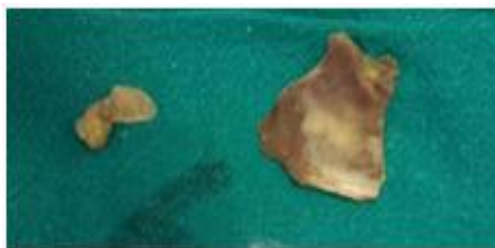
Figure 2: X-ray ST neck lateral view showing irregular sharp radioopaque FB shadow at cervical 4,5,6 vertebrae.

Cricopharynx was found to be the most common site of impaction in [197 (86.4%)] others were upper 3rd of esophagus and postcricoid region from where one shaving blade and nail was removed (Table 3).

In 0-20 years of age coin was found to be the most common foreign body 154 (67.54%). Sharp bone was most commonly impacted foreign body found 16 (7.01%) in 20-40 years (Figure 3). In age group of 40-60 years mutton piece [5 (2.19%)] was most commonly impacted foreign body and in age group of >60 year artificial dentures [3 (1.31%)] was most common (Table 4).

Table 3: Distribution of patients according to site of impaction.

Site	Cases	Percentage
Pyriform fossa	02	0.87
Post cricoids	01	0.43
Cricopharynx	197	86.40
Upper 1/3 rd oesophagus	27	11.84
Middle 1/3 rd oesophagus	01	0.43
Lower 1/3 rd oesophagus	00	0

**Figure 3: Sharp large chicken bone removed.****Table 4: Age wise distribution of patients according to type of foreign body.**

Type of foreign body	No. of cases	Percentage
Age (0-20) year		
Metallic objects:		
Coin	154	79.82
Battery cell	18	7.89
Safety pin	04	1.75
Ear ring	03	1.31
Button	03	1.31
Non-metallic:		
Plastic objects	03	1.31
Smaller vegetative seeds	16	7.01
Age (20-40) year		
Meat/bone:		
Fish bone	12	5.26
Chicken bone	04	1.75
Metallic objects:		
Nail	1	0.43
Shaving blade	1	0.43
Vegetative seed:		
Mango seed	1	0.43
Age (40-60) year		
Mutton piece	05	2.19
Age >60 year		
Denture	03	1.31

In our series all foreign bodies were removed by endoscopy under general anesthesia. Most foreign body were removed by rigid esophagoscopy [218 (95.61%)] and rest were managed by direct laryngoscopic removal. (Figure 4).

**Figure 4: Showing tablet with sharp packing removed from pyriform fossa of a 6 month old child by direct laryngoscopy.**

DISCUSSION

Foreign body impaction in esophagus is one of the common problems met within day-to-day otorhinolaryngological practice and the victims mainly are children.

In children most of the foreign body were ingested accidentally while playing and in some of them foreign body were put into mouth by similar kins, while in adults most of the foreign body were ingested during alcoholism.^{1,2}

Younger children less than 5 years of age are most likely to ingest battery cell, most of them were from watches, hearing aids, toys, games and calculators.⁵

In our study also most of the patients (58.33%) were from age group of 0-3 year, due to their higher propensity to place every object in mouth.

A higher number (79.9%) belonged to low socioeconomic status, and most of them came from rural areas (70.01%).

Many children with esophageal foreign body are asymptomatic but in some the foreign body can make the child refuse to eat, and can produce symptoms of dysphagia, coughing, drooling, stridor, vomiting and foreign body sensation.⁶

In our series the most common presenting symptom was sudden onset dysphagia to solids (92.98%) followed by pain in throat and vomiting. Cough and dyspnoea were found to be associated with large foreign bodies which were impinging upon trachea.

Radiographic evaluation including soft tissue lateral neck radiograph and wide chest radiograph of neck and chest suggests the level of impaction. It also gives clues regarding shape, size and nature of foreign body. Coins and battery cell are usually oriented coronally in the esophagus mostly at level of cricopharynx. Radiographically, battery cell shows a "double contour or double ring shadow" on the antero-posterior view and "shouldering" on the lateral view in neck radiograph. Radiolucent foreign bodies such as plastic, glass objects,

vegetable seed, wooden stick can be detected by endoscopy or contrast radiography.⁷

Timing of endoscopy is very crucial to reduce the morbidity and mortality. Disc batteries and sharp pointed objects with obstructive symptoms requires emergent endoscopic removal. Blunt foreign body like coins, food bolus not causing complete obstruction, magnets and objects < 2.5 cm diameter in an asymptomatic patients can be observed for 24-48 hours, but after 48 hours they must be removed endoscopically irrespective of their clinical presentation.⁸

Rigid esophagoscopy under general anesthesia with orotracheal intubation is preferred method for removal of foreign body impacted at level of cricopharynx while pyriform sinus foreign body could be removed by direct rigid laryngoscopy. Retrieval forceps, polypectomy snare or a retrieval net are commonly used to remove sharp foreign body⁹ while smooth soft and non-opaque foreign body such as meat without bone or mutton piece can be removed with help of fluoroscopic guided Foley's catheter¹⁰ or may be pushed into the stomach with help of esophageal bougie.¹¹ An alternative is small calibre transnasal endoscope.¹² and 1.0 mg glucagon administration can be tried to cause relaxation of distal esophagus and allows spontaneous passage of impacted bolus in adults.^{13,14}

Rigid endoscopic removal is preferred over fluoroscopic guidance because, it does not provide airway protection, having poor visualization of underlying esophageal pathology and lacks of control over object as it may be removed or may pass into stomach.^{15,16}

In our series all foreign bodies were removed by endoscopy under general anesthesia. Most foreign body were removed by rigid esophagoscopy [218 (95.61%)] and rest were managed by direct laryngoscopic removal.

Impacted foreign bodies which are associated with complication risk such as perforation or obstruction. Foreign body which cannot be removed endoscopically, which are present distal to the esophagus and who do not show progression for several weeks should be considered for open surgical removal via laparotomy.¹⁷

Blunt and flat foreign bodies do not cause any harm to the esophagus early but sharp foreign body such as bone piece and safety pin may causes retropharyngeal edema and air impaction around foreign body which in long term may develop into retropharyngeal abscess.

Battery cell impaction is much dangerous and it leads to release of alkali chemicals which causes local irritation, edema, corrosion of mucosa, and stricture formation so should be removed immediately. Rare complications of long term foreign body impaction includes esophageal perforation, mediastinitis, tracheo-esophageal fistula,

visceral rupture, peritonitis, and abscess formation.¹⁸ In our series no such complications were seen.

CONCLUSION

- The foreign body ingestion is most commonly seen in children less than 3 years.
- All children with foreign body ingestion should undergo radiographic examination so as to determine the size, shape and type of foreign body.
- Asymptomatic patients may be observed upto 24 hours while symptomatic patients with sharp foreign body and battery cell should be considered for emergency removal.
- Rigid esophagoscopy under general anesthesia is a safe and effective method for removal of foreign body.
- Foreign body which passed to the stomach and associated with complications such as perforation, peritonitis and abscess should undergone urgent laparotomy and surgical removal.

ACKNOWLEDGEMENTS

We are thankful to Superintendent MY hospital for permitting us to use hospital records.

Funding: No funding sources

Conflict of interest: None declared

Ethical approval: Not required

REFERENCES

1. Webb WA. Management of foreign bodies of the upper gastrointestinal tract: update. *Gastrointest Endosc.* 1995;41:39-51.
2. G. Paul Digoy. Diagnosis and management of upper aerodigestive tract foreign bodies. *OCNA.* 2008;41:485-96.
3. Prakash Adhikari, Bikesh Lal Shrestha, Dharma K. Baskota, Bimal K. Sinha. Accidental foreign body ingestion: analysis of 163 cases. *Arch Otolaryngol.* 2007;11(3):267-70.
4. Palta R, Sahota A, Bemarki A, Salama P, Simpson N, Laine L. Foreign-body ingestion: characteristics and outcomes in lower socioeconomic population with predominantly intentional ingestion. *Gastrointest Endosc.* 2009;69:426-33.
5. Litvitz EL, Schmitz BF. Ingestions of cylindrical and button batteries: an analysis of 2382 cases. *Pediatrics.* 1992;89:747-57.
6. Hachimi-Idrissi S, Come L, Vandempias Y. Management of ingested foreign bodies in childhood: our experience and review of literature. *Eur J Emerg Med.* 1998;5:319-23.

7. Naid Dehghani. Ingested foreign bodies in children: BC children's hospital emergency room protocol. BC Med J. 2008 June;5(5):257-62.
8. ASGE Standards of Practice Committee, Steven O. Ikenberry, Terry L. Jue, M. Anderson, V. Appalaneni, S. Banerjee, et al. Management of ingested foreign bodies and food impactions. Gastrointest Endosc. 2011;73(6):1085-91.
9. Faigel DO, Stotland BR, Kochman ML, Hoops T, Judge T, Kroser J, et al. Device choice and experience level in endoscopic foreign object retrieval: an *in vivo* study. Gastrointest Endosc. 1997;45:490-2.
10. Nixon GW. Foley catheter method of esophageal foreign body removal: extension of applications. Am J Radiol. 1979;132:441-2.
11. Bonadio WA, Jona JZ, Glicklich M, Cohen R. Esophageal Bougie technique for coin ingestion in children. J Pediatr Surg. 1988;23:917-8.
12. Chu KM, Choi HK, Tuen HH, Law SY, Branicki FJ, Wong J. A Prospective randomized trial comparing the use of the flexible gastroscope versus the broncoscope in the management of foreign body ingestion. Gastrointest Endosc. 1998;47:23-7.
13. Ferruci TJ, Long JA. Radiographic treatment of esophageal food impaction using intravenous glucagon. Radiology. 1977;125:25-8.
14. Trenkner SW, Maglante D, Lehman GA, Chernish SM, Miller RE, Johnson CW. Esophageal food impaction treatment with glucagon. Radiology. 1983;149:40.
15. Schunk JE, Harrison AM, Corneli HM, Nixon GW. Fluoroscopic Foley catheter removal of esophageal foreign bodies in children: experience in 415 episodes. Pediatrics. 1994;94:709-14.
16. Gaigel DO, Fennerty MB. Miscellaneous disease of the esophagus. In: Gaigel DO, Fennerty MB, eds. Textbook of Gastroenterology. 1st ed. Philadelphia: Lippincott Williams and Wilkins; 1999: 1304-1325.
17. Cheng W, Tam PKH. Foreign body ingestion in children: Experience with 1265 cases. J Paediatr Surg. 1999;34:1472-6.
18. Schunk JE. Foreign body ingestion/aspiration. In: Schunk JE, eds. Textbook of Pediatric Medicine. 5th ed. Philadelphia: Lippincott Williams and Wilkins; 2006: 307-314.

Cite this article as: Gupta Y, Gourh G, Mundra RK. Retrospective study of upper digestive tract foreign bodies in central India. Int Surg J 2015;2:539-43.