

Case Report

Primary antiphospholipid antibody syndrome presenting as acute superior mesenteric vein thrombosis

Vignesh N. C.*, Manivannan D., Maniselvi S., Kannan R.

Department of General Surgery, Madras Medical College, Chennai, Tamil Nadu, India

Received: 04 April 2021

Revised: 09 May 2021

Accepted: 11 May 2021

*Correspondence:

Dr. Vignesh N. C.,

E-mail: nc.vignesh94@gmail.com

Copyright: © the author(s), publisher and licensee Medip Academy. This is an open-access article distributed under the terms of the Creative Commons Attribution Non-Commercial License, which permits unrestricted non-commercial use, distribution, and reproduction in any medium, provided the original work is properly cited.

ABSTRACT

Antiphospholipid antibody syndrome (APS) is an autoantibody mediated thrombophilia characterised by recurrent arterial or venous thrombosis and/or pregnancy morbidity. APS presenting as thrombosis in mesenteric venous system is relatively uncommon (10%). Here, we present a case of primary APS presenting as acute superior mesenteric vein (SMV) thrombosis in a 38-year-old female. She was admitted with the complaints of abdominal pain and constipation for five days. Her abdomen was distended with sluggish bowel sounds. Her abdominal contrast enhanced computed tomography revealed thrombosis of SMV, splenic vein and portal vein. She was initially kept on conservative management and started on anticoagulants. Her coagulation work-up revealed that she was positive for anticardiolipin antibody and therefore, the diagnosis of APS was made. She was continued on conservative management and anticoagulants. On the tenth day of admission, after starting oral diet, she developed severe abdominal pain and abdominal signs of peritonitis. She was then taken up for emergency laparotomy. Intraoperatively; there was 100 cm of gangrenous ileal segment, about 60 cm from ileocecal junction and 160 cm from duodenojejunal flexure. The gangrenous ileal segment was resected and a double barrel ileostomy was constructed. She had an uneventful postoperative recovery and was started on lifelong anticoagulants.

Keywords: Antiphospholipid antibody, Mesenteric ischemia, Venous thrombosis, Anticoagulant

INTRODUCTION

Acute mesenteric ischemia is a severe life-threatening gastrointestinal emergency, accounting for 1 in 1000 hospital admissions worldwide, with a mortality of 40%.^{1,2} It is characterised by decreased mesenteric blood supply to visceral organs of gastrointestinal tract. It is classified into four different types based on underlying cause: non-occlusive, arterial thrombosis, arterial embolic and venous thrombosis. Amongst these, venous thrombosis is the least common cause. Mesenteric venous thrombosis (MVT) in the setting of APS is uncommon. Once the diagnosis of MVT is made, a search for underlying cause is a must. This helps us determine the duration of anticoagulation, in order to prevent recurrent

thrombosis in such patients. The duration of anticoagulation varies depending on the underlying conditions associated with MVT such as inflammation, malignancy and thrombophilia like APS, as in our patient. Local inflammation is considered temporary and potentially treatable, so patients are anticoagulated for 3 to 6 months. In case of underlying malignancy or thrombophilia, lifelong anticoagulation is required, to prevent recurrent thrombosis in such patients.

CASE REPORT

This is a case of 38 years aged female who presented with 5 days history of abdominal pain, nausea and vomiting. She had previous history of two spontaneous

abortions. Contrast enhanced computed tomography (CECT) abdomen revealed thrombosis of SMV, portal vein, splenic vein, poorly enhancing bowel wall with thickening of jejunum (Figure 1), superior mesenteric artery (SMA) was normal and there was no evidence of pneumatosis intestinalis. Patient was diagnosed as a case of mesenteric vasculitis, due to SMV thrombosis and it was confirmed by abdominal angiogram. She was managed conservatively and started on intravenous heparin. Her serum antinuclear antibody was negative. Anticardiolipin antibody was positive. Given the finding of primary APS with SMV thrombosis, she was continued on anticoagulants. On tenth day after admission, three days after starting diet, she developed severe abdominal pain and abdominal signs of peritonitis. She was then, taken up for emergency laparotomy. Ileal gangrene was noted, for about 100 cm, which was 60 cm from ileocaecal junction and 160 cm from duodenojejunal junction (Figure 2 and 3). We proceeded with resection of gangrenous ileal segment, proximal end ileostomy and distal mucous fistula was done. Post-operatively, she was started on low molecular weight heparin (LMWH) and later changed to oral warfarin. She was advised to continue lifelong oral warfarin, to prevent recurrent thrombotic attacks.

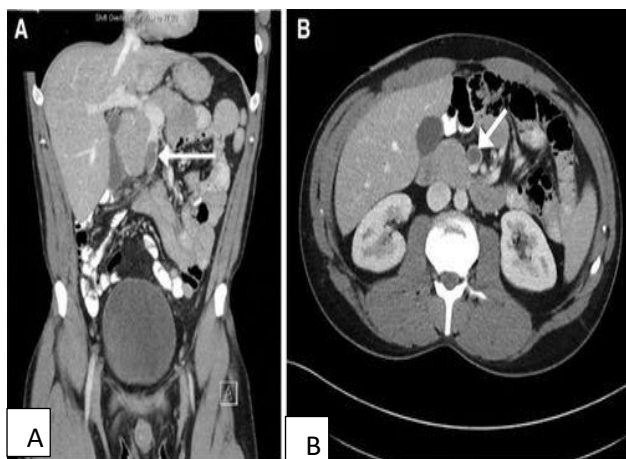


Figure 1: (A and B) CECT abdomen of SMV thrombosis.

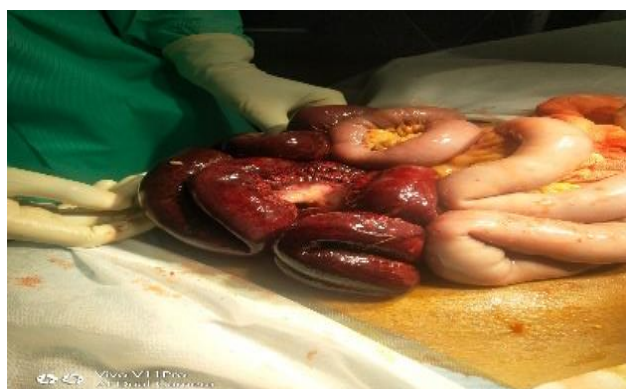

Figure 2: Gangrenous ileal segment (intra-operative image).

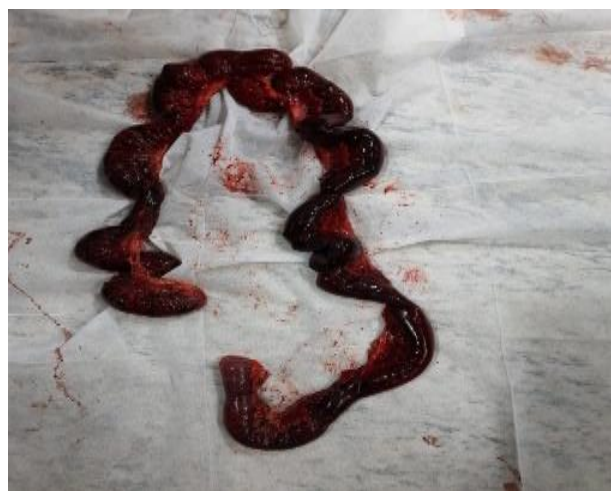

Figure 3: Resected gangrenous ileal segment.

DISCUSSION

Most patients with acute mesenteric vein thrombosis (MVT) have predisposing risk factors like inflammatory process, thrombophilia or malignancies.^{1,2} Rarely, autoimmune thrombophilia like APS, can cause acute MVT. The diagnosis of APS can be made with classical clinical findings and laboratory evidence of antiphospholipid antibodies (aPL) like lupus anticoagulant or IgG or IgM antibodies to cardiolipin or beta 2-glycoprotein.^{3,4} Reports of seronegative APS with clinically significant thrombosis and atypical IgA antibodies to cardiolipin or beta 2-glycoprotein exist.⁵⁻⁹ Current guidelines recommend lifelong anticoagulation with vitamin K antagonists (VKA) like warfarin to prevent thrombosis and thrombotic events. Only ten cases of acute MVT caused by APS are described in literature, all involving SMV and were treated with VKAs.¹⁰⁻¹⁹ In APS, aPL antibodies induce a hypercoagulable state by promoting platelet aggregation and activation, synthesis of proinflammatory cytokines like interleukin-6, tumour necrosis factor alpha, and increased expression of platelet membrane glycoprotein IIB/IIIA by endothelial cells.²⁰ When collaterals are also involved by the thrombotic process, lethal complications like infarction, necrosis, perforation of bowel and sepsis occur. In acute MVT, bowel rest, intravenous fluids, analgesia and anticoagulation are important to prevent thrombus extension and to promote recanalisation.²¹⁻²³ Anticoagulation with parenteral heparin, as a bridge to oral VKAs like warfarin was used for acute MVT caused by APS. LMWH is the preferred parenteral anticoagulant over un-fractionated heparin (UFH).²⁴ Anticoagulation with VKAs can be erratic, so the therapeutic range between international normalised ratio (INR) of 2.0-3.0 is required to prevent recurrent thrombosis. In refractory APS or when there are contraindications to oral anticoagulants, LMWH is used for long term anticoagulation.²⁵

CONCLUSION

With a diagnosis of acute SMV thrombosis, a search for hypercoagulable state is indicated. This will help determine the duration of anticoagulation and prevent recurrent thrombosis. A high level of suspicion is needed to diagnose acute MVT, when the patient presents with vague abdominal pain and hematochezia, because thrombosis of mesenteric vessels is rare and lethal if left undiagnosed. An early detection on acute MVT, diagnosis of APS and initiation of anticoagulation is necessary to prevent progression of thrombosis and complications.

Funding: No funding sources

Conflict of interest: None declared

Ethical approval: Not required

REFERENCES

- Russell CE, Wadhwa RK, Piazza G. Mesenteric venous thrombosis. *Circulation*. 2015;131:1599-603.
- Choudhary AM, Grayer D, Nelson A. Mesenteric venous thrombosis: a diagnosis not to be missed! *J Clin Gastroenterol*. 2000;31:179-82.
- Gómez-Puerta JA, Cervera R. Diagnosis and classification of the antiphospholipid syndrome. *J Autoimmun*. 2014;48:20-5.
- Miyakis S, Lockshin MD, Atsumi T, et al. International consensus statement on an update of the classification criteria for definite antiphospholipid syndrome (APS). *J Thromb Haemost*. 2006;4:295-306.
- Hughes GR, Khamashta MA. Seronegative antiphospholipid syndrome. *Ann Rheum Dis*. 2003;62:1127
- Zohoury N, Bertolaccini ML, Rodriguez-Garcia JL. Closing the serological gap in the antiphospholipid syndrome: the value of "non-criteria" antiphospholipid antibodies. *J Rheumatol*. 2017;44:1597-602.
- Ruiz-García R, Serrano M, Martínez-Flores JÁ et al. Isolated IgA anti-β₂ glycoprotein I antibodies in patients with clinical criteria for antiphospholipid syndrome. *J Immunol Res*. 2014;2014:1-8.
- Tortosa C, Cabrera-Marante O, Serrano M. Incidence of thromboembolic events in asymptomatic carriers of IgA anti β₂ glycoprotein-I antibodies. *PLoS One*. 2017;12:e0178889-18.
- Murthy V, Willis R, Romay-Penabad Z. Value of isolated IgA anti-β₂ glycoprotein I positivity in the diagnosis of the antiphospholipid syndrome. *Arthritis Rheum*. 2013;65:3186-93.
- Higa M, Kojima M, Ohnuma S. Portal and mesenteric vein and inferior vena cava thrombosis associated with antiphospholipid syndrome. *Intern Med*. 2001;40:1245-9.
- Yong Z, Wang L, Chen J. Mesenteric venous thrombosis in a patient with antiphospholipid syndrome and systemic lupus erythematosus. *Asian Biomed*. 2013;7:711-4.
- Donohue K, Minkove S, Weiler B. Catastrophic antiphospholipid antibody syndrome presenting as intraabdominal abscess: an unusual case of thrombotic storm. *Chest*. 2016;150:377A.
- Fried M, Van Ganse W, Van Avermaet S. Mesenteric vein thrombosis triggered by blunt abdominal trauma in a patient with the primary antiphospholipid syndrome. *Eur J Gastroenterol Hepatol*. 2002;14:697-700.
- Martínez Vázquez C, Rivera A, Albo C. Superior mesenteric vein thrombosis and the primary antiphospholipid syndrome. *Rev Clin Esp*. 1993;192:153-3.
- Egwuonwu S. Acute superior mesenteric vein thrombosis in a patient with primary antiphospholipid syndrome: a case report and brief review of the literature. *J Gastrointest Dig Syst*. 2015;05:1-3.
- Wasr WA, Shahrir MSM, Hussein H. Antiphospholipid syndrome presenting as mesenteric vein thrombosis and gangrenous small bowel. *Int Med J Malaysia*. 2011;10:45-8.
- Kato N, Yukioka H, Yoshida G. Superior mesenteric vein thrombosis presented transient false positivity for lupus anticoagulant under heparin treatment. *Eur J Emerg Med*. 2002;9:67-70.
- Lee HJ, Park JW, Chang JC. Mesenteric and portal venous obstruction associated with primary antiphospholipid antibody syndrome. *J Gastroenterol Hepatol*. 1997;12:822-6.
- Vacca A, Garau P, Cauli A. Primary antiphospholipid syndrome with mesenteric venous thrombosis presenting with intestinal infarction: a case description. *Lupus*. 2007;16:455-6.
- Chighizola CB, Ubiali T, Meroni PL. Treatment of thrombotic antiphospholipid syndrome: the rationale of current management: an insight into future approaches. *J Immunol Res*. 2015;2015:1-20.
- Harnik IG, Brandt LJ. Mesenteric venous thrombosis. *Vasc Med*. 2010;15:407-18.
- Singal AK, Kamath PS, Tefferi A. Mesenteric venous thrombosis. *Mayo Clin Proc*. 2013;88:285-94.
- Hmoud B, Singal AK, Kamath PS. Mesenteric venous thrombosis. *J Clin Exp Hepatol*. 2014;4:257-63.
- Bounameaux H. Unfractionated versus low-molecular-weight heparin in the treatment of venous thromboembolism. *Vasc Med* 1998;3:41-6.
- Vargas-Hitos JA, Ateka-Barrutia O, Sangle S. Efficacy and safety of long-term low molecular weight heparin in patients with antiphospholipid syndrome. *Ann Rheum Dis*. 2011;70:1652-4.

Cite this article as: Vignesh NC, Manivannan D, Maniselvi S, Kannan R. Primary antiphospholipid antibody syndrome presenting as acute superior mesenteric vein thrombosis. *Int Surg J* 2021;8:1901-3.