

Case Report

Intraoperative transthoracic ultrasonography in hepatopulmonary hydatid cyst disease: seeing beyond the horizon

Komal Gupta, Ankita Singh, Deepti Singh, Gopal Puri, Pritam Yadav, Kamal Kataria*

Department of Surgical Disciplines, All India Institute of Medical Sciences, New Delhi, India

Received: 27 March 2021

Accepted: 07 May 2021

***Correspondence:**

Dr. Kamal Kataria,

E-mail: drkamalkataria@gmail.com

Copyright: © the author(s), publisher and licensee Medip Academy. This is an open-access article distributed under the terms of the Creative Commons Attribution Non-Commercial License, which permits unrestricted non-commercial use, distribution, and reproduction in any medium, provided the original work is properly cited.

ABSTRACT

Liver is the most common organ involved in hydatid disease. But involvement of multiple organs simultaneously is not unheard of. Here we have presented our experience with one such similar case with involvement of lower lobe of right lung and segment VII of liver. There was spontaneous rupture of the lung hydatid cyst during the hospital stay. A right posterolateral thoracotomy was performed for evacuation of spilled hydatid cyst content from the right pleural cavity. Intraoperative ultrasound (IOUS) was used to locate and drain the hepatic hydatid cyst via the diaphragm. Such single incision surgery for hepatopulmonary hydatid disease is associated with lesser post-operative morbidity and early discharge from the hospital. Use of IOUS can significantly improve the rate of successful localization and drainage of hepatic hydatid cyst in transthoracic approach.

Keywords: Intraoperative ultrasound, IOUS, Hydatid disease, Liver surgery, PAIR, Thoracotomy

INTRODUCTION

Hydatid disease caused by *Echinococcus granulosus* is one of the commonest zoonosis, with humans as accidental intermediate host. It primarily affects liver. However, hepato-pulmonary involvement is well established in 4-25% cases.¹ Currently surgical management is the only treatment available with curative intent. Open approach is preferred in cases of ruptured hydatid cyst. Here we have emphasized the advantage of using intra operative transdiaphragmatic ultrasonography for localization and drainage of hepatic cysts.

CASE REPORT

A 22 years old lady presented with complaint of a single episode of sudden onset severe upper abdominal pain 1 month prior. It was self-resolving. There was no history of lump in the abdomen, jaundice, breathing difficulty. With clinically palpable non tender hepatomegaly, on further evaluation patient was found to have eosinophilia and a unilocular cystic lesion was identified in the liver

on ultrasound. Chest X ray showed an opaque space occupying lesion in the lower lobe of the right lung. On contrast enhanced computed tomography (CECT) of chest and abdomen, a large thin walled unilocular cystic lesion measuring 12×10 cm in right lung lower lobe and another cyst measuring 8×8 cm in segment VII of the liver likely due to hydatid cyst disease were identified (Figure 1). Patient was started on oral albendazole tablets. She was scheduled to undergo drainage/excision of the pericysts by thoracoabdominal approach. However, while awaiting elective surgery, patient had multiple episodes of vomiting and dyspnoea. Chest X ray suggested rupture of the right lung hydatid cyst (Figure 2). There was no airway or hemodynamic compromise. Patient was taken to operation theatre for an emergency right posterolateral thoracotomy. Intraoperatively ruptured hydatid cyst was found with spillage of detached membrane and fluid in the right pleural cavity. Thoracic cavity was packed with surgical pads soaked in scolicidal agent (povidone iodine). Hydatid membrane was evacuated, along with daughter cysts and pleural cavity was lavaged with scolicidal agent. Areas of air leaks into the pericyst

(communicating bronchus) were sealed using sutures. Multiple attempts were made to aspirate the hydatid cyst of liver segment VII transdiaphragmatically via wide bore needle, but they were unsuccessful. Thereafter intraoperatively ultrasonographic localization and needle drainage of hepatic cyst transdiaphragmatically was attempted and accomplished successfully by placing the ultrasound probe through the right posterolateral thoracotomy incision over the diaphragm (Figure 3). Clear fluid was drained, there was no bile. Following this scolicalid agent was injected in the cavity and repeat aspiration was done. Diaphragm was covered with surgical pads soaked in scolicalid agent and phrenotomy (2 cm transverse incision) was done at the site of needle drainage. Pericyst of the liver hydatid was incised (1 cm incision) and hydatid membrane in the hepatic hydatid cyst was evacuated. (Figure 4). Hydatid cavity was again washed thoroughly with the scolicalid agent and the phrenotomy site was closed over a negative suction closed drainage tube in the hepatic cyst cavity. Thoracotomy wound was closed in layers after intercostal drainage tube placement. Patient had an uneventful postoperative period. Postoperatively there was no bile in the subhepatic drain and it was removed on post-operative day 3. She was discharged from the hospital on post-operative day 5 after removal of the intercostal drainage tube.

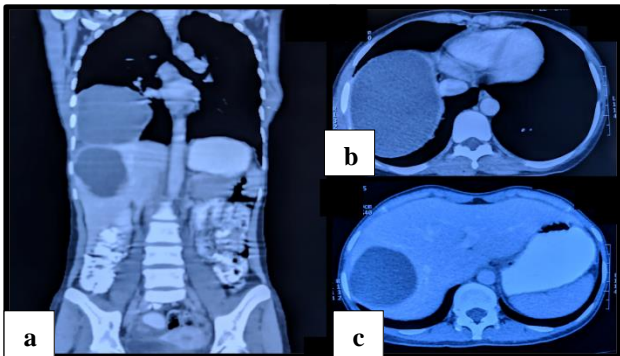


Figure 1: CECT scan (a) coronal section showing hydatid cyst in lung and liver; (b) transverse section showing hydatid cyst in lung; (c) transverse section showing hydatid cyst in liver.

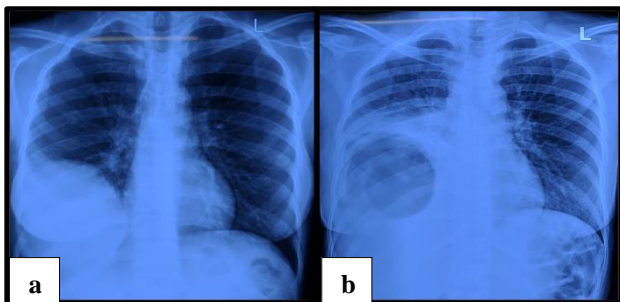


Figure 2: Chest X ray (a) preoperative with space occupying lesion in lower lobe of right lung; (b) air filled cavity in right lung suggestive of rupture of hydatid cyst.

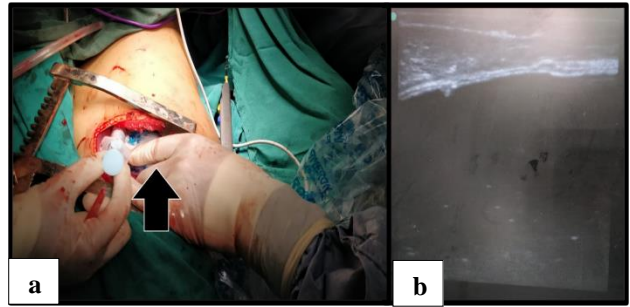


Figure 3: (a) Performing transdiaphragmatic intraoperative ultrasound (arrow represents ultrasound probe covered in sterile plastic cover inserted via Right posterolateral thoracotomy incision); (b) transdiaphragmatic ultrasound showing pericyst with homogenous cystic content underneath.

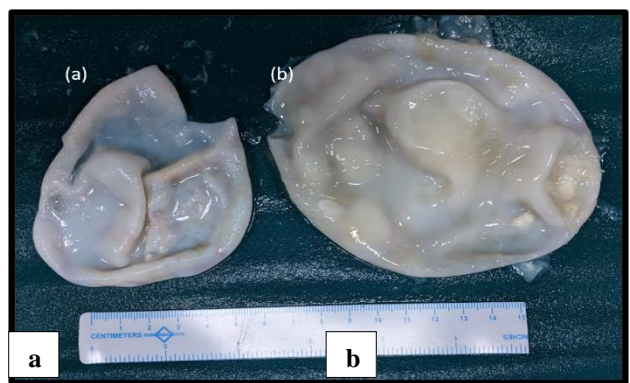


Figure 4: (a) Hydatid membrane of liver cyst; (b) hydatid membrane of lung cyst.

DISCUSSION

Hydatid disease can involve a wide array of organ system and has a varied presentation. Simultaneous involvement of multiple organs is also not unlikely. Hepatopulmonary disease is a common presentation. Surgery for hepatopulmonary hydatid disease by the traditional thoracoabdominal approach is associated with higher morbidity in these patients. Use of transthoracic approach to treat pulmonary and hepatic disease with a single incision has been reported before.² Using intraoperative ultrasonography in transthoracic approach can significantly increase the chances of successful localization of the hepatic cyst in these cases. Hepatic hydatid disease which have large cyst or multiple cysts are known to distort the liver anatomy. Preoperative cross sectional imaging like computed tomography (CT) scan or magnetic resonance imaging (MRI) are often times unable to delineate the exact relation of the cyst with the vital structures like bile duct, hepatic vein, portal vein and inferior vena cava.³ Despite extensive preoperative planning, injury to such structures is not unheard of during the surgery because of distorted anatomy and the progression of the disease during the time gap between the cross sectional imaging and the surgery.⁴ Intraoperative ultrasound is frequently used for hepatic

hydatid cyst to choose the most appropriate area for the incision site of cystectomy. Most superficial part of the cyst, which is away from any biliary radicals and is easily approachable is chosen based on the ultrasound imaging. A carefully chosen site for cystectomy can decrease the chances of post-operative complications like biliary fistulae.⁵ Often the cyst is first aspirated using a wide bore cannula at the proposed site of cystectomy incision, presence of clear fluid without any bile staining indicates unlikely biliary- cyst communication and the site of needle insertion can be used for cystectomy incision safely. Sites of biliary-cyst communication can be localized using the ultrasound and the surgical plan can be adapted accordingly using a more radical surgical resection, as a conservative approach is more frequently associated with postoperative cavity related complications.⁶ Ultrasound can be particularly useful in cases with deep seated hydatid cyst and cyst along the posterior surface of the liver which are tough to approach via routine subcostal or midline abdominal incision. Preoperative use of albendazole has been a subject of controversy. It is favoured, as it decreases the chances of recurrent disease. Though only using albendazole to achieve sterility without further surgery is not preferred as even after 3 months of albendazole therapy viable scoleces have been identified.^{7,8}

Currently most lung hydatid cysts are approached surgically, objective of treatment being preservation of lung parenchyma with removal of all parasitic material. Hence cystostomy are preferred over pericystectomy or lobectomy.⁹ Transthoracic approach for hepatic cyst has been used in cases of hepatopulmonary disease. Like the proven benefit of percutaneous drainage of liver cyst, transthoracic drainage should provide similar benefit.¹⁰ The transthoracic approach can be difficult in certain cases, such as cyst in left lobe of liver, deep seated cysts and cysts located away from the diaphragm, approaching the liver during left posterolateral thoracotomy for left lung hydatid disease is also difficult.

Despite preoperative planning using cross sectional imaging, locating a hepatic cyst can be tough. Transthoracic ultrasound may be useful in case of difficulty in localizing the site of maximum bulge of hepatic cyst through diaphragm. Without proper localization, larger phrenotomy incision are needed in such cases. With the use of intraoperative ultrasound, a smaller incision can be used with less post-operative compromise of pulmonary function.

CONCLUSION

Intraoperative ultrasound (IOUS) is a vital tool for the surgeon. It can help the surgeon operate in regions using minimally invasive approach beyond what eyes can see.

Its intraoperative utility as a localization tool for tumors and other swellings has widened surgeons' reach.

Funding: No funding sources

Conflict of interest: None declared

Ethical approval: Not required

REFERENCES

1. Rami-Porta R, Ais-Conde JG, Bravo-Bravo JL, Alix-Trueba A, Serrano-Muñoz F. Treatment of synchronous pulmonary and hepatic hydatid cysts. *J Thorac Cardiovasc Surg.* 1986;92(2):314-5.
2. Sahin E, Enön S, Cangir AK, Kutlay H, Kavukçu S, Akay H, Okten I, Yavuzer S. Single-stage transthoracic approach for right lung and liver hydatid disease. *J Thorac Cardiovasc Surg.* 2003;126(3):769-73.
3. Kulali F, Acar A, Semiz-Oysu A, Canbak T, Tolan K, Bukte Y. Misleading findings of liver-specific MR contrast agent for radiological diagnosis of cysto-biliary communication in hydatid cysts. *Radiol Med.* 2019;124(6):460-6.
4. Frikha F, Trigui A, Rejab H, Toumi N, Fendri S, Jemal A, Amar MB, Mzali R. Correlation of radiological findings with surgical findings in hepatic hydatid disease. A prospective study of 79 cases. *Ann Ital Chir.* 2018;89:309-14.
5. El-Gendi AM, El-Shafei M, Bedewy E. The Role of Prophylactic Endoscopic Sphincterotomy for Prevention of Postoperative Bile Leak in Hydatid Liver Disease: A Randomized Controlled Study. *J Laparoendosc Adv Surg Tech A.* 2018;28(8):990-6.
6. Yüksel O, Akyürek N, Sahin T, Salman B, Azili C, Bostanci H. Efficacy of radical surgery in preventing early local recurrence and cavity-related complications in hydatid liver disease. *J Gastrointest Surg.* 2008;12(3):483-9.
7. Dziri C, Haouet K, Fingerhut A. Treatment of hydatid cyst of the liver: where is the evidence? *World J Surg.* 2004;28(8):731-6.
8. Bildik N, Cevik A, Altıntaş M, Ekinçi H, Canberk M, Gülmen M. Efficacy of preoperative albendazole use according to months in hydatid cyst of the liver. *J Clin Gastroenterol.* 2007;41(3):312-6.
9. Aldahmashi M, Alassal M, Kasb I, Elrakhawy H. Conservative Surgical Management for Pulmonary Hydatid Cyst: Analysis and Outcome of 148 Cases. *Can Respir J.* 2016;8473070.
10. Khuroo MS, Wani NA, Javid G, Khan BA, Yattoo GN, Shah AH, Jeelani SG. Percutaneous drainage compared with surgery for hepatic hydatid cysts. *N Engl J Med.* 1997;337(13):881-7.

Cite this article as: Gupta K, Singh A, Singh D, Puri G, Yadav P, Kataria K. Intraoperative transthoracic ultrasonography in hepatopulmonary hydatid cyst disease: seeing beyond the horizo. *Int Surg J* 2021;8:1910-2.