

Case Series

Ruptured splenic artery pseudoaneurysm: is surgery always required?

Girish D. Bakhshi¹, Kanishk N. Patil^{1*}, Sachin S. Sholapur¹, Avinash Gutte²,
Chandrakant Sable¹, Owais Patel¹, Parth D. Barfiwala¹

¹Department of General Surgery, ²Department of Radiology, Grant Government Medical College and Sir J. J. Group of Hospitals, Mumbai, Maharashtra, India

Received: 26 March 2021

Accepted: 06 May 2021

*Correspondence:

Dr. Kanishk N. Patil,

E-mail: kanishk.nitin.patil@gmail.com

Copyright: © the author(s), publisher and licensee Medip Academy. This is an open-access article distributed under the terms of the Creative Commons Attribution Non-Commercial License, which permits unrestricted non-commercial use, distribution, and reproduction in any medium, provided the original work is properly cited.

ABSTRACT

Splenic artery aneurysms are extremely rare, and pseudoaneurysms are even rarer. More often than not, the aetiology is acute or chronic pancreatitis, although blunt trauma to abdomen and previous endovascular procedure (iatrogenic) are also known causes. The condition can have a wide spectrum of clinical presentations ranging from incidental finding to severe uncompensated circulatory shock. Splenic artery pseudoaneurysm (SAP) is frequently misdiagnosed as a pseudocyst pancreas with haemorrhage in it, as was the case with one of the present patients. In this case series, we discuss two patients of SAP. A young 33-year-old male patient, known case of pancreatitis, who presented with severe hypotension and ultrasonography (USG) suggestive of hemoperitoneum and pseudocyst pancreas with hematoma. The second patient was a 42-year-old male who presented with acute onset upper abdominal pain, vomiting, abdominal distension and giddiness. Both these patients were resuscitated by giving fluids and blood transfusions. Their diagnosis of SAP was confirmed on computed tomography (CT) of abdomen. Both these patients underwent endovascular coiling of SAP. Present report highlights the role of endovascular intervention in managing a bleeding SAP as long as emergency surgical team are kept on stand-by.

Keywords: Pseudocyst, SAP, Endovascular procedure

INTRODUCTION

Visceral artery pseudoaneurysms are uncommon with splenic artery being most commonly involved, followed by the hepatic and the coeliac arteries.¹ Though acute and chronic pancreatitis cause most of the pseudoaneurysms, iatrogenic injuries, peptic ulcer disease and less commonly, idiopathic reasons also contribute to the etiology. There are very few reported cases of SAP of idiopathic etiology.² Trauma leading to pseudoaneurysm is also noted in literature. Sudden deceleration injuries like road traffic accidents lead to damage of the intima and the elastic lamina of the splenic artery leading to pseudoaneurysm formation.³ SAP are important due to their potentially life-threatening complications and the fact that they are difficult to diagnose on account of their varied presentation. Less than 200 cases have been discussed about in the literature.^{4,5} Now that CT scan is

being used routinely in diagnosis of abdominal pathologies, more and more cases of SAP are being diagnosed. This has prompted studies to find out which line of management is best suited for a patient. SAP with diameter <2 cm has an asymptomatic presentation and those with >5 cm is generally symptomatic and need to be managed definitively.^{1,5,6}

Case 1

A 33 years old male came to the emergency department in a hypotensive state with acute abdomen. Patient had severe abdominal pain for 8 days. Pain was sudden in onset and was radiating to the back and the upper abdomen. He also gave history of intermittent episodes of non-bilious vomiting. He used to consume alcohol frequently. He took treatment from a local hospital and was managed on medications. The treating physician

advised ultrasonography of the abdomen and pelvis in which a pancreatic cyst of dimensions 6.1x6.2x7.1 cm (143 cc) was seen. The patient was then referred to our hospital for further management.

The patient was given immediate resuscitation with intravenous fluids and bedside ultrasonography (USG) was done. USG showed free fluid in abdomen with pancreatic collection. Patient was stabilised by giving blood transfusion and Computed Tomography (CT) scan was done. CT scan was suggestive of atrophic pancreas with multiple calcific foci in the body, head and tail region. The main pancreatic duct was also dilated (5.5 mm). A well-defined heterogeneous collection measuring 6.5x10.2x5.9 cm was seen anterior to the body of pancreas, left kidney and superomedial to the spleen with extension into the subcapsular region which was suggestive of thrombosed part of pseudoaneurysm (Figure 1). Hepatic and splenic arteries were seen directly arising from the abdominal aorta without a coeliac trunk. A pseudocyst of size 3.5x4.1x2.9 cm was also seen inferomedial to the above-mentioned collection. Moderate ascites with area of hyper density in the pelvis was also seen which was suggestive of a hemoperitoneum.

As patient was stable, it was decided in consultation with interventional radiologists to plan for endovascular coiling of the pseudoaneurysm with operation theatre and surgeons as standby. The patient underwent an intervention radiology procedure.

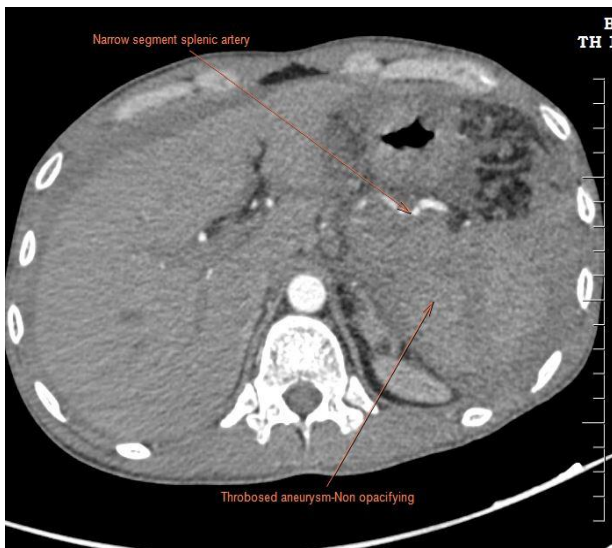


Figure 1: CECT of SPA (thrombosed, non-opacifying on CECT).

A right femoral access was obtained through a 4 Fr sheath. Mid distal part of the suspicious SAP was coiled with CONCERTO PV-20-50-HELIX detachable coils. Post stent assisted coiling angiogram showed near complete extrusion of the aneurysm from the circulation Figure 2 (A and B).

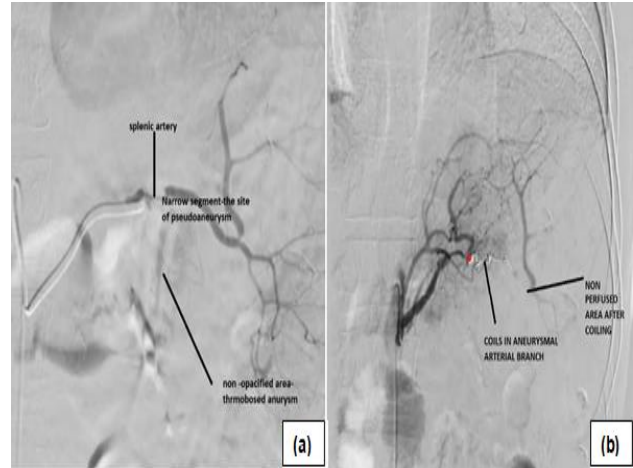


Figure 2: (A and B) Angiography of SPA. Post coiling angiography.

Post procedural period was uneventful the patient was given two more blood transfusions after the procedure and was kept under observation for thirteen days before he was discharged. Two monthly USG in follow up period showed complete resolution of collection after 4 months. Follow up of 6 months has shown him to be disease and symptom free.

Case 2

A 42-year-old male, carpenter by occupation, presented in emergency department with acute onset upper abdominal pain, vomiting, abdominal distension and giddiness for 3 days. Pain was sharp, tolerable, non-radiating, non-referred, moderate in intensity. He had bilious, non-projectile vomiting of 3-4 episodes in a day. He gradually developed abdominal distension in past 3 days and excessive tiredness and giddiness. He consulted a local physician for his complaints and was then diagnosed of severe anemia with hemoglobin of 5.4 gm%. He was then referred to our hospital for further management. Patient had no comorbidities or any similar history in the past. Other than occasional habit of chewing tobacco, no other substance abuse was present. Clinically the patient was pale, tachycardic and had upper abdominal tenderness without obvious guarding.

Patient was stabilized in the emergency department (ED) by giving fluid and blood transfusions. Ultrasound examination of the abdomen and pelvis revealed a large hypoechoic lesion of 9x10x11cm in the epigastric region which was displacing the stomach anteriorly and the pancreas inferiorly with mild free fluid in the abdomen and pelvis. Computed tomography with arterial contrast revealed a large irregular heterogenous lesion of 10.9x13.5x6.5 cm in epigastric region. Contrast blush was seen on arterial phase within the lesion with a ruptured SAP of size 1.2x0.7 cm with hemoperitoneum (Figure 3 (A and B)). Pancreas appeared normal.

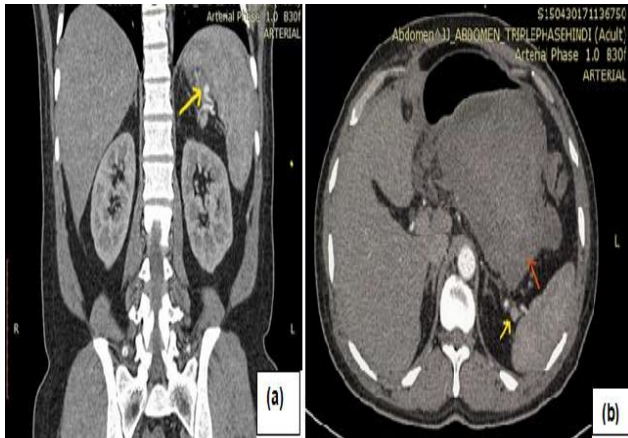


Figure 3: (A and B) CECT Abdomen demonstrating an SAP. Transverse section showing hematoma and pseudoaneurysm displacing the stomach anteriorly.

Blood and serum chemistries were unremarkable except for the features iron deficiency anemia. Serum amylase (41U/l) and lipase (97.2U/l) were not elevated.

Patient was diagnosed with SAP of unknown etiology, as there were no signs of pancreatic inflammation or any previous surgical procedures. Patient was planned for endovascular repair of the SAP after ensuring hemodynamic stability with surgical stand by.

A right femoral access was taken and a splenic angiogram was performed. 30x20mm pseudoaneurysm was identified in the superior branch of the splenic artery.

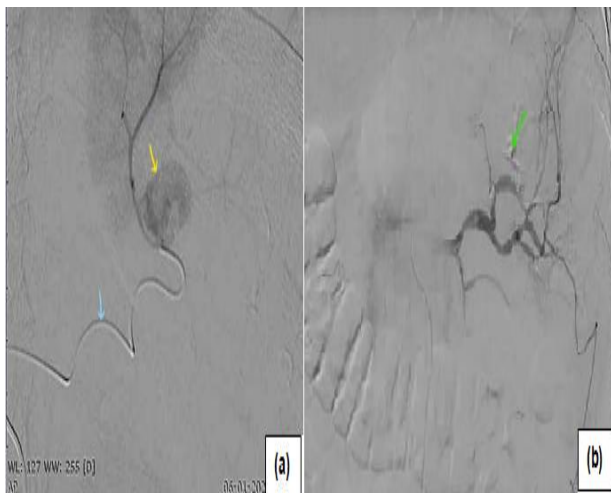

Figure 4: (A and B) Splenic artery angiogram demonstrating a pseudoaneurysm in the superior branch of the splenic artery (yellow arrow) and the microcatheter (blue arrow). Exclusion of the diseased segment in post procedure angiogram.

A microcatheter was passed across the neck of pseudoaneurysm in distal splenic artery and selective embolization of the diseased segment was done with 50% n-butyl-2-cyanoacrylate glue. Exclusion of the diseased

segment was seen in post procedure angiogram (Figure 4 (A and B)). Patient had no complaints on day 2 of the procedure and was discharged in a stable condition. Follow up USG after 4 month showed complete resolution of collection.

DISCUSSION

Arterial aneurysms are a rare occurrence. Pseudoaneurysms being more uncommon than true aneurysms. A study of 3,600 arteriograms found an incidence rate of 0.78%.⁷ True aneurysms are vascular dilatation involving all the 3 layers of the arterial wall: the intima, media, and adventitia. Pseudoaneurysms are dilatations of vessels that do not contain all 3 layers of the artery wall.^{1,8} Pathophysiology of the pseudoaneurysm is the autolysis of the wall of the artery by the digestive enzymes released due to the pancreatic injury caused in pancreatitis.⁹ Loss of the middle layer characterized by disintegration of elastic fibres and loss of smooth muscles leads to necrotizing arteritis, which is the most frequent finding.¹⁰ In present case series one patient had pancreatitis as the etiological factor, however, there was no etiological factor in second case.

Patients suffering with SAP can be asymptomatic, with the pseudoaneurysm being an incidental finding, or in a state of shock, on the opposite end of spectrum, as it was in present case.

The most common symptom in these patients is abdominal pain, occurring in about one third of patients. The complications of SAP are potentially fatal and hence treatment is recommended if these exceed 2 cm in diameter, are increasing in size, are associated with inflammation, are symptomatic or occur in pregnant women or individuals with portal hypertension.^{11,12} A large series from the Mayo Clinic showed that 97.5% of patients with non-ruptured splenic artery aneurysms were asymptomatic. Of all the complications of SAP, haemorrhage is the most severe and when it does occur, it can lead to massive bleeding into any surrounding intra-abdominal organs or spaces, which include the peritoneal cavity, retroperitoneal space, or pancreatic duct (hemorrhage into the pancreas).¹² In present case reports, both patients had ruptured SAP with hemoperitoneum, however, both could be resuscitated with blood transfusion. The reason may be that it was a gradual leak from ruptured SAP and majority of the leak was contained resulting in presentation as pseudocyst. The SAP can also rupture into a pseudocyst that can eventually lead to a formation of an even bigger pseudocyst.⁴ The risk of pseudoaneurysm rupture can be as high as 37%, with the mortality rate after rupture being nearly 90%.

Given the catastrophic nature of the disease, early and prompt diagnosis is of immense importance. Various diagnostic techniques have been used to diagnose SAP like USG, Doppler, CT scan and magnetic resonance

imaging (MRI). CT scan is advantageous in distinguishing SAP from pancreatic tumors, solid epithelial tumors, gastric leiomyomas and pseudocysts, as was seen in present cases. SAP can be wrongly diagnosed as a pseudocyst on USG.⁶ Even with the advent of various imaging techniques, the gold standard for diagnosis remains a direct catheter visceral angiography, which has the advantage of being both diagnostic and therapeutic, but has the disadvantage of not being easily available and this procedure requires the patients to be hemodynamically stable.^{5,13}

Current guidelines for management dictate that every SAP, irrespective of its size, symptoms or rupture, be managed definitively.¹⁴ This is because a pseudoaneurysm generally has a co morbidity present, like pancreatitis, which increases the risk of mortality. Therapeutic management of SPA is either operative or transcatheter procedures. Transcatheter embolization was initially introduced by Probst et al in 1978. These procedures are preferred in patients who are asymptomatic and hemodynamically stable because transcatheter procedures have lesser post procedural mortality rates. There are a few cases in literature that have shown that transcatheter procedures can be performed even in cases when the patient is unstable. A combination of multiple procedures might be necessary for some cases, especially for giant SAAs or patients with comorbid conditions. The most frequent complications of transcatheter embolization are coil migration, aneurysm rupture, intestinal infarct, fever, splenic infarct, and abscess.¹

Operative management is preferable in patients who are unstable, in centres where interventional radiology is unavailable or when there is a diagnostic uncertainty as endoscopic ultrasound and drainage of suspected pancreatic pseudocyst can be catastrophic and are contraindicated when SAP is a possible differential diagnosis. Mortality rate after open surgical intervention of false aneurysms near the head of the pancreas is reported to be around 16% and may reach up to 50% for those near the body and tail.¹⁴ Operative procedures are also performed in cases where a previous endovascular procedure like coiling has failed and the coil has migrated or a previously embolized SAP has recanalized.¹⁵ Minimally invasive laparoscopic excision of splenic artery aneurysm is an alternative to open abdominal surgery. In cases where the SAP is an incidental finding, the patient is asymptomatic and hemodynamically stable, endovascular procedures remain the mainstay. In present report, both the patients were responders to resuscitation and became stable, hence angioembolization was done keeping both surgeons and operation room (OR) as standby in case interventional radiology fails. However, both these patients had uneventful procedure with favourable outcome after angioembolization with resolution of collection after 4 months.

CONCLUSION

SAPs are rare and difficult to diagnose. A high level of suspicion is required while assessing patients of pancreatitis who present with severe anaemia or shock. Patients with ruptured SAP will require initial resuscitation. Operative intervention is associated with high morbidity and mortality. Patients can undergo transcatheter procedures after initial resuscitation with OR and surgical team on standby. Quick diagnosis and a definitive management are of utmost importance in management of this condition which may otherwise have disastrous outcomes. An endovascular procedure may be performed, all the while keeping an OR ready on standby in the event that the patient deteriorates during the procedure or the transcatheter procedure fails.

Funding: No funding sources

Conflict of interest: None declared

Ethical approval: Not required

REFERENCES

1. Akbulut S, Otan E. Management of giant splenic artery aneurysm. *Medicine US*. 2015;94:e1016.
2. Schatz RA, Schabel S, Rockey DC. Idiopathic Splenic Artery Pseudoaneurysm Rupture as an Uncommon Cause of Hemorrhagic Shock. *J Investig Med High Impact Case Rep*. 2015;3(2):2324709615577816.
3. Norotsky MC, Rogers FB, Shackford SR. Delayed presentation of splenic artery pseudoaneurysms following blunt abdominal trauma: case reports. *J Trauma*. 1995;38:444-7.
4. Tessier DJ, Stone WM, Fowl RJ, Abbas MA, Andrews JC, Bower TC et al. Clinical features and management of splenic artery pseudoaneurysm: Case series and cumulative review of literature. *J Vascular Surg*. 2003;38:969-74.
5. Chia C, Pandya GJ, Kamalesh A, Shelat VG. Splenic artery pseudoaneurysm masquerading as a pancreatic cyst-a diagnostic challenge. *Int Surg*. 2015;100:1069-71.
6. Yagmur Y, Akbulut S, Gumus S, Demircan F. Giant splenic artery pseudoaneurysm: A case report and literature review. *Int Surg*. 2015;100:1244-8.
7. Mariúba JVO. Splenic aneurysms: Natural history and treatment techniques. *J Vascular Brasileiro*. 2020;19.
8. Yadav S, Sharma P, Singh PK, Punia S, Desai P, Anjan AK et al. Giant splenic artery aneurysm: A rare but potentially catastrophic surgical challenge. *Int J Surg Case Rep*. 2012;3:533-6.
9. Ronde T de, Beers B, Canniere L, Trigaux JP, Melange M. Thrombosis of splenic artery pseudoaneurysm complicating pancreatitis. 1993;34:1271-3.
10. Goldberg RF, Maley W, Kennedy EP, Yeo CJ, Lavu H. Giant Splenic Artery Pseudoaneurysm. *J Gastrointestinal Surg*. 2011;15:1063-6.

11. Rai P, KC H, Goel A, Aggarwal R, Sharma M. Endoscopic ultrasound-guided coil and glue for treatment of splenic artery pseudo-aneurysm: new kid on the block. *Endoscopy Int Open.* 2018;06:E821-5.
12. Hogendoorn W, Lavidia A, Myriam Hunink MG, Moll FL, Geroulakos G, Muhs BE et al. Open repair, endovascular repair, and conservative management of true splenic artery aneurysms. *J Vascular Surg.* 2014;60:1667-76.
13. Varshney P, Songra B, Mathur S, Gothwal S, Malik P, Rathi M et al. Splenic Artery Pseudoaneurysm Presenting as Massive Hematemesis: A Diagnostic Dilemma. *Case Rep Surg.* 2014;2014:501937.
14. Al-Habbal Y, Christophi C, Muralidharan V. Aneurysms of the splenic artery-A review. *Surgeon.* 2010;8:223-31.
15. Roland J, Brody F, Venbrux A. Endovascular Management of a Splenic Artery Aneurysm. *Surgical Laparoscopy, Endoscopy Percutaneous Tech.* 2007;17:459-61.

Cite this article as: Bakhshi GD, Patil KN, Sholapur SS, Gutte A, Sable C, Patel O, Barfiwala PD. Ruptured splenic artery pseudoaneurysm: is surgery always required? *Int Surg J* 2021;8:1887-91.