

Case Report

A case report of complete pancreatic lipomatosis

Nuvvula Satwik, Sanjay Nagappa Koppad*, Srikar Rao Nadipally

Department of General Surgery, Yeneopya Medical college, Mangalore, Karnataka, India

Received: 19 March 2021

Accepted: 03 May 2021

***Correspondence:**

Dr. Sanjay Nagappa Koppad,

E-mail: sanjaykoppad@gmail.com

Copyright: © the author(s), publisher and licensee Medip Academy. This is an open-access article distributed under the terms of the Creative Commons Attribution Non-Commercial License, which permits unrestricted non-commercial use, distribution, and reproduction in any medium, provided the original work is properly cited.

ABSTRACT

The pancreas is an exocrine and endocrine organ that is related to the stomach, duodenum, colon and spleen. Fatty degeneration of the pancreas is common with aging. The entire pancreas may be replaced by fat and the patient may have no clinical symptoms. We here presented a case of a 28 years old male known case of type 2 diabetes diagnosed 3 months back, who was admitted to our hospital for diffuse abdominal pain for the past 2 months, which was non-colicky in nature associated with nausea, anorexia, diarrhea and generalized weakness, no aggravating or relieving factors. With this scenario, he was investigated further for abdominal pain and found to have pancreatic lipomatosis.

Keywords: Common bile duct, Computed tomography, Carcinoembryonic antigen

INTRODUCTION

The pancreas is an exocrine and endocrine organ approximately 15-20 cm long that is related to the stomach, duodenum, colon and spleen. Fatty degeneration of the pancreas is common with aging. The entire pancreas may be replaced by fat and the patient may have no clinical symptoms. Fatty replacement of exocrine pancreas, also known as fatty infiltration, lipomatosis, adipose atrophy or lipomatous pseudo-hypertrophy is a well-documented benign entity of speculative origin.¹ The exact etiopathogenesis behind fatty replacement is not known, however, several predisposing factors have been suggested. These include obesity, diabetes mellitus, chronic pancreatitis, hereditary pancreatitis, pancreatic duct obstruction by calculus or tumor and cystic fibrosis.²

Fatty replacement may be focal or diffuse. Focal fatty replacement is the most common degenerative lesion of pancreas and has no major clinical significance. Total fat replacement is a rare condition and is associated with pancreatic enzyme deficiency and malabsorption. Following are few subtypes: even pancreatic lipomatosis, uneven pancreatic lipomatosis.

There are four different types of uneven pancreatic lipomatosis. Type 1a (35% of cases) is characterized by replacement of the head with sparing of the uncinate process and peribiliary region; type 1b (36%), by replacement of the head, neck and body with sparing of the uncinate process and peribiliary region; type 2a (12%) by replacement of the head, including the uncinate process and sparing of the peribiliary region and type 2b (18%), by total replacement of the pancreas with sparing of the peribiliary region.³

Progressive B-cell dysfunction in the context of insulin resistance is a hallmark of type 2 diabetes.⁴ Glucose toxicity ensuing from diabetes related hyperglycemia has been regarded as a contributor to B-cell damage.⁵ In contrast, chronic exposure of the pancreatic islets to non-esterified fatty acids (NEFAs) is considered as a potential primary cause of B-cell dysfunction.⁶ In obese individuals increased lipolysis contributes to high levels of circulating NEFAs, whereas liver insulin resistance leads to elevated hepatic output of triglyceride-rich particles.⁷ When NEFA supply exceeds utilization, non-adipose tissues including the pancreatic islets, start accumulating triglycerides, which is aggravated by the simultaneous presence of hyperglycemia.^{6,5,8,9}

Experimental and autopsy data indicate that fatty infiltration of the pancreas may contribute to a decrease in B-cell mass and function.

CASE REPORT

We here present a case of a 28 year old male known case of type 2 diabetes diagnosed 3 months back who was admitted to our hospital for diffuse abdominal pain for the past 2 months, which was non colicky in nature, radiating to back associated with nausea, anorexia and generalized weakness, no aggravating or relieving factors. There is history of significant weight loss, loose stools multiple episodes immediately after having food. History of blurring of vision in left eye since 2 months. History of pulmonary TB 2 years back and treated. General examination revealed sinus bradycardia, normal blood pressure with a normal respiratory rate. Physical examination revealed mild generalized tenderness all over abdomen, respiratory and cardiovascular examination showed no abnormality. There are multiple palpable lymphnodes in the right axillary and B/L inguinal area. Blood sugar level at the time of admission was 230 mg/dl. Hemoglobin A 1c was 16.9%, urinary ketones 1+. Routine blood tests, liver function test, renal function test, arterial blood gases, serum amylase and lipase levels, peripheral smear and fasting lipid profile, CEA were normal. Stool for steatorrhea present, Ca 19-9 elevated 229. Ultrasound of abdomen showed suspected abdominal TB/lymphoma.

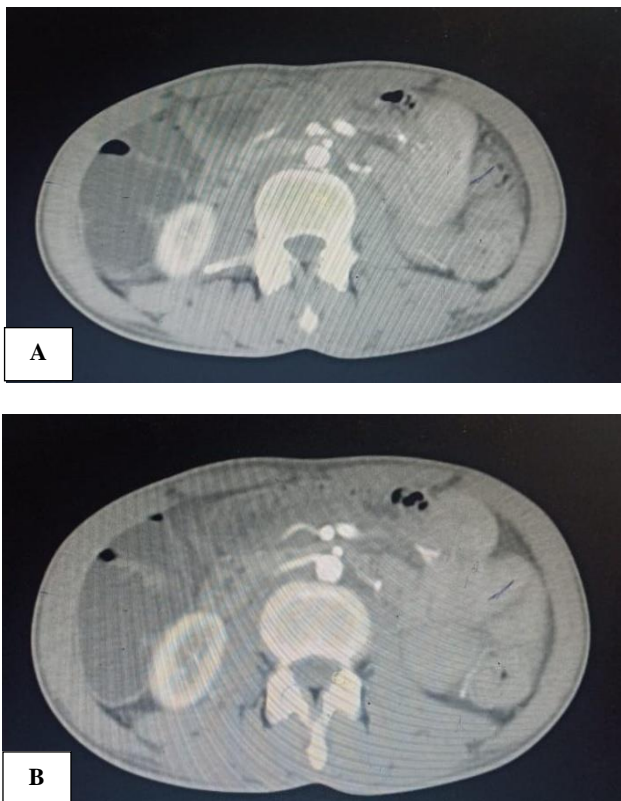


Figure 1 (A and B): CT abdomen showing fatty replacement of pancreas.

Computed tomography (CT) of abdomen revealed complete fatty replacement of pancreas-suggestive of pancreatic lipomatosis. Multiple peripancreatic and periportal lymph nodes present. No intrapancreatic mass, calcification or pancreatic ductal dilatation was seen. Both hepatic ducts, common hepatic duct, cystic duct, their confluence and common ducts were normal. There was no evidence of dilatation of intra/extrahepatic biliary or portal radicals. Patient was taken up for lymph node excision and reported as reactive lymph nodes. On the basis of the above mentioned findings, the diagnosis of diffuse pancreatic lipomatosis was made. Patients were managed with adequate hydration and insulin therapy and other supportive treatments.

DISCUSSION

The accumulation of fat in the pancreatic gland has been referred to using various synonyms such as pancreatic lipomatosis, fatty replacement, fatty infiltration, fatty pancreas, lipomatous pseudohypertrophy, non-alcoholic fatty pancreatic disease and pancreatic steatosis.¹⁰ Pancreatic lipomatosis is becoming an increasing problem worldwide due to the increasing incidence of obesity and diabetes mellitus. Fatty infiltration of the pancreas has been also reported in advanced cases of cystic fibrosis, Shwachman syndrome and Johanson-Blizzard syndrome. Other conditions related to diffuse fatty replacement of pancreas include steroid therapy, Cushing's syndrome, chronic pancreatitis, hemochromatosis and malnutrition.

Fatty replacement may be focal or diffuse. Focal fatty replacement is the most common degenerative lesion of pancreas and has no major clinical significance. Total fat replacement is a rare condition and is associated with pancreatic enzyme deficiency and malabsorption. Fatty replacement may be uniform or unevenly distributed in the pancreas.

Patients are usually asymptomatic with small focal fatty replacement but may present with atypical abdominal pain and/or steatorrhea, mass effect of pancreas on the duodenal loop or malabsorption with severe fatty replacement.^{11,12}

It is common in elderly and obese individuals and very rarely in young ones. Our patient was a young male who presented with pain in abdomen and was diagnosed as pancreatic lipomatosis on CT abdomen. CT of abdomen revealed gross atrophy with near complete fatty replacement of pancreas. No intrapancreatic mass, calcification or pancreatic ductal dilatation was seen. MRCP using 2D FSE and SPGR sequences revealed near complete fatty replacement pancreatic parenchyma, suggests pancreatic lipomatosis. Both hepatic ducts, common hepatic duct, cystic duct, their confluence and common ducts were normal. There was no evidence of dilatation of intra/extrahepatic biliary or portal radicals. Thus, probable cause of type 1 diabetes in our patient was

pancreatic lipomatosis. Considering the age of our patient it is a very rare entity in this age group.

Cross-sectional imaging namely, CT has an important role in the evaluation of pancreatic disease. CT is particularly useful in detecting pancreatic duct obstruction by the calculus or tumor. Fatty infiltration of pancreas is seen on CT evidenced as pancreatic parenchymal soft tissue intermixed with fat. Associated atrophy is also seen in aged individual.

Fat accumulation in the pancreatic islets leads to a decreased insulin secretion and might explain why insulin resistant people cannot encounter the higher demands of insulin and then develop type 2 diabetes mellitus.¹³⁻¹⁷ In addition, a greater proportion of pancreatic fat was associated with increased insulin levels in obese non-diabetic participants. This may indicate that the toxic effect of pancreatic fat accumulation might require a long time before manifesting in impaired B-cell function and it has been assessed that pancreatic B-cell damage is present for more than a decade before diabetes is diagnosed.¹⁸

CONCLUSION

A 28 year old male case of type 2 diabetes found to have total pancreatic lipomatosis. FI is the most common benign condition of the pancreas. The precise etiology remains unknown and may be multifactorial. The diagnosis is classically unambiguously made by ultrasound, CT and MRI in the vast majority of cases. Uneven FI represents the majority of cases. As a consequence, the imaging features may be extremely varied. Ductal and embryologic reasons have been proposed to explain these various patterns. The differential diagnosis concerns include agenesis and lipomatous pseudohypertrophy of the pancreas. One must consider FI of pancreas as one of the diagnosis in a patient presenting with abdominal pain and diarrhea.

Funding: No funding sources

Conflict of interest: None declared

Ethical approval: Not required

REFERENCES

- Patel S, Bellon EM, Haaga J, Park CH. Fat replacement of the exocrine pancreas. *AJR Am J Roentgenol.* 1980;135(4):843-5.
- Soyer P, Spelle L, Pelage JP, Dufresne AC, Rondeau Y, Gouhiri M, et al. Cystic fibrosis in adolescents and adults: Fatty replacement of the pancreas-CT evaluation and functional correlation. *Radiology.* 1999;210(3):611-5.
- Matsumoto S, Mori H, Miyake H, Takaki H, Maeda T, Yamada Y, et al. Uneven fatty replacement of the pancreas: Evaluation with CT. *Radiology.* 1995;194(2):453-8.
- Kahn SE, Hull RL, Utzschneider KM. Mechanisms linking obesity to insulin resistance and type 2 diabetes. *Nature.* 2006;444(7121):840-6.
- Shimabukuro M, Zhou YT, Levi M, Unger RH. Fatty acid-induced beta cell apoptosis: A link between obesity and diabetes. *Proc Natl Acad Sci U S A.* 1998;95(5):2498-502.
- McGarry JD. Banting lecture 2001: Dysregulation of fatty acid metabolism in the etiology of type 2 diabetes. *Diabetes.* 2002;51(1):7-18.
- Prentki M, Nolan CJ. Islet beta cell failure in Type 2 diabetes. *J Clin Invest.* 2006;116(7):1802-12.
- Newsholme P, Keane D, Welters HJ, Morgan NG. Life and death decisions of the pancreatic beta-cell: the role of fatty acids. *Clin Sci.* 2007;112(1):27-42.
- Kharroubi I, Ladrière L, Cardozo AK, Dogusan Z, Cnop M, Eizirik DL. Free fatty acids and cytokines induce pancreatic beta-cell apoptosis by different mechanisms: role of nuclear factor-kappa B and endoplasmic reticulum stress. *Endocrinology.* 2004;145(11):5087-96.
- Smits MM, vanGeenen EJ. The clinical significance of pancreatic steatosis. *Nat Rev Gastroenterol Hepatol.* 2011;8(3):169-77.
- Lin WC, Chen JH, Lin CH, Shen WC. Rapidly progressive pancreatic lipomatosis in a young adult patient with transfusion-dependent myelodysplastic syndrome. *J Formos Med Assoc.* 2007;106(8):676-9.
- Kim KH, Kim CD, Ryu HS, Hyun JH, Chung JP, Chung JB, et al. Endoscopic retrograde pancreatographic findings of pancreatic lipomatosis. *J Korean Med Sci.* 1999;14(5):578-81.
- Ritz-Laser B, Meda P, Constant I, Klages N, Charollais A, Morales A, et al. Glucose-induced preproinsulin gene expression is inhibited by the free fatty acid palmitate. *Endocrinology.* 1999;140(9):4005-14.
- Lameloise N, Muzzin P, Prentki M, Assimacopoulos-Jeannet F. Uncoupling protein 2: a possible link between fatty acid excess and impaired glucose-induced insulin secretion? *Diabetes.* 2001;50(4):803-9.
- Bränström R, Leibiger IB, Leibiger B, Corkey BE, Berggren PO, Larsson O. Long chain coenzyme A esters activate the pore-forming subunit (Kir6. 2) of the ATP-regulated potassium channel. *J Biol Chem.* 1998;273(47):31395-400.
- Liang Y, Buettger C, Berner DK, Matschinsky FM. Chronic effect of fatty acids on insulin release is not through the alteration of glucose metabolism in a pancreatic beta-cell line (beta HC9). *Diabetologia.* 1997;40(9):1018-27.
- El-Assaad W, Buteau J, Peyot ML, Nolan C, Roduit R, Hardy S, et al. Saturated fatty acids synergize with elevated glucose to cause pancreatic beta-cell death. *Endocrinology.* 2003;144(9):4154-63.

18. Maedler K, Oberholzer J, Bucher P, Spinas GA, Donath MY. Monounsaturated fatty acids prevent the deleterious effects of palmitate and high glucose on human pancreatic beta-cell turnover and function. *Diabetes.* 2003;52(3):726-33.

Cite this article as: Satwik N, Koppad SN, Nadipally SR. A case report of complete pancreatic lipomatosis. *Int Surg J* 2021;8:1921-4.