

## Case Report

# Trans-duodenal migration of pancreatic duct stent into liver

Girish D. Bakhshi, Samprathi D.\*, Akshat Mishra, Mahesh Chanap

Department of General Surgery, Grant Government Medical College and JJ Group of Hospitals, Mumbai, Maharashtra, India

**Received:** 03 March 2021

**Revised:** 13 April 2021

**Accepted:** 14 April 2021

**\*Correspondence:**

Dr. Samprathi D.,

E-mail: samprathi4u@gmail.com

**Copyright:** © the author(s), publisher and licensee Medip Academy. This is an open-access article distributed under the terms of the Creative Commons Attribution Non-Commercial License, which permits unrestricted non-commercial use, distribution, and reproduction in any medium, provided the original work is properly cited.

### ABSTRACT

Endoscopic retrograde Cholangio-pancreatography (ERCP) is the one of the modalities for treating symptomatic pancreatic duct obstruction with dilation. A plastic stent placement is the standard technique followed. Complications after a plastic stent placement commonly found in the biliary tract in the form of migration into the duodenum with or without perforation have been widely described. Although complications of pancreatic duct stents are relatively rare, duodenal perforation secondary to pancreatic plastic stent migration into liver has not been described. Duodenal perforation results in perforative peritonitis when the intestinal contents leak into peritoneal cavity. However, stent migration resulting in duodenal perforation is a slow process where the inflammation results in adherence of surrounding organs, thereby preventing leak of intestinal contents into free peritoneal cavity. We present a case of contained duodenal perforation due to migration of pancreatic stent into liver. It is important to note that the chronic inflammatory process around the migrated pancreatic duct stent led to the asymptomatic nature patient in present case.

**Keywords:** Pancreas, Stent, Migration, Duodenum, Liver

### INTRODUCTION

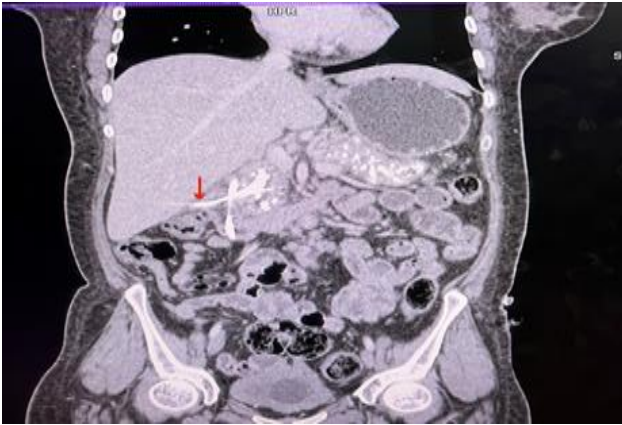
Pancreatic duct stenting is a widely used mode of treatment for chronic calcific pancreatitis, pancreatic pseudocyst with pancreatic duct communication into the pseudocyst.<sup>1</sup> Endoscopic ultrasound (EUS) is a newly emerging technique for pancreatic ducts measuring less than 3-4 mm where surgical treatment is not feasible.<sup>2</sup> Pancreatic duct stent usually migrates either into the pseudocyst proximally or into the duodenum distally.<sup>3</sup> However, pancreatic stent causing perforation of duodenum and migrating into liver has not been described in literature. We present a case of 44 years old female whose pancreatic stent underwent trans duodenal migration into liver.

### CASE REPORT

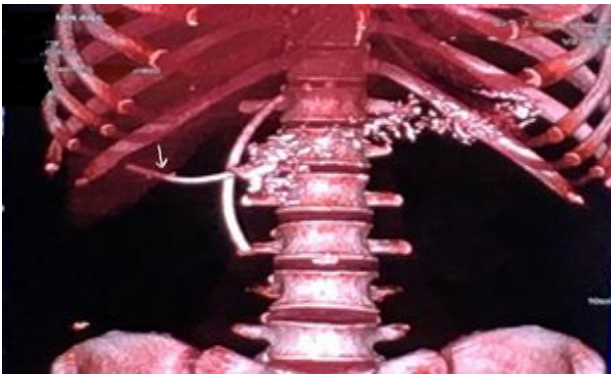
A 44-year-old female presented with dull aching pain in the upper abdomen, radiating to the back. She was

diagnosed with chronic calcific pancreatitis 3 months back in a private hospital for which she had undergone endoscopic retrograde cholangiopancreatography (ERCP) guided pancreatic duct stent placement along with common bile duct (CBD) stenting. Her present clinical examination was unremarkable. Abdominal computed tomography (CT) revealed the displaced pancreatic duct stent with its one end in pancreatic duct and other end passing through the wall of the second part of duodenum opposite ampulla into segment VI of liver resulting in contained duodenal perforation. There was no free fluid in the surrounding area or in peritoneum as shown in the Figure 1 and 2.

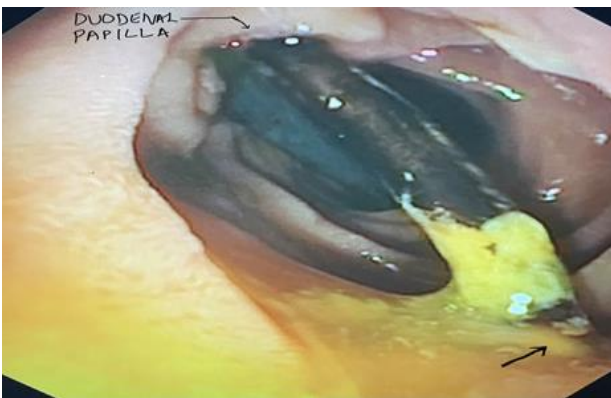Her upper gastrointestinal (GI) endoscopy revealed gastritis with trans duodenal migration of pancreatic stent across the lumen of duodenum and piercing the wall opposite ampulla of Vater. Her biliary stent was normally placed and the free end could be seen in the duodenal lumen (Figure 3).



**Figure 1: coronal CT of trans-duodenal migration of the pancreatic stent with its tip in the segment VI of liver.**



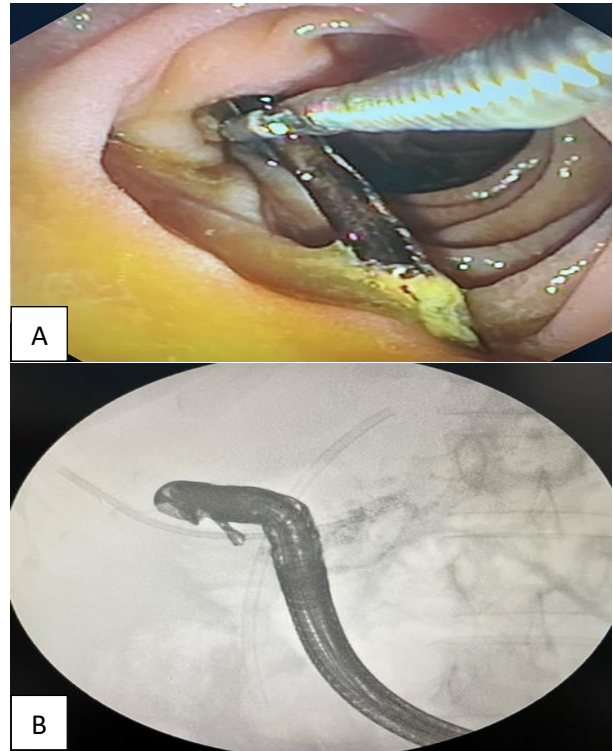
**Figure 2: 3D reconstruction of CT of migrated pancreatic duct stent into liver.**



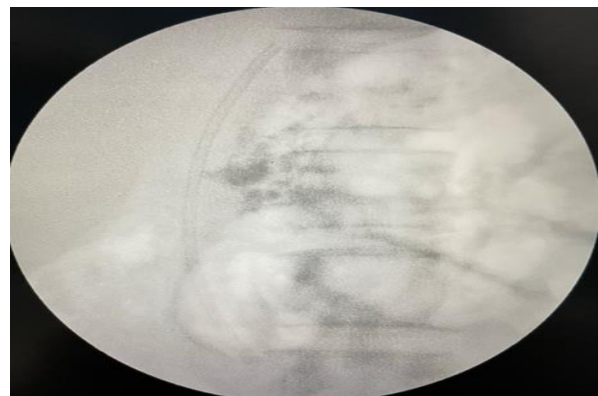**Figure 3: Endoscopic of the pancreatic stent piercing the duodenal wall (black arrow).**

As this perforation was sealed with liver buttressing the perforation site with no free or localized collection in peritoneal cavity and patient being asymptomatic, ERCP with removal of stent was planned. The plastic stent was successfully retrieved from the duodenal wall and removed using rat-tooth forceps (Figure 4). Another stent was placed in the pancreatic duct. Post procedure there was no free peritoneal air (Figure 5) and patient had uneventful recovery. She was discharged on day 4 post-

procedure on pancreatic enzyme supplements. Follow up of 2 months has shown her to be disease and symptom free.



**Figure 4: (A and B) Migrated pancreatic duct stent retrieved using rat-toothed forceps endoscopically.**



**Figure 5: Post procedure endoscopic imaging of no evidence of free air in the abdomen confirming containment of the perforation.**

## DISCUSSION

ERCP-related perforations are relatively uncommon (incidence of 0.14%-1.6%), though associated with a high mortality rate of 4.2%-29.6%, the cause being consequential peritonitis leading to hemodynamic instability. The present patient did not show any such symptoms or signs of perforative peritonitis. Her condition was diagnosed incidentally.

Though there are ample number of clinical classifications of ERCP-related perforations such as the Stapfer classification (2000), Howard classification (1999) and Kim classification (2011), none of the above cover all types of ERCP-related perforations, like the one mentioned in this case report.<sup>8-</sup>

There are two documented cases of pancreatic duct stent migrations, one of which involved detection of stent in the right iliac fossa and the other in peri ampullary duodenal part where the mainstay of treatment was abdominal exploratory surgery.<sup>9,10</sup> The present case is the first instance where the stent has migrated into liver without any symptoms needing a different and more meticulous approach given the close anatomical association of transverse colon to second part of duodenum and liver containing the displaced stent.

Due to chronicity of the stent migration, the surrounding inflammation and fibrosis around the second part of duodenum and the liver led to containment of the perforation, hence accounting for the asymptomatic and stable presentation of the patient. In such a condition, instead of intervening either via an open or a laparoscopic approach, which could have life-threatening complications, an endoscopic procedure was used to retrieve the stent and hence have an uneventful intra and post procedure period.

## CONCLUSION

Pancreatic stent migration may result in duodenal perforation. However, as this migration is slow and gradual process, the surrounding inflammation allows the surrounding organs to buttress this perforation. This results in concealed perforation, which can be managed endoscopically without any surgical intervention.

*Funding: No funding sources*

*Conflict of interest: None declared*

*Ethical approval: Not required*

## REFERENCES

1. Testoni PA. Endoscopic pancreatic duct stent placement for inflammatory pancreatic diseases. *World J Gastroenterol.* 2007;13(45):5971-8.
2. Chapman CG, Waxman I, Siddiqui UD. Endoscopic Ultrasound (EUS)-Guided Pancreatic Duct Drainage: The Basics of When and How to Perform EUS-Guided Pancreatic Duct Interventions. *Clin Endosc.* 2016;49(2):161-7.
3. Cohen SA, Siegel JH, Kasmin FE. Complications of diagnostic and therapeutic ERCP. *Abdom Imaging.* 1996;21(5):385-94.
4. Alfieri S, Rosa F, Cina C, Tortorelli A, Tringali A, Perri V et al. Management of duodeno-pancreato-biliary perforations after ERCP: outcomes from an Italian tertiary referral center. *Surg Endosc.* 2013;27:2005-12.
5. Miller R, Zbar A, Klein Y, Buyeviz V, Melzer E, Mosenkis BN et al. Perforations following endoscopic retrograde cholangiopancreatography: a single institution experience and surgical recommendations. *Am J Surg.* 2013;206:180-6.
6. Stapfer MV, Selbi RR, Stein SC, Katkhouda N, Parekh D, Jabbour N et al. Management of duodenal perforation after endoscopic retrograde cholangiopancreatography. *Gastroenterology.* 1998;114:A1428.
7. Howard TJ, Tan T, Lehman GA, Sherman S, Madura JA, Fogel E et al. Classification and management of perforations complicating endoscopic sphincterotomy. *Surgery (St Louis).* 1999;126:658-65.
8. Kim BS, Kim IG, Ryu BY, Kim JH, Yoo KS, Baik GH et al. Management of endoscopic retrograde cholangiopancreatography-related perforations. *J Korean Surg Soc.* 2011;81:195-204.
9. Mari G, Costanzi A, Monzio N, Miranda A, Rossi M, Rigamonti L et al. Small bowel perforation caused by pancreaticojejunal anastomotic stent migration after pancreaticoduodenectomy for periampullary carcinoma. *JOP.* 2015;16:185-8.
10. Nishiwaki M, Mizuno C, Yano K, Oya H, Amano I, Matsumoto J et al. Retroperitoneal perforation caused by migration of a Pancreatic Spontaneous Dislodgement Stent into periampullary diverticula. *Intern Med.* 2018;57:351-5.

**Cite this article as:** Bakhshi GD, Samprathi D, Mishra A, Chanap M. Trans-duodenal migration of pancreatic duct stent into liver. *Int Surg J* 2021;8:1640-2.