

## Case Report

# Laparoscopic resection of small bowel gist: a case report

Satkunan Mark\*, Lai Weng Wai, Navien Supramaniam, Yan Yang Wai

Department of Surgery, Hospital Raja Permaisuri Bainun, Ipoh, Malaysia

**Received:** 22 February 2021

**Accepted:** 03 April 2021

**\*Correspondence:**

Dr. Satkunan Mark,

E-mail: [satkunanmark@gmail.com](mailto:satkunanmark@gmail.com)

**Copyright:** © the author(s), publisher and licensee Medip Academy. This is an open-access article distributed under the terms of the Creative Commons Attribution Non-Commercial License, which permits unrestricted non-commercial use, distribution, and reproduction in any medium, provided the original work is properly cited.

### ABSTRACT

Small bowel bleed accounts for approximately 5% of all gastrointestinal bleeding. While arteriovenous malformation is the commonest cause of small bowel bleeding, other causes include inflammatory bowel disease, small bowel tumours, ulcers and polyps make up the rest. Tumours range from benign adenomas, hamartomas and leiomyomas to malignant GISTs, adenocarcinomas or lymphomas. We reported a case of a jejunal GIST causing intermittent bleeding. Upper and lower GI endoscopy did not find any abnormality and the diagnosis was made through computerized tomography. It showed a mid-jejunal tumour that was in close proximity to the distal duodenum. The rest of the hollow and solid organs were normal. The patient was prepared and underwent laparoscopic assessment. The tumour was mobile, arising from proximal jejunum and did not show infiltration or adhesions to nearby viscera. A segmental resection with adequate margin was performed laparoscopically and extracted through the umbilical port wound. The pathology report revealed an intermediate GIST with clear margins. Laparoscopic assessment should ideally be carried prior to any resection of small bowel tumours. Uncomplicated small bowel resections can safely be done laparoscopically with good oncological outcome and faster patient recovery.

**Keywords:** Small bowel GIST, Laparoscopic small bowel resection, Small bowel tumour

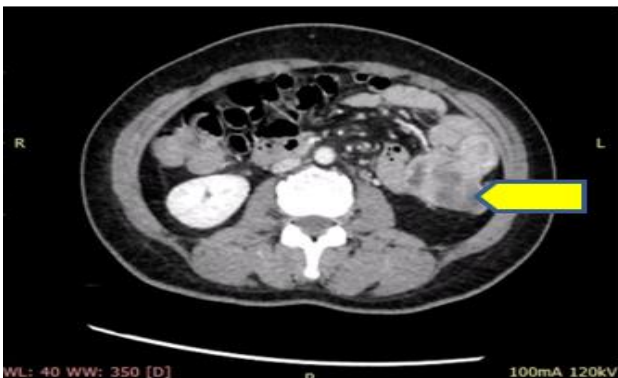### INTRODUCTION

Small bowel bleed accounts for up to 5% of all gastrointestinal bleeds.<sup>1</sup> Arteriovenous malformations make up the majority. Other causes of small bowel bleed include inflammatory bowel disease, ulcers, polyps and tumors. Benign tumors include adenomas and hamartomas while malignant tumors may be adenocarcinomas, lymphomas or gastrointestinal stromal tumors (GISTs).<sup>2</sup> Diagnosis is often delayed and usually made following CT scan. Surgical resection is the mainstay of treatment and a minimally invasive approach is advantageous in many aspects. We hereby present a case of an intermittent bleeding small bowel tumor that underwent laparoscopic resection with good clinical and oncological outcome.

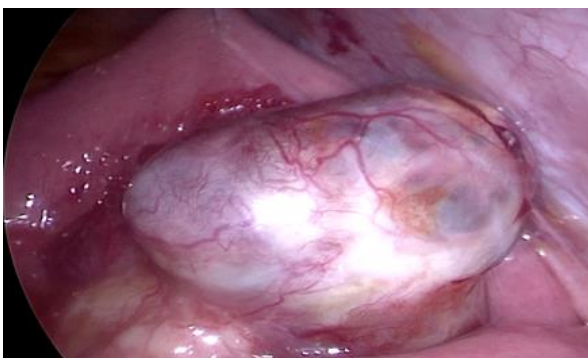### CASE REPORT

A 40 year old lady with recurrent admissions for occult gastrointestinal (GI) bleeding was referred to our center. She presented with recurrent admissions for anemia and melena. Upper and lower GI endoscopy could not isolate the source of bleeding. A CT scan of the abdomen was then done and found a mid-jejunal tumor close to the duodenojejunal (DJ) flexure (Figure 1). A CT mesenteric angiogram that followed did not show active tumor bleeding. She was then prepared for surgery. A laparoscopic assessment preceded definitive surgical treatment. She was placed in supine position with both her arms tucked on both sides. The laparoscopic tower was positioned at the patient's left shoulder. The surgeon on the patient's right, first assistant next to the surgeon and the second assistant on the patient's left. An optical

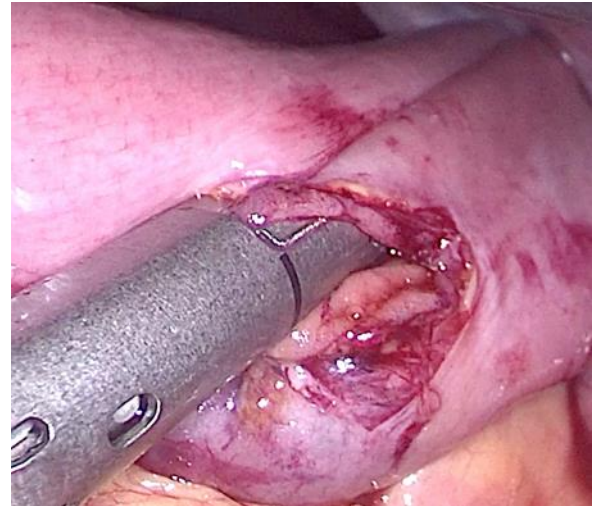
12 mm port was stationed subumbilically, a working 5 mm port placed in the right midclavicular (MCL) line at the level of the umbilicus and the second 5 mm working port at the McBurney's point. A third 5 mm port was placed in the left MCL at level of the umbilicus. The tumor was found in the left upper quadrant approximately 50 cm from the DJ flexure. It was a freely mobile exophytic tumor arising from the antimesenteric border of the jejunum and measured approximately 4cm×6cm (Figure 2). The entire length of the small and large bowel was inspected before proceeding to resection. A stitch was placed on the bowel and was used to hold the bowel in place during resection. A segmental resection with adequate margin was then carried out. The mesentery was excised using ultrasonic shears and the feeding jejunal vessels were ligated and divided. The affected small bowel was resected and a side-to-side anastomosis done using with linear stapler (Figure 3). The enterotomy as well the mesenteric window was closed using intracorporeal suturing (Figure 4). The resected segment of the small bowel was extracted via umbilical port site following 5 cm extension of the wound (Figure 5). The wounds were closed using standard closure technique. She was allowed oral feeds by second day after surgery and was discharged on fourth post-operative day. She was reviewed in the clinic 2 weeks later, the wounds healed well (Figure 6) and pathology review of the specimen showed an intermediate jejunal GIST with margin of 3 cm on either side.



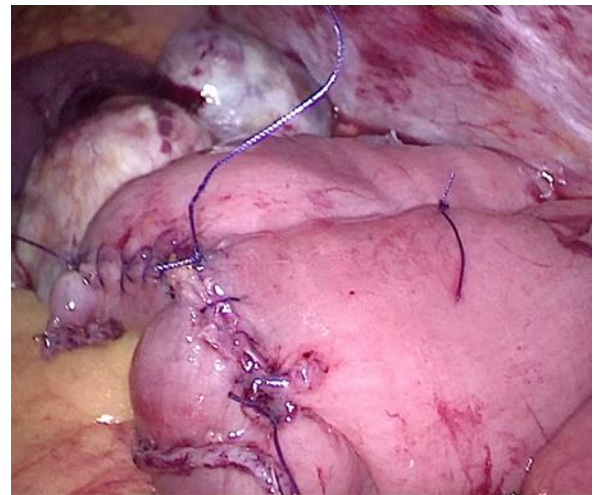
**Figure 1: Mid jejunal tumor (yellow arrow).**



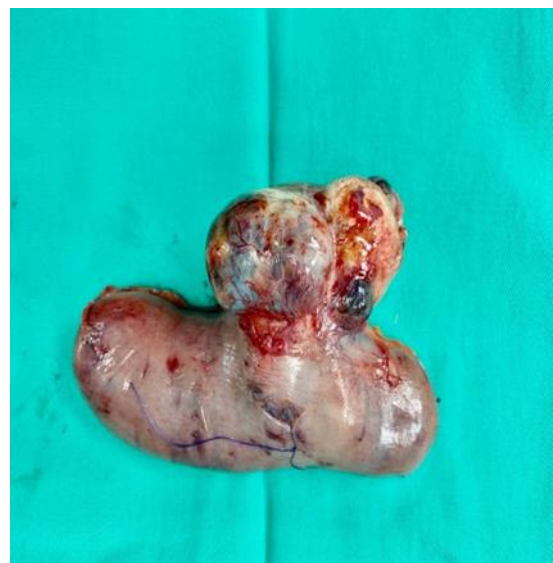**Figure 2: Exophytic jejunal tumor with marionette stitch in place.**



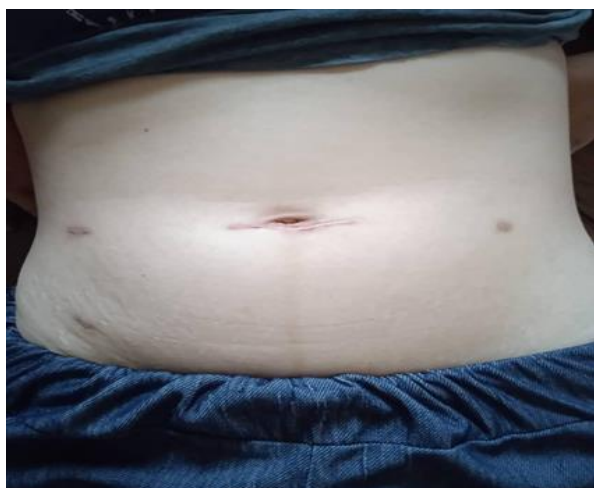**Figure 3: Stapled side to side anastomosis being performed.**



**Figure 4: Closure of enterotomy.**



**Figure 5: Resected specimen.**



**Figure 6: Post-operative review of wounds.**

## DISCUSSION

GISTs can occur anywhere along the entire GI tract. The commonest site of occurrence is the stomach followed by the small bowel and less commonly esophagus and large bowel.<sup>3</sup> Complications of GISTs include GI bleeding, obstruction, intraperitoneal bleeding and perforation.

The use of laparoscopy for small bowel tumor resection is less frequently performed in comparison to gastric and colonic resection. There are several possible factors that are responsible for this. Firstly, the small bowel is mobile making it challenging for dissection. Secondly interloop adhesion or local infiltration of tumors are less predictable thus increase the complexity of the surgery. Finally, resecting and restoring continuity of the bowel laparoscopically requires some degree of skill, patience and judgment.<sup>4</sup> The use of laparoscopic assessment is beneficial especially in small bowel lesions as it allows planning subsequent incision if there is a need for conversion to an open surgery.<sup>5</sup> Since major part of mobilization and dissection can be done laparoscopically, the incision that is to be made would be one that is smaller in contrast to open surgery.<sup>5</sup>

To ease dissection and resection of the tumor segment, we adopted the Marionette technique by placing a suture on the bowel and was held in place by the assistant. The upward retraction facilitated the view of the bowel along with its mesentery right down to its root. This is important to adequately ascertain the margin of the resection, jejunal vessel isolation or more importantly to prevent tumor rupture during handling. A margin of 1-2 cm is adequate.<sup>6</sup> The advantage of performing laparoscopic resection for small bowel tumor lies in its length. In an uncomplicated small bowel tumor adequate margin can be obtained easily.

Once bowel segment devascularization is complete, several options can be adopted for resection and anastomosis. The entire segment can be delivered out

through a separate incision or through the optical port wound. Extracorporeal resection and anastomosis may then be carried out. Alternatively, resection and anastomosis can be performed intracorporeally. It can be done in an isoperistaltic or side to side manner.<sup>7</sup> In our case, the bowel segment was excised using a laparoscopic linear stapler. Once resection was complete the cut ends were aligned in a side to side manner and a suture was placed close to the cut edges to keep the bowel loops in place. Two enterotomies made adjacent to each other and a third and final linear stapler completes the anastomosis. The enterotomy and the mesenteric defect was closed with absorbable suture with ease.

The final challenge lies in extracting the tumor. We extended the optical port wound to approximately 5 cm length and the bowel segment was removed. Care and caution should be exercised so as to prevent tumor rupture or dissemination.<sup>8</sup> Several options for prevention include retrieving the specimen in a laparo-endoscopic bag or the use of a wound protector to protect the wound.<sup>9</sup>

## CONCLUSION

Laparoscopic assessment prior to any small bowel resection should be carried out before any definitive surgical procedure. In the absence of local infiltration, adhesions or peritoneal disease, a curative R0 resection can be achieved. Laparoscopic resection is safe, provides adequate oncological margins, early return of bowel activity as well as shorter hospital stay. We recommend laparoscopic modality be used as the primary mode of surgery based on favorability of the tumor size and location as well as the confidence and experience level of the surgeon.

*Funding: No funding sources*

*Conflict of interest: None declared*

*Ethical approval: Not required*

## REFERENCES

1. Murphy B, Winter DC, Kavanagh DO. Small bowel gastrointestinal bleeding diagnosis and management- a narrative review. *Front. Surg.* 2019;6:25.
2. Riveros CS, Mindiola AL, Fernandez HM, Regino WO. Small bowel bleeding: approach and treatment. *Rev Colomb Gastroenterol.* 2017;32(3).
3. Farhan K, Mushtaq DK, Rabindra C, Priyam Y. A case report on gastrointestinal stromal tumor (GISTs). *Int J Sci Invent.* 2018;7(4):823-9.
4. Xuewei W, Peng W, Hao S, Jianwei L, Haitao Z, Zhizngi Z. Laparoscopic resection of intestinal stromal tumors with transrectal extract specimen a case report. *Medicine.* 2019;98(29):16377.
5. Stewart D, Hughes M, Hope WW. Laparoscopic-assisted small bowel resection for treatment of adult

- small bowel intussusception: a case report. *Cases J.* 2008;432(11).
6. Rutkowski P, Skoczylas J, Wisniewski P. Is the surgical margin in gastrointestinal stromal tumors different? *Visc Med.* 2018;34:347-52.
  7. Kim JJ, Lim JY, Nguyen SQ. Laparoscopic resection of gastrointestinal stromal tumors: Does laparoscopic surgery provide an adequate oncologic resection? *World J Gastrointest Endosc.* 2017;9(9):448-55.
  8. Lee S, Kwon J, Lee J. Laparoscopic treatment of gastrointestinal stromal tumors located at the duodenojejunal junction. *SAGE Open Medi Case Rep.* 2020;8:1-4.
  9. Iulian S, Lucian A, Adrian T, Dana SL, Cornelia N. Laparoscopic resection of gastric GISTs. Where do we stand now? A single-centered experience. *J Mind Med Sci.* 2019;6(2):21.

**Cite this article as:** Mark S, Wai LW, Supramaniam N, Wai YY. Laparoscopic resection of small bowel gist: a case report. *Int Surg J* 2021;8:1579-82.