

Case Report

Management strategies for giant abdominal pseudocyst in a patient with ventriculoperitoneal shunt

Prateek Madaan¹, Inayat Grewal¹, Vipin K. Gupta^{2*}, Anshul Kulshreshtha², Soumya Gupta¹

¹Government Medical College and Hospital, Chandigarh, India

²Department of Neurosurgery, Government Medical College and Hospital, Chandigarh, India

Received: 19 February 2021

Accepted: 16 March 2021

*Correspondence:

Dr. Vipin K. Gupta,

E-mail: vipinkgupta77@gmail.com

Copyright: © the author(s), publisher and licensee Medip Academy. This is an open-access article distributed under the terms of the Creative Commons Attribution Non-Commercial License, which permits unrestricted non-commercial use, distribution, and reproduction in any medium, provided the original work is properly cited.

ABSTRACT

Ventriculoperitoneal (VP) shunt is considered as the mainstay treatment of hydrocephalus, it remains as one of the most failure prone surgical interventions worldwide. Abdominal pseudocyst (APC) is one of the rare complications of VP shunt and is more prevalent in paediatric population. In this case, the patient is an 11-year-old male with history of tubercular meningitis with hydrocephalus for which VP shunt was done and the patient developed a giant abdominal pseudocyst which is the 3rd largest pseudocyst reported till date in a paediatric patient known best to our knowledge. This case is particularly unique due to rapid development of such a large pseudocyst in a span as short as 6 weeks. In this article, the causes of formation of APC and the treatment protocol to manage the patient with abdominal pseudocyst secondary to VP shunt are also discussed.

Keywords: Hydrocephalus, Abdominal pseudocyst, Tubercular meningitis, Ventriculopleural shunt

INTRODUCTION

Tubercular meningitis is one of the common extra pulmonary tuberculosis manifestations. Hydrocephalus is one of the main complications of tubercular meningitis with common occurrence among patients who have the disease for 4 to 6 weeks.¹ The VP shunt is the cornerstone for treating hydrocephalus with tubercular meningitis although, ventriculoatrial and ventriculopleural shunts can also be done. An APC is one of the rare complications of the VP shunt, with an occurrence rate of 1-4.5%.² Here we discuss our case involving development of a giant pseudocyst in a short period of time which is particularly rare. We also discuss the reasons for development of pseudocyst and management algorithm to treat such a complication.

CASE REPORT

An 11 year old male child presented to the outpatient department with history of pain in abdomen, abdominal

distention, loose stools and vomiting 6 weeks after he underwent VP shunt for tubercular meningitis with hydrocephalus due to rifampicin resistant *Mycobacterium tuberculosis*. The patient was already taking multidrug-resistant antitubercular therapy for 2 months. He was not having any fever or headache. Blood markers for infection such as TLC, CRP and procalcitonin were done and were found to be within normal limits. Patient was evaluated by USG abdomen; NCCT head and later on CT abdomen was done (Figure 1).

Ultrasonography abdomen showed large cystic collection occupying whole of the abdominal cavity. CECT abdomen scan showed large cyst in abdominal cavity with shunt tubing inside it and gut loops were pushed towards postero-superior side of abdominal cavity and on contrast there was no enhancement of the cyst wall and no septations inside it. Cyst size was approximately 9.3 cm (anteroposterior length) x 18.4 cm (width) x 25.3 cm (height) and was approximately 2500 ml in volume.

Blood investigations including LFT were normal. NCCT head showed ventricular end of the shunt well in place. There was no hydrocephalus. So, the diagnosis of APC due to VP shunt was made.

The patient was operated and a catheter was placed to drain the cyst and about 2500 ml of clear fluid was

drained. Abdominal end of the shunt was removed and placed inside the pleural cavity. The drain was kept for 4 days and was removed after getting USG abdomen which confirmed no residual collection in the cyst. The patient was asymptomatic on serial follow-ups till a year.

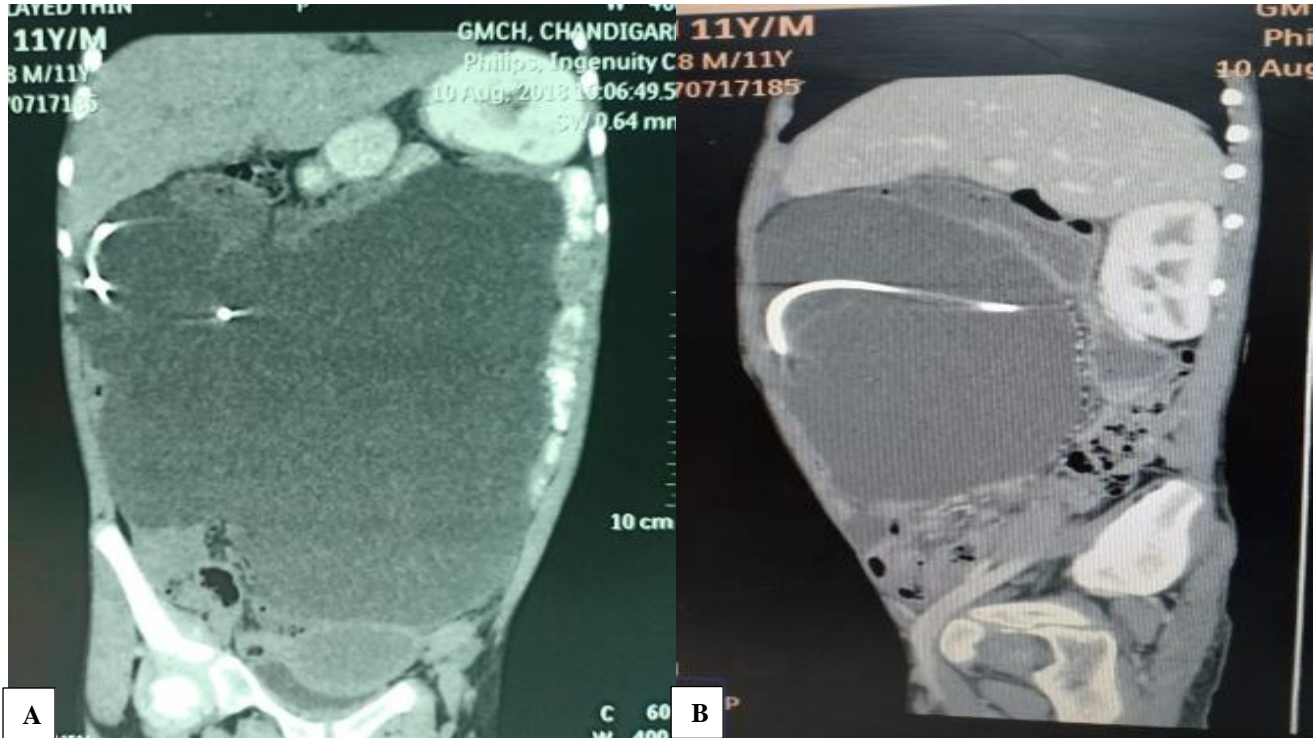

Figure 1: Computed tomography of abdomen showing giant pseudocyst occupying whole of abdomen with gut loops pushed superolaterally; (A) coronal section, (B) sagittal section.

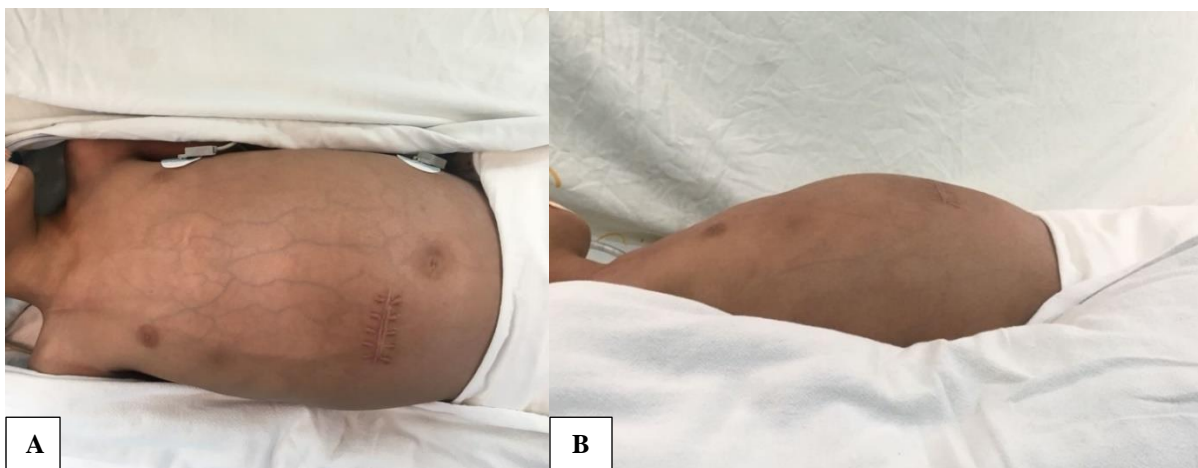


Figure 2: (A) Superior view and (B) lateral view of the patient showing large abdominal distension due to pseudocyst.

DISCUSSION

Tubercular meningitis is the most severe form of extra pulmonary tuberculosis.³ Hydrocephalus is one of the most common complications of tubercular meningitis with incidence rate of 70-95%.^{1,4-6} This incidence is

particularly higher in children with a reported incidence of 87% in children with tubercular meningitis.^{1,4,6} VP shunting, now a commonly used technique for the management of hydrocephalus, is associated with a lot of complications with abdominal complications being very common having a reported incidence of 5-47%.^{7,8} Most

common complications are peritonitis, inguinal hernia, ascites and perforation of bladder or abdominal wall while APC appears to occur rarely.⁹ APC, 1st described by Harsh in 1954, has incidence rate of 1-4.5% of all the shunt cases.^{2,10}

Most of the abdominal pseudocysts are small in size. In the presented case, the pseudocyst is very large measuring 25.3×18.3×9.3 cm in size with approximate volume of 2500 ml. According to our review of literature, this is the 3rd largest abdominal pseudocyst in a pediatric patient and 7th largest overall in a patient with VP shunt. Only 6 other large pseudocysts have been reported (11-16), the largest one overall measuring 12.7 l in an adult patient and 30×15.6×11.8 cm being the largest in a pediatric patient.¹¹⁻¹⁵ The time between VP shunt surgery and development of abdominal pseudocyst in the above cases ranged from 4 months to 12 years.^{11,16} However, in the presented case the patient developed pseudocyst within 6 weeks of VP shunt.

The most common clinical features of an adult patient with an abdominal pseudocyst are pain abdomen, abdominal distension and a palpable abdominal mass while pediatric patients present commonly with clinical symptoms of raised intracranial pressure such as headache, nausea and vomiting.^{17,18} Although in our case, the patient is of pediatric age group and he was admitted due to abdominal distension, pain and vomiting.

The abdominal pseudocyst are usually diagnosed by CT scan and abdominal ultrasonography.¹⁸ The main features of CSF pseudocyst on abdominal ultrasound and CT scanning are intraperitoneal fluid collection with well-defined margins and the finding of the distal tip of the shunt catheter within or close to the pseudocyst as was found in our case.¹⁹

Predisposing factors for development of abdominal pseudocyst include history of previous abdominal surgery leading to peritoneal adhesions, high CSF protein, multiple shunt revisions and peritoneal inflammation leading to decreased CSF absorption.^{18,20,21} The wall of a pseudocyst is composed of non-epithelial tissue such as fibrous tissue or inflamed serosal surface and is filled with CSF and debris.²² It has been suggested that lack of non-epithelial tissue as well as presence of inflammatory infiltrates may hamper absorption of CSF leading to accumulation of CSF in a cyst like space.²³

In the presented case, the cause of abdominal pseudocyst is likely to be inflammation of the peritoneal cavity leading to thickening of the peritoneum which resulted in decreased absorptive capacity of the peritoneal lining hence, leading to accumulation of CSF in a cyst like space delineated by inflammatory adhesions formed due to tuberculosis.

Algorithm for management of APC is discussed under Table 1 and is explained in detail below.

Management

Owing to the rarity of such large cysts, the consensus in the management of such cases is institutionalized and follows no established guidelines. One thing that needs to be highlighted in these cases is the need of comprehensive approach which includes dealing with the distal end of VP shunt as well as the abdominal pseudocyst. Shunt tip needs to be taken out from the cyst cavity, so that the fluid in the cyst can be dealt with, equally important is the diversion of CSF to some other pathway so that the ventricular drainage is not compromised. It is obviously preferred to deal with both the issues in a single operation theatre visit. However, infection is the main factor for deciding the management of the cyst. All the patients need to be thoroughly examined for the same by thorough clinical evaluation and biochemical markers such as TLC/DLC, CRP and procalcitonin.

Management in case of NO pre-existing infection

If the infection has been ruled out, the distal end should be taken out of the cyst cavity and prepared for re-diversion after the CSF is sent for microbiological and biochemical examination. An attempt should be made to re-exploit the abdominal cavity for CSF diversion if sufficient abdominal cavity is available or if normal peritoneal surface is seen. Alternatively, other cavities may be explored for the placement of distal catheter. If at any point, the intraoperatively sent cyst fluid or CSF analysis is suggestive of infection, distal shunt needs to be exteriorized and further management should be done as per protocol for infected pseudocyst. If the cyst is very small and asymptomatic then it can be left inside abdominal cavity. If it is large and causing symptoms then drainage of the cyst may be done via laparoscopic, open or percutaneous (under intraoperative image guidance) approach, the decision for which should be guided by the size of the cyst and surgeon's ease in the procedure.

Management in case of pre-existing infection

If the preoperative evaluation reveals clinical signs of sepsis or the biochemical markers for sepsis are deranged or the intraoperative CSF appearance seems infected, distal end of the shunt should be temporarily diverted via an External Ventricular Drainage (EVD) or converted to an Ommaya reservoir and the patient should be started on antibiotics. If there is gross infection of peritoneum or features of peritonitis are present, it is to be managed by laparotomy and peritoneal lavage. However, if the cyst is infected but contained/localized then it should be managed by open or laparoscopic drainage or excision of cyst. Subsequent permanent CSF diversion should be planned once the infection is settled.

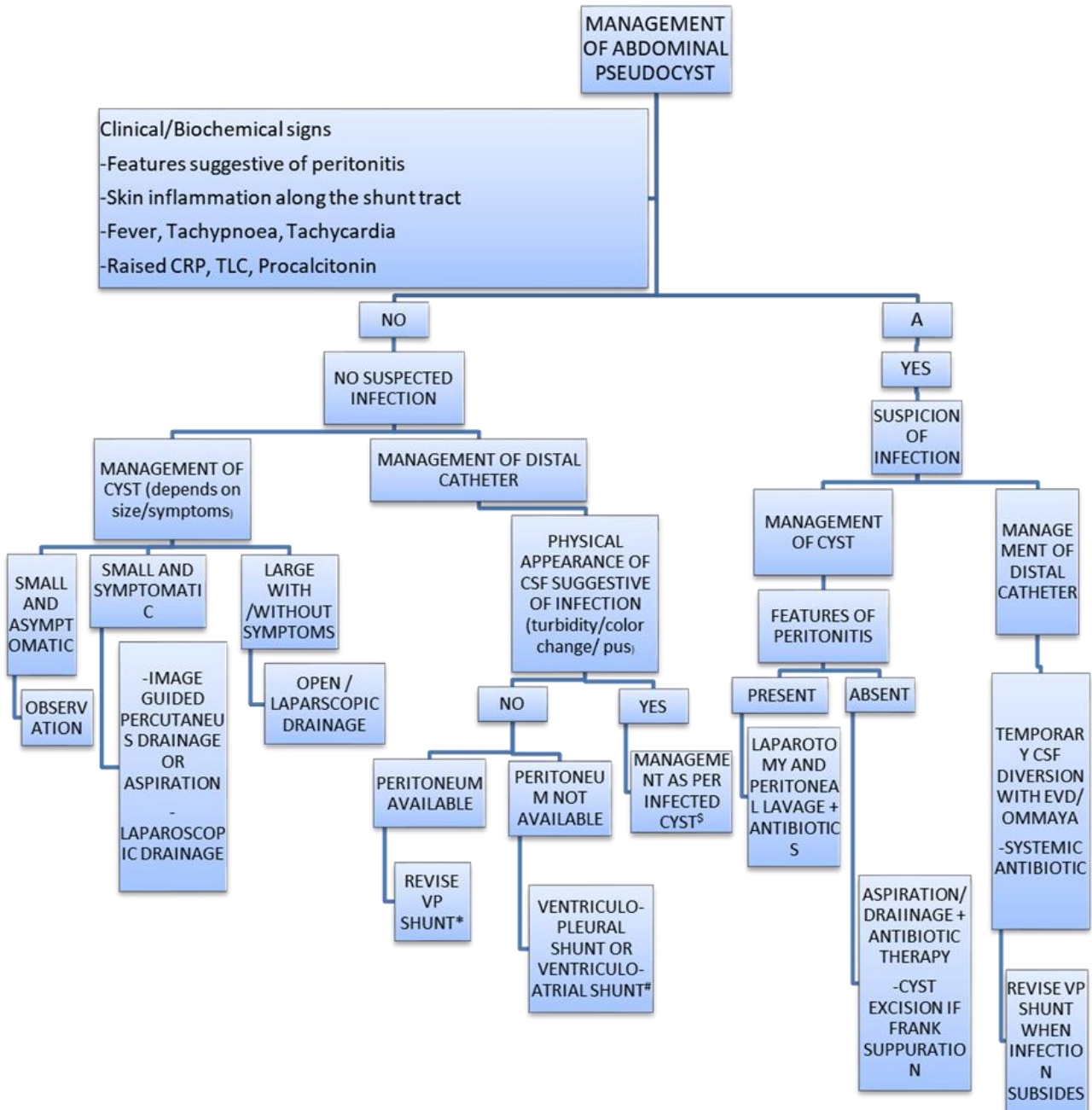


Table 1: Treatment algorithm for management of abdominal pseudocyst secondary to VP shunt failure,

* Subjected to external CSF diversion if CSF analysis suggestive of infection, # Subjected to external CSF diversion if CSF analysis suggestive of infection, # maybe subject to CSF diversion if intraoperative suspicion of infection, \$ as per given under flowchart A.

CONCLUSION

If a patient with VP shunt presents with acute or subacute abdominal distension, abdominal pseudocyst should be considered as one of the differential diagnoses and must be ruled out by either CT or ultrasonography of abdomen. When diagnosed, it should be managed as per protocol discussed above.

*Funding: No funding sources
Conflict of interest: None declared
Ethical approval: Not required*

REFERENCES

1. Rajshekhar V. Management of hydrocephalus in patients with tuberculous meningitis. *Neurol India.* 2009;57(4):368-74.
2. Ohba S, Kinoshita Y, Tsutsui M, Nakagawa T, Shimizu K, Murakami H, et al. Formation of abdominal cerebrospinal fluid pseudocyst: case report. *Neurol Med Chir.* 2012;52(11):838-42.
3. Well GTJV, Paes BF, Terwee CB, Springer P, Roord JJ, Donald PR, et al. Twenty years of pediatric tuberculous meningitis: a retrospective

- cohort study in the Western Cape of South Africa. *Pediatrics.* 2009;123(1):1-8.
4. Bhargava S, Gupta AK, Tandon PN. Tuberculous meningitis: a CT study. *Br J Radiol.* 1982;55(651):189-96.
 5. Ozateş M, Kemaloglu S, Gürkan F, Ozkan U, Hoşoglu S, Simşek MM. CT of the brain in tuberculous meningitis: a review of 289 patients. *Acta Radiol.* 2000;41(1):13-7.
 6. Schoeman J, Donald P, Zyl LV, Keet M, Wait J. Tuberculous hydrocephalus: comparison of different treatments with regard to ICP, ventricular size and clinical outcome. *Dev Med Child Neurol.* 1991;33(5):396-405.
 7. Dabdoub CB, Dabdoub CF, Chavez M, Villarroel J, Ferrufino JL, Coimbra A, et al. Abdominal cerebrospinal fluid pseudocyst: a comparative analysis between children and adults. *Childs Nerv Syst.* 2014;30(4):579-589.
 8. Dabdoub CB, Fontoura EA, Santos EA, Romero PC, Diniz CA. Hepatic cerebrospinal fluid pseudocyst: a rare complication of ventriculoperitoneal shunt. *Surg Neurol Int.* 2013;4:162.
 9. Yuh S, Vassilyadi M. Management of abdominal pseudocyst in shunt-dependent hydrocephalus. *Surg Neurol Int.* 2012;3:146.
 10. Harsh GR. Peritoneal shunt for hydrocephalus, utilizing the fimbria of the fallopian tube for entrance to the peritoneal cavity. *J Neurosurg.* 1954;11(3):284-94.
 11. Wang BH, Hasadsri L, Wang H. Abdominal cerebrospinal fluid pseudocyst mimicking full-term pregnancy. *Journal of Surgical Case Reports.* 2012;2012(7):6.
 12. Lee C, Cheng W, Shen C. Large pseudocyst in the anterior extraperitoneal space as a complication of ventriculoperitoneal shunt. *Formo J Surg.* 2015;48(4):130-2.
 13. Lukhi H, Singh M, Chakravarthy S, Perwez N. Largest Abdominal CSF Pseudocyst—An Uncommon Complication of VP Shunt. *NJR.* 2013;3(1):89-90.
 14. Ayan E, Tanriverdi HI, Caliskan T, Senel U, Karaarslan N. Intraabdominal pseudocyst developed after ventriculoperitoneal shunt: a case report. *J Clin Diagn Res.* 2015;9(6):5-6.
 15. Ouladsaiad M, Hokoumi H, Aballa N. A giant abdominal cerebrospinal fluid pseudocyst. *Iran J Neurosurg.* 2017;3(3):109-14.
 16. Yim SB, Chung YG, Won YS. Delayed abdominal pseudocyst after ventriculoperitoneal shunt surgery: a case report. *Nerve.* 2018;4(2):111-4.
 17. Pathi R, Sage M, Slavotinek J, Hanieh A. Abdominal cerebrospinal fluid pseudocyst. *Australas Radiol.* 2004;48(1):61-3.
 18. Rainov N, Schobess A, Heidecke V, Burkert W. Abdominal CSF pseudocysts in patients with ventriculo-peritoneal shunts. Report of fourteen cases and review of the literature. *Acta Neurochir.* 1994;127(1-2):73-8.
 19. Aparici-Robles F, Molina-Fabrega R. Abdominal cerebrospinal fluid pseudocyst: a complication of ventriculoperitoneal shunts in adults. *J Med Imaging Radiat Oncol.* 2008;52(1):40-3.
 20. Anderson CM, Sorrells DL, Kerby JD. Intraabdominal pseudocysts as a complication of ventriculoperitoneal shunts. *J Am Coll Surg.* 2003;196(2):297-300.
 21. Rovlias A, Kotsou S. Giant abdominal CSF pseudocyst in an adult patient 10 years after a ventriculo-peritoneal shunt. *Br J Neurosurg.* 2001;15(2):191-2.
 22. Sharma AK, Pandey AK, Diyora BD, Mamidanna R, Sayal PP, Ingale HA. Abdominal CSF pseudocyst in a patient with ventriculoperitoneal shunt. *Indian Journal of Surgery.* 2004;66(6):360-3.
 23. Anwar R, Sadek A, Vajramani G. Abdominal pseudocyst: a rare complication of ventriculoperitoneal shunting. 2017;17(3):212-3.

Cite this article as: Madaan P, Grewal I, Gupta VK, Kulshreshtha A, Gupta S. Management strategies for giant abdominal pseudocyst in a patient with ventriculoperitoneal shunt. *Int Surg J* 2021;8:1386-90.