

Case Report

Multiple spontaneous jejunal and ileal perforations: a diagnostic challenge

Vijayalakshmi Sunder*, Shanthi Ponandal Swaminathan, Vikas Kawarat,
Kamalraj Maiyazhagan, Shriram Khanna, Rajeswari Mani, Kannan Ross

Institute of General Surgery, Madras Medical College and Rajiv Gandhi Government General Hospital, Chennai,
Tamil Nadu, India

Received: 17 February 2021

Revised: 24 February 2021

Accepted: 02 March 2021

*Correspondence:

Dr. Vijayalakshmi Sunder,

E-mail: vijisunder93@gmail.com

Copyright: © the author(s), publisher and licensee Medip Academy. This is an open-access article distributed under the terms of the Creative Commons Attribution Non-Commercial License, which permits unrestricted non-commercial use, distribution, and reproduction in any medium, provided the original work is properly cited.

ABSTRACT

Spontaneous multiple jejunal perforations are rare. In India, the commonest cause of small bowel perforation is typhoid fever followed by tuberculosis. We report a case of multiple jejunal and ileal perforations in a 23-year-old young woman who was known to have ulcerative colitis on medical therapy including steroids. She was then diagnosed to have active pulmonary tuberculosis and commenced on anti-tuberculosis therapy. She presented with generalised peritonitis and underwent emergency bowel resection with proximal enterostomy and creation of mucous fistula of the distal ileum. Post-operative course was stormy due to sepsis and she eventually succumbed on the 3rd post-operative day. Histopathological examination revealed non-specific changes and was not contributory to diagnosis. Possible causes of spontaneous jejunal perforations are discussed and the literature is reviewed. This case, despite a fatal outcome, is being reported to highlight the need for high index of suspicion in such situations.

Keywords: Jejunal perforations, Ileal perforations, Tuberculosis, Typhoid fever, Coeliac disease

INTRODUCTION

Spontaneous multiple small bowel perforations are rare. Perforations of jejunum and ileum contribute to around 0.4% of patients presenting with acute abdomen.¹ While the diagnosis of hollow viscus perforation is relatively straight forward, the site of perforation is often made only after laparotomy. The cause of small bowel perforation, in India, is often due to infections – typhoid fever and tuberculosis. In the Western countries, trauma forms the leading cause, followed by closed loop obstructions, malignancy, jejunal diverticula and tumours.² Less common causes of small bowel perforations include Crohn's disease, ischaemia, iatrogenic manipulations, and drugs such as potassium chloride and steroids.²

The underlying cause for the small bowel perforations can often be diagnosed; however, there are instances when the

diagnosis proves elusive to be arrived at. Pneumoperitoneum is present in only 50 % of the cases and if the clinical signs are subtle, there may be delay in diagnosis which can be life threatening.³ We describe a case of multiple small bowel perforations and the management. Diagnostic challenges and differential diagnoses are discussed.

CASE REPORT

A 23-year-old unmarried young woman presented to the emergency department with generalised abdominal pain of six hours duration which was of sudden onset. There was no history of vomiting, diarrhoea, constipation, or trauma.

A few months prior to this episode of acute abdominal pain, she was diagnosed to have ulcerative colitis for which she was on mesalamine. Since she continued to have

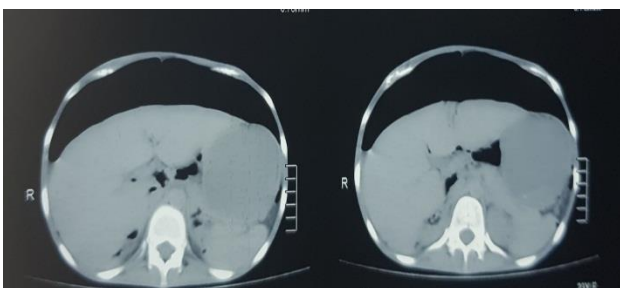
diarrhoea and bloody motions she was also commenced on oral steroids (prednisolone-20 mg/d). However, she developed cough with sputum. Chest X ray showed infiltration in the right lung and her sputum was positive for acid-fast bacilli (AFB). She was commenced on anti-tuberculous therapy and steroid therapy was stopped 10 days prior to presentation. There was no history of headaches or fever. She had menstrual irregularities and now reported seven months amenorrhoea.

On admission, she was found to be malnourished with pulse rate of 120/min, blood pressure (BP) of 90/70 mm Hg and saturations of 94% on room air. Abdominal examination revealed generalised tenderness with guarding. Bowel sound were absent. A plain radiograph revealed free air under diaphragm with pneumonitis on the right lung (Figure 1).



Figure 1: Chest x ray revealed free air under the diaphragm with tubercular collapse-consolidation right upper lobe and upper mediastinal shift to the right.

Abdominal CT scan showed pneumoperitoneum (Figure 2 and 3). NG tube was placed, and she was commenced on broad spectrum antibiotics. Her blood tests were normal except for leucocytosis (32,500/cu/mm) and thrombocytosis (591,000/cu/mm).



Figures 2: Transverse sections on CT scan showing free air in the peritoneal cavity above the liver.

She was taken up for emergency laparotomy after informed consent. A midline laparotomy revealed grossly soiled peritoneal cavity with intestinal contents and chemical peritonitis. More than 1.5 litres of peritoneal fluid were sucked out. Faecal contamination from the distal ileal perforations were present. There were no

peritoneal deposits suggestive of tubercles seen. There was no area of narrowing or strictures in the bowels. There were no diverticula seen in both small and large bowels. The stomach, duodenum, and colon normal. Multiple interloop adhesions of small bowel were found. Transverse colon epiploicae formed a band over an ileal loop and was attached to the mesentery which was divided. There were enlarged mesenteric nodes.

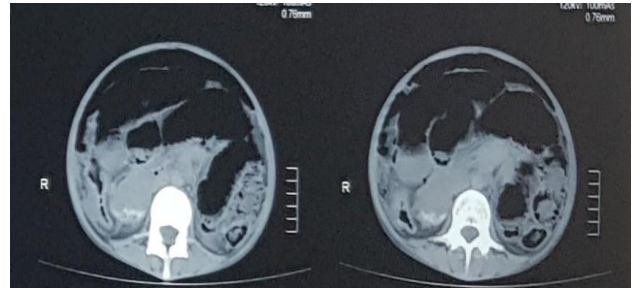


Figure 3: Transverse sections showing free air above the bowels.

Multiple perforations were seen in the jejunum and ileum (Figure 4 and 5) extending from 30 cm beyond the duodeno-jejunal (DJ) flexure until 50 cm proximal to the ileo-caecal valve. Given the proximity of the perforations to each other, the large number, and the degree of peritoneal soiling it was decided that repair of individual perforations would be inappropriate and hence involved portion of the small bowel extending from 30 cms distal to DJ flexure up to 50 cm proximal to the ileo-caecal valve was excised. Given the soiling, no primary bowel anastomosis was performed. Both ends of the bowels were brought out to the abdominal wall as an enteric stoma - a jejunostomy proximally and a mucous fistula was created with the distal ileal end (Figure 6).

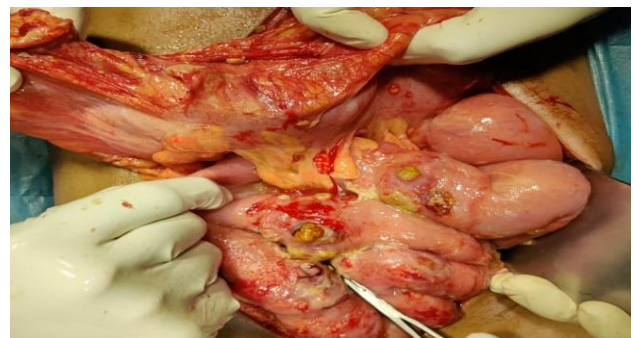


Figure 4: Multiple perforations seen with contents protruding out of the bowel.

Thorough peritoneal lavage with copious amounts of warm saline was performed. Sub hepatic, pelvic and flank drains were sited and abdominal closed in a single layer. During surgery, she had blood transfusion. She also required large volumes of colloids and crystalloids to maintain mean arterial pressure. Vasopressors, too, were commenced as she remained hypotensive even after adequate fluid replenishment.

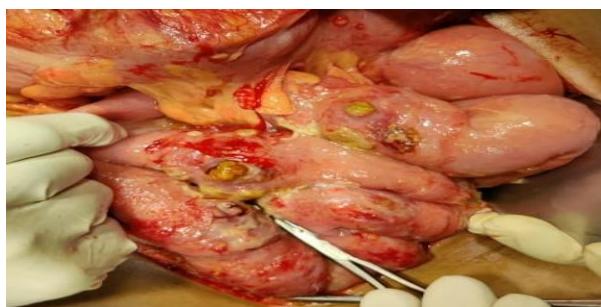

Figure 5: Closer view of the perforations, loops of bowel are seen adherent together with inflammatory exudate.

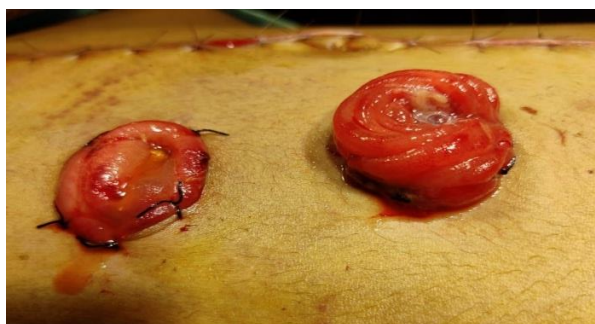

Figure 6: Jejunostomy of the proximal end and mucous fistula of the distal ileal end.

The resected specimen (Figure 7) was sent for histopathological examination which revealed largely non-specific features of inflammation near the perforations. There were no features suggestive of tuberculosis, typhoid, coeliac disease or inflammatory bowel disease (Chron's disease or ulcerative colitis) in the resected specimen.

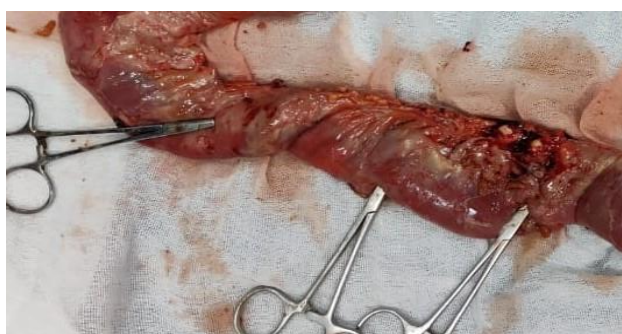

Figure 7: A portion of the resected specimen showing multiple perforations at the sites indicated by the artery forceps placed in the perforation.

She was kept ventilated in the ICU post-operatively. Adequate fluid balance was achieved by meticulous attention to output from stoma, NG tube and urinary volumes. She was wide awake and obeying commands. However, she required dual vasopressors with inotropes to achieve a mean arterial pressure of 70 mm Hg. Over the next few days, she became oligo-anuric and her condition deteriorated. Despite aggressive therapy, she succumbed

to sepsis on the 3rd post-operative day. Blood cultures were reported to have grown multi drug resistant acinetobacter. Peritoneal fluid grew *Escherichia coli*. There was no acid-fast bacilli in the peritoneal fluid.

The exact diagnosis – cause for the multiple small bowel perforations - in this case remains unclear. The possible causes of small bowel perforations and their likelihood in the present case is discussed. The histological features were largely non-specific with no definitive diagnosis possible on histological grounds.

DISCUSSION

Intestinal perforations constitute a surgical emergency and often needs emergency surgery promptly. Delay in surgery increases mortality. Laparoscopic approaches are being increasingly used in high volume centres.^{4,5}

While diagnosis of a hollow viscus perforation can be made pre-operatively, the exact site of perforation- especially in the case of jejunal perforations -are most often diagnosed intra-operatively. In the absence of trauma, perforations of small bowel are often spontaneous.^{6,7} The cause of these spontaneous perforation usually becomes evident at operation.

In case of ileal perforations, in India, the commonest cause is typhoid fever.^{8,9} The perforations due to typhoid fever could be multiple.^{10,11} The surgical outcomes following repair of ileal perforations due to typhoid depend on the time interval between perforation and repair, and the quantity of peritoneal fluid. Delay in repair with peritoneal fluids greater than 1000 ml are associated with high mortality.¹² Our patient had gross contamination with 1.5 litres of peritoneal fluid at operation. This perhaps contributed to the mortality, even though the patient was operated upon within 24 hours of onset of symptoms.

Tuberculosis accounts for only 5 to 9% of all small bowel perforations.¹³ However, tuberculosis most often causes bowel wall thickening, fibrosis and intestinal strictures causing obstruction as opposed to perforations, which is relatively rare. Trauma is the next common cause for ileal perforations. Inflammatory disease due to Crohn's disease also causes ileal perforations. Free perforations into the peritoneal cavity are rare in Crohn's disease. Most often a hollow viscus fistulates into another hollow viscus.

In the case of jejunal perforations, the common causes include jejunal diverticulosis, volvulus of the diverticuli or foreign body in diverticulum, coeliac disease complicated by lymphoma. Dengue has been reported to cause multiple jejunal perforations.¹⁴⁻¹⁷

Steroid induced bowel perforations have been described.^{18,19} However, this perforations occur after prolonged therapy with high dose steroids. Co-existent tuberculosis and typhoid causing multiple small bowel perforations have been described.²⁰

In our patient, the presence of active pulmonary tuberculosis would make one consider tuberculosis as the first diagnosis. However, there were no features of tuberculous abdomen – no tubercles or thickening of bowel wall. More importantly, histopathology did not reveal definitive evidence of tuberculosis.

Ileal perforation as the first manifestation of typhoid fever in the absence of toxic symptoms of fever, headaches is very unlikely. Moreover, there were no histopathologic features of typhoid in the resected specimen.

Steroids causing bowel perforations usually occur after prolonged intake with high doses. Our patient had only 15-day course of steroids which was stopped after the diagnosis of pulmonary tuberculosis. Moreover, the last dose of steroid was 10 days prior to her presenting symptoms. Also, steroid therapy causing multiple perforations has not been described.

In the absence of any pathognomonic feature of any condition, a diagnosis of “non-specific small bowel perforation” may have to be done.

CONCLUSION

This rare case high lights the high mortality involved in such situations and underscores the point that diagnosis can be elusive in a few cases. Such instances of “non-specific small bowel perforations” may have to be borne in mind when confronted with similar situations.

Funding: No funding sources

Conflict of interest: None declared

Ethical approval: Not required

REFERENCES

1. Hines J, Rosenblat J, Duncan DR, Friedman B, Katz DS. Perforation of the mesenteric small bowel: Etiologies and CT findings. *Emerg Radiol.* 2013;20(2):155-61.
2. Pouli S, Kozana A, Papakitsou I, Daskalogiannaki M, Raissaki M. Gastrointestinal perforation: clinical and MDCT clues for identification of aetiology. *Insights Imaging.* 2020;11(1):31.
3. Lo Re G, Mantia F La, Picone D, Salerno S, Vernuccio F, Midiri M. Small Bowel Perforations: What the Radiologist Needs to Know. *Semin Ultrasound.* 2016;37(1):23-30.
4. Sakaguchi T, Tokuhara K, Nakatani K, Kon M. Laparoscopic management for spontaneous jejunal perforation caused by nonspecific ulcer: A case report. *Int J Surg Case Rep.* 2017;39:309-12.
5. Streck CJ, Lobe TE, Pietsch JB, Lovvorn HN. Laparoscopic repair of traumatic bowel injury in children. *J Pediatr Surg.* 2006;41(11):1864-9.
6. Freeman HJ. Spontaneous free perforation of the small intestine in adults. *World J Gastroenterol.* 2014;20(29):9990-7.
7. Demirli Atici S, Yeşilyurt D, Akpınar G, Üstün M, Aydın C. Spontaneous perforation of jejunal ulcer. *Duzce Med J.* 2020;22(1):51-3.
8. Verma H, Pandey S, Sheoran KD, Marwah S. Surgical Audit of Patients with Ileal Perforations Requiring Ileostomy in a Tertiary Care Hospital in India. *Surg Res Pract.* 2015;1-4.
9. Jhobta RS, Attri AK, Kaushik R, Sharma R, Jhobta A. Spectrum of perforation peritonitis in India-review of 504 consecutive cases. *World J Emerg Surg.* 2006;1(1).
10. Sharma A, Sharma R, Sharma S, Sharma A, Soni D. Typhoid intestinal perforation: 24 Perforations in one patient. *Ann Med Health Sci Res.* 2013;3(5):41.
11. Nasir AA, Adeniran JO, Abdur-Rahman LO, Odi TO OJ. Typhoid intestinal disease: 32 perforations in 1 patient. *Niger Postgr Med J.* 2008;15(1):55-7.
12. Sheshe A, Anyanwu L-J, Mohammad A, Muhammad A, Obaro S. Typhoid intestinal perforation: Analysis of the outcome of surgical treatment in Kano, Nigeria. *Arch Med Heal Sci.* 2018;6(1):59.
13. Debi U, Ravisankar V, Prasad KK, Sinha SK, Sharma AK. Abdominal tuberculosis of the gastrointestinal tract: Revisited. *World J Gastroenterol.* 2014;20(40):14831-40.
14. Kassahun WT, Fangmann J, Harms J, Bartels M, Hauss J. Complicated small-bowel diverticulosis: A case report and review of the literature. *World J Gastroenterol.* 2007;13(15):2240-2.
15. Neal HSDR. Jejunal diverticulosis complicated by volvulus and recurrent spontaneous diverticular perforation. *Br J Clin Pr.* 1990;44:644-6.
16. Fidler M. Foreign-body perforation of a jejunal diverticulum. *Br J Surg.* 1972;59(9):744-5.
17. Kumar Jain AC. Multiple jejunal perforations in dengue. *Int J Adv Med.* 2017;1(2):153-4.
18. He J-N, Tian Z, Yao X. Multiple perforations and fistula formation following corticosteroid administration: A case report. *World J Clin Cases.* 2017;5(2):67.
19. ReMine SG, McIlrath DC. Bowel perforation in steroid-treated patients. *Ann Surg.* 1980;192(4):581-6.
20. Grieco M, Polti G, Lambiase L, Cassini D. Jejunal multiple perforations for combined abdominal typhoid fever and miliary peritoneal tuberculosis. *Pan Afr Med J.* 2019;33:51.

Cite this article as: Sunder V, Swaminathan SP, Kawarat V, Maiyazhagan K, Khanna S, Mani R, et al. Multiple spontaneous jejunal and ileal perforations: a diagnostic challenge. *Int Surg J* 2021;8:1370-3.