

Original Research Article

The posterior interosseous artery flap versus the adipofascial radial artery perforator flap in reconstruction of firecracker and homemade bomb blast injuries of the hand

Madhumita Gupta*, Prabir Kumar Jash

Department of Plastic Surgery, Medical College and Hospital, Kolkata, West Bengal, India

Received: 07 February 2021

Revised: 27 February 2021

Accepted: 01 March 2021

***Correspondence:**

Dr. Madhumita Gupta,

E-mail: docmadhu82@gmail.com

Copyright: © the author(s), publisher and licensee Medip Academy. This is an open-access article distributed under the terms of the Creative Commons Attribution Non-Commercial License, which permits unrestricted non-commercial use, distribution, and reproduction in any medium, provided the original work is properly cited.

ABSTRACT

Background: The soft tissues of the radial aspect of the hand are predominantly affected in firecracker and homemade bomb blast injuries. In such cases, regional flap options are quite appealing for defect coverage. We have compared the outcomes of using two pedicled regional forearm flaps in these injuries, the posterior interosseous artery flap (PIAF) and the adipofascial radial artery perforator flap (ARAPF).

Methods: 37 patients underwent reconstruction of the hand with PIAF (20 cases) and ARAPF (17 cases) between January 2014 and December 2019. They were compared with regards to patient demographics, reconstruction techniques, short-term and long-term functional and aesthetic outcomes using the disabilities of the arm, shoulder and hand (DASH) score and the subjective satisfaction score (SSS).

Results: All our flaps survived without any major complications affecting long-term outcome. We found no statistically significant difference between the two flaps in terms of patient demographics, flap paddle size, duration of hospital stay, DASH score and SSS for recipient site. However, significant difference was noted in the duration of surgery, method of donor site closure and SSS for the donor site.

Conclusions: Both the PIAF and ARAPF can be considered in cases of soft tissue defects of the hand from firecracker or bomb blast injuries. Both preserve the major arteries of the hand while still having reliable vascular pedicle.

Keywords: Adipofascial radial artery perforator flap, Bomb blast injury, Firecracker, Hand, Posterior interosseous artery flap

INTRODUCTION

The reconstruction of soft tissue defects of the hand with exposure of underlying vital structures like tendons, bones, joints and neurovascular bundles can be quite challenging.^{1,2} The principle aims of plastic surgical reconstruction of such complex soft tissue injuries are infection prevention, protection of vital structures and preservation or restoration of adequate hand function. Various coverage options for these cases include local, regional, distant or microsurgical free flaps. Ideally such reconstructions should be expeditious, single-staged and allow for early limb mobilization and short hospital stay.

Blast injuries of the hand can have disastrous consequences. These have been usually associated with military and terrorist attacks.³ In India, however, a different pattern of blast injury is commonly encountered. This results from either recreational bursting of firecrackers or the handling of homemade bombs, which have widely variable blast potential with explosives deflagrating at rates ranging from 400 to 9000 m/sec.⁴ Due to the predominantly centrifugal action of the energy vector in such injuries, the radial aspect of the hand is most commonly affected; mainly involving the first to third rays, thenar eminence and the first web space. The result can be varying degrees of damage to the soft tissue,

bones and joints, neurovascular structures or even disarticulation amputations worse at the radial digits.⁵ In less severe cases, deep abrasions or lacerations can be addressed with either secondary intention wound healing, delayed primary repair or skin grafting.⁵ But severe cases presenting with tissue avulsion of the radial digits and first web space require resurfacing with durable and pliable flaps. The presence of an adequately spanned first web space is a pre-requisite for prehensile hand function.⁶ In blast injuries, a broad zone of injury rules out the options of using local flaps.^{7,8} Microvascular free flaps can be used in such situations. But, they require special technical expertise, set-up and longer operating times.^{1,2,9} Distant flaps like the groin, abdominal, chest or hypogastric flaps can also be used, although limited by the need for a two-staged procedure, uncomfortable limb positioning and relative delay in hand mobilization.¹⁰ The pedicled regional flaps from the forearm provide quite an attractive option in these patients. These can be either based on axial vessels like the radial, ulnar, anterior and posterior interosseous or based on perforators. The flap paddle may be fasciocutaneous or adipofascial, thus sparing the forearm skin. The choice of flap in reconstructive hand surgery is often debatable and depends on the surgeon's preference in addition to factors related to the patient's injury or general health.¹¹

In our study, we compared the technical details and outcomes of reconstructing firecracker and homemade bomb blast injuries of the hand with posterior interosseous artery flap (PIAF) and the adipofascial radial artery perforator flap (ARAPF).

METHODS

A retrospective, observational study was conducted at the Department of Plastic and Reconstructive Surgery at the Medical College and Hospital, Kolkata, India for patients presenting between January 2014 and December 2019 with soft tissue defects of the hand due to firecracker or homemade bomb blast injuries who underwent reconstruction with either the PIAF or the ARAPF. Patients with additional injuries to any other part of the same upper limb proximal to the distal wrist crease were excluded. Informed written consent was obtained from all subjects prior to the procedure. The study methodology was approved by the Institutional Ethical Committee for Research and Development.

All 37 patients had presented to the emergency department with either firecracker or homemade bomb blast injuries sustained within the last 24 hours. After the initial emergency debridement and washout in theatre, definitive flap coverage was carried out in a delayed primary setting during the same admission in semi-elective daytime hand trauma lists.

Following the first debridement, the injuries were categorised into mild, moderate, severe and major as per the hand injury severity score (HISS).¹² The mild injuries

only involve soft tissue loss, moderate includes additional bone and joint injuries, severe refers to neurovascular structure damage, whereas, major involves traumatic disarticulation or amputation of a part or whole of the hand.

Anatomy and surgical technique

PIAF: The posterior interosseous artery is a branch of the interosseous artery which, in turn, arises from the ulnar artery. It passes dorsal to the superior border of the interosseous membrane of forearm and traverses distally in the plane between abductor pollicis longus and supinator muscles. 5-13 cutaneous perforators arise from the main vessel, most of them in the proximal half of forearm. The vessel finally anastomoses with the dorsal perforating branch of the anterior interosseous artery and the dorsal carpal branch of the radial artery about 2.5 cm proximal to the distal radio-ulnar joint (DRUJ).¹³ The flap was raised under tourniquet control. Pre-operative handheld Doppler signal localisation of a suitable perforator was carried out. The flap paddle was designed in reverse from a defect template after centralising the perforators. Flap elevation was in a proximo-distal direction. The septocutaneous perforators were delicately dissected up to the main vessel in the intermuscular plane between extensor carpi ulnaris and extensor digiti minimi, carefully preserving the posterior interosseous nerve branches. Dissection was stopped at least 2.5 cm proximal to the DRUJ. The flap was tunnelled to the hand defect avoiding any kinks or compression. The donor area was either skin grafted or directly closed, depending of the flap size and surrounding tissue laxity (Figure 1).

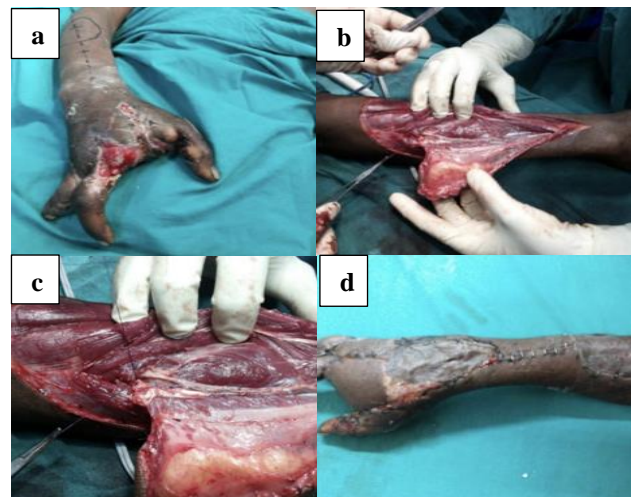


Figure 1: The PIAF: (a) pre-operative marking, (b) intra-operative dissection, (c) demonstration of vascular pedicle, (d) inset of flap paddle and skin grafting of donor site.

ARAPF: The radial artery traverses in the forearm in the inter-muscular plane between the flexor carpi radialis and the brachoradialis muscles. An average of 6 fasciocutaneous perforators arising from this artery are

usually detected within 15 cm proximal to the distal wrist crease, of which about 2 clinically significant ones (>0.5 mm) are located around 2 cm proximal to the radial styloid process.^{14,15} The flap was harvested under tourniquet control after pre-operative mapping of suitable perforator guided by handheld Doppler signal. The flap paddle was designed in reverse from a defect template. A lazy-S skin incision was centred over the radial artery axis. Flap was elevated in a proximo-distal direction. The adipofascial flap was harvested including the cephalic vein. Dissection was stopped about 2.5 cm proximal to the radial styloid process to preserve the prominent perforator(s). The flap was then flipped over and tunnelled to the hand defect without any twist or compression and covered with a split-thickness skin graft (Figure 2).

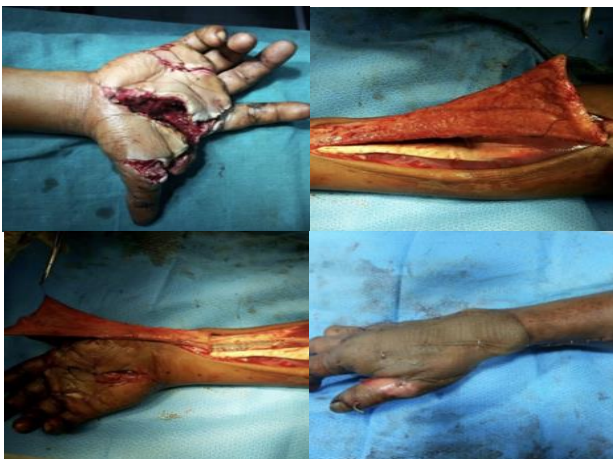

Figure 2: The ARAPF: demonstration of flap harvest and inset with skin grafting of flap paddle.

In both the cases, light post-operative bandage was used with flap monitoring window. The limb was kept elevated on a pillow avoiding any pressure on the flap paddle or pedicle. The dressings were changed with a graft check on post-operative day 5-7. The patients were regularly followed up in outpatient clinic and hand physiotherapy unit following discharge for at least a year (range 1-2.5 years).

The demographic distribution of patients in the two groups (PIAF and APAPF) were compared in terms of age, sex, laterality of the injury and hand dominance. The injury severity was graded according to the HISS score.¹² The PIAF and ARAPF flap techniques were compared in terms of the total flap size, donor site closure and duration of surgery.

The outcomes were assessed short-term with respect to flap survival, venous congestion, wound dehiscence, need for return to theatre and duration of post procedure hospital stay. The long-term assessment involved recording the patient's satisfaction with the results as reported by the subjective satisfaction score (SSS) for both the donor and the recipient sites. This score was

assessed by using a visual analogue scale (1-10: 1 being extremely dissatisfied to 10 being extremely satisfied). The functional outcome was measured by the DASH (disabilities of the arm, shoulder and hand) score.¹⁶ This is a 30 part questionnaire with each answer scored on a scale of 1 (no difficulty) to 5 (maximum difficulty). At least 27 questions need to be answered to obtain a valid score. The sum total of all the scores gives the raw score. The raw score is then transformed to a 0-to-100 scale with 0 depicting no disability and 100 depicting maximum disability.

The results were analysed using the two-tailed Mann-Whitney U test (as the total number of patients in each group was <30) and Chi-square test. The level of statistical significance was considered as $p < 0.05$.

RESULTS

37 patients with firecracker and homemade bomb blast injuries of the hand presenting to the Plastic and Reconstructive Surgery Department of the Medical College and Hospital, Kolkata, India between January 2014 and December 2019 were reconstructed with the PIAF (20 cases, M:F=17:3) and the ARAPF (17 cases, M:F=13:4) flaps. All had soft tissue defects involving the radial aspect of the hand including the dorsum, and the first web space. The demographic distribution of the patients in the two groups are depicted in Table 1. The mean flap paddle areas were 33.57 ± 10.5 cm² (range 19.25-56 cm²) for the PIAF group and 29.44 ± 7.53 cm² (range 17.5-45 cm²) for the ARAPF group. The difference between the flap dimensions of the two groups was not statistically significant.

Table 1: Distribution of demographic factors and hand injury severity score (HISS) in the study population.

Demographic criteria	PIAF	ARAPF
Number of patients	20	17
Age in years (mean±SD; range)	32.95±14.25 12-68	35.82±15.72; 17-76
Sex (male:female)	17:03	13:04
Laterality (right:left)	16:04	14:03
Hand dominance (dominant:non-dominant)	17:03	15:02
HISS grade (mild: moderate: severe: major)	4, 7, 5, 4	4, 7, 3, 3

15 donor sites in the PIAF group needed a skin graft for closure; of the remaining 5 cases closed directly the maximum dimension allowing for primary closure of donor site was recorded at 4.5×7.5 cm². The ARAPF being an adipofascial flap, the skin over the donor area was directly closed without any case of recorded wound infection, dehiscence or skin flap necrosis. All donor sites healed satisfactorily without any major complications.

The difference in technique of donor site closure was found to be statistically significant at $p=0.000004$.

All the flaps from both groups were viable. In the PIAF group one flap suffered from venous congestion that was managed with medicinal grade leech therapy for 4 days with complete flap paddle salvage. In the ARAPF group, one patient had distal marginal flap necrosis that caused some wound dehiscence over a small ($1 \times 0.5 \text{ cm}^2$) area, and was managed by a return to theatre on post-operative day 9 for debridement of involved part and direct closure. There was no recorded palsy of the posterior interosseous nerve in the PIAF group.

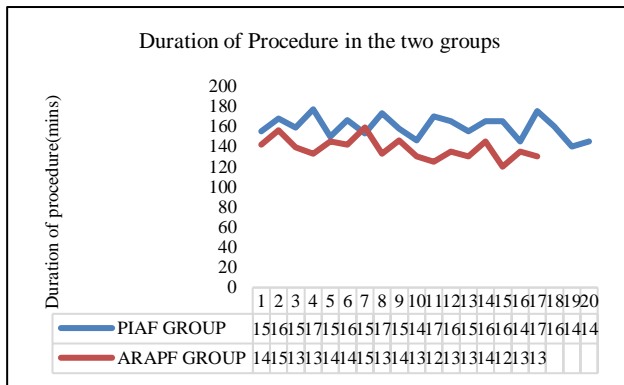


Figure 3: The distribution of duration of surgical procedure in the two groups.

The mean duration of surgery (Figure 3) in the PIAF group was 159.5 ± 10.77 minutes (range 140-177 minutes); whereas the same in the ARAPF group was 137.94 ± 10.35 minutes (range 120-159 minutes). The difference between the two groups was statistically significant.

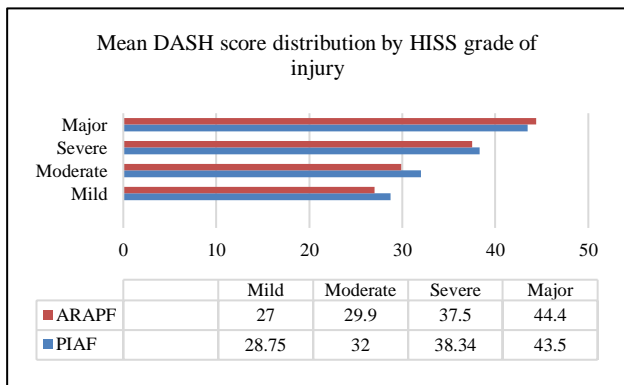


Figure 4: The distribution of mean DASH score categorized by the HISS injury grades for the two groups.

The duration of post-operative hospital stay was noted at 7.35 ± 1.14 days (range 7-12 days) for the PIAF group and 7.35 ± 0.78 days (range 7-10) for the ARAPF group. The difference between the two was not statistically significant. The single patient in the PIAF arm who

developed venous congestion and needed leech therapy stayed longer (12 days), while the one in the ARAPF arm needing debridement of marginal necrosis and re-inset of flap stayed for 10 days.

The mean DASH score for the PIAF group was 34.95 ± 5.67 , while the same for the ARAPF group was 33.44 ± 6.54 . When the DASH score was correlated with the injury severity as per the HISS grades, no statistically significant difference in eventual functional outcome could be detected in the two groups (Figure 4).

The distribution of subjective satisfaction score for both the donor and recipient sites in the two groups are depicted in Figure 5. The mean \pm SD scores were 6.9 ± 1 and 7.35 ± 0.6 for the PIAF and ARAPF donor sites respectively; while the same for the recipient sites were 7 ± 0.69 and 6.9 ± 0.66 . There was a statistically significant difference between the two groups with respect to satisfaction with the donor site ($p=0.008$), but not the recipient site ($p=0.79$).

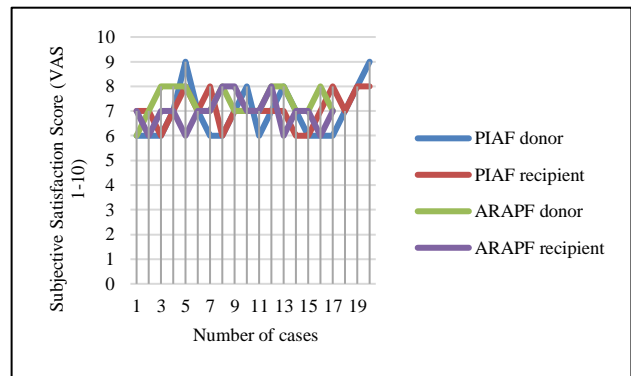


Figure 5: The distribution of the subjective satisfaction score for both the donor and recipient sites in the two groups.

DISCUSSION

Appropriate thin, pliable and single-staged soft tissue coverage of hand defects is crucial for effective protection of vital structures, as well as for allowing adequate hand mobilization in order to achieve the best functional outcome possible.¹⁷ The forearm is a suitable regional donor site for providing various vascularised flap options aimed at hand coverage.¹⁸ Amongst the various possible options, the distally based radial forearm flap, the radial artery perforator flap and the posterior interosseous artery flap are the ones that allow a good reach to resurface defects predominantly affecting the radial aspect of the hand, which is the usual pattern noted in firecracker and homemade bomb blast injuries.⁵

The original radial forearm flap (Chinese flap) was first used by Lin et al for hand and finger soft tissue coverage.¹⁹ Though it is reliable in its vascular supply and provides a thin, pliable cover; its main drawbacks include sacrificing a major artery of the hand and donor

site morbidities.²⁰ In 1990, Chang et al performed an anatomic study of 14 cadaveric forearms and designed a distally based radial forearm adipofascial flap for hand reconstruction.²¹ They detected about 10 small septocutaneous perforators starting from 1.5 cm proximal to the radial styloid process up to the bifurcation of the radial artery.²² This flap has the obvious advantage of allowing direct donor site skin closure and sparing of a major hand vessel.²³

The posterior interosseous artery flap also avoids sacrificing a major hand artery, but involves slightly more tedious dissection in order to preserve the posterior interosseous nerve branches.²⁰

In our comparative study, the majority of the patients were young adult males (PIAF: 85% males, ARAPF: 76.5% males) with the dominant hand most commonly affected. This finding is consistent with other series reporting similar mechanism of hand injury.^{24,25}

In this study, PIAF flap paddle size ranged from 19.25-56 cm², while ARAPF flap size ranged from 17.5-45 cm². Mahmoud et al reported paddle sizes ranging from 40 to 100 cm² for the adipofascial radial artery perforator flap.²³ However, Al Najjar concluded that this flap can be safely used to cover small to moderate sized (12-63 cm²) defects.²⁶ The average dimensions reported for the PIAF range from 6-99 sq cm.²⁷ In both groups of patients we have used comparable flap dimensions which corroborate with those from other series.

The pivot point for the ARAPF flap in our series was located at 2.5 cm proximal to the radial styloid process. This is consistent with Chang and Hou, who proposed it to be between 2 and 4 cm above this bony landmark.²⁸

Various studies have reported the operative time for the adipofascial radial artery perforator flap to be around one and a half to two hours.^{23,29} In our cases, the mean duration of operation for the ARAPF group was 138 minutes, which is slightly higher. Other comparative studies have reported the duration of posterior interosseous flap technique at around 160 minutes which is similar to our finding.³⁰ The relatively more tedious dissection of the vascular pedicle from the posterior interosseous nerve can be stated as the reason of the longer duration of procedure in the PIAF group.

Some studies have mentioned venous congestion as an important complication for the PIAF flap which can result in partial or complete flap necrosis. We experienced this complication in one flap which eventually could be fully salvaged with the help of leech therapy.

Previous studies have reported the post-operative stay to range between 5-15 days in cases of both the PIAF and ARAPF flaps.^{23,30,33} In our series the same ranged from 7-12 days which is comparable to other studies and failed to show any significant difference between the two arms.

With regards to the functional outcome, our study did not reveal any significant difference between the two groups. When the outcome was categorised according to the HISS score of injury, the overall hand function was found to be good and as per expectation. Our DASH scores in both groups corroborated well with scores for other upper limb pathologies and procedures, which typically ranges between 25 and 50.³⁴

The long-term subjective satisfaction amongst our patients from both the groups were quite similar with regards to the recipient site. However, the ARAPF group of patients were significantly more satisfied with their donor sites. This is due to the fact that a significantly greater number of donor sites in the PIAF group required a skin grafting for resurfacing, while all the donor defects in the ARAPF group underwent direct closures. This is similar to the finding by Akdag et al who reported significantly better satisfaction with the adipofascial radial forearm flap group.³⁰

The limitation of this study is that it involved a limited number of patients in each group and carried out retrospectively. Further comparative studies involving a larger study population and carried out prospectively might provide a better insight.

CONCLUSION

However, from this study, we can conclude that both the posterior interosseous artery flap and the adipofascial radial artery perforator flap can be considered for soft tissue resurfacing of the hand defects in firecracker and homemade bomb blast injuries. Both have a reliable blood supply and spares major arteries of the hand. Both these regional flaps are attractive options in such injuries, thus avoiding the need for prolonged and meticulous free flap surgeries or multi-staged procedures involving distant pedicled flaps.

Funding: No funding sources

Conflict of interest: None declared

Ethical approval: The study was approved by the Institutional Ethics Committee

REFERENCES

1. Freitas AD, Pardini AG Jr, Tavares KE, Lima LAA. Pedicled antebrachial flaps to cover skin defects in the hand. Rev Bras Ortop. 1996;28(4):204-8.
2. Agir H, Sen C, Alagöz S, Onyedi M, Isil E. Distally based posterior interosseous flap: primary role in soft-tissue reconstruction of the hand. Ann Plast Surg. 2007;59(3):291-6.
3. Jabaley ME, Peterson HD. Early treatment of war wounds of the hand and forearm in Vietnam. Ann Surg. 1973;177:167-73.
4. US Naval Academy. Military explosives. Fundamentals of naval weapons systems. Federation of American Scientists website. Available at: <http://www.fas.org/man/dod->

- 101/navy/docs/fun/part12.htm. Accessed on 13 December 2011.
5. Hazani R, Buntic RF, Brooks D. Patterns in blast injuries to the hand. *Hand.* 2009;4(1):44-9.
 6. Adani R, Tarallo L, Marcoccio I, Fregni U. First web-space reconstruction by the anterolateral thigh flap. *J Hand Surg Am.* 2006;31(4):640-6.
 7. Zancolli EA, Angrigiani C. Posterior interosseous island forearm flap. *J Hand Surg Br.* 1988;13(2):130-5.
 8. Akyürek M, Safak T, Keçik A. Coverage of a thumb wound and correction of a first web space contracture using a longitudinally split reverse radial forearm flap. *Ann Plast Surg.* 2001;47(4):453-7.
 9. Foucher G, van Genechten F, Merle N, Michon J. A compound radial artery forearm flap in hand surgery: an original modification of the Chinese forearm flap. *Br J Plast Surg.* 1984;37(2):139-48.
 10. Sabapathy SR, Venkatramani H, Martin Playa P. The use of pedicled abdominal flaps for coverage of acute bilateral circumferential degloving injuries of the hand. *Trauma Case Rep.* 2015;1(3-4):25-31.
 11. Liu DX, Wang H, Li XD, Du SX. Three kinds of forearm flaps for hand skin defects: experience of 65 cases. *Arch Orthop Trauma Surg.* 2011;131(5):675-80.
 12. Campbell DA, Kay SP. The hand injury severity scoring system. *J Hand Surg Br.* 1996;21(3):295-8.
 13. Wang JQ, Cai QQ, Yao WT, Gao ST, Wang X, Zhang P. Reverse posterior interosseous artery flap for reconstruction of the wrist and hand after sarcoma resection. *Orthop Surg.* 2013;5(4):250-4.
 14. Onode E, Takamatsu K, Shintani K, Yokoi T, Uemura T. Anatomical origins of radial artery perforators evaluated using color Doppler ultrasonography. *J Reconstr Microsurg.* 2016;32:594-8.
 15. Saint-Cyr M, Mujadzic M, Wong C, Hatef D, Lajoie AS, Rohrich RJ. The radial artery pedicle perforator flap: vascular analysis and clinical implications. *Plast Reconstr Surg.* 2010;125:1469-78.
 16. Beaton DE, Katz JN, Fossel AH, Wright JG, Tarasuk V, Bombardier C. Measuring the whole or the parts? Validity, reliability, and responsiveness of the Disabilities of the Arm, Shoulder and Hand outcome measure in different regions of the upper extremity. *J Hand Ther.* 2001;14(2):128-46.
 17. Jones NF, Jarrahy R, Kaufman MR. Pedicled and free radial forearm flaps for reconstruction of the elbow, wrist, and hand. *Plast Reconstr Surg.* 2008;121(3):887-98.
 18. Soucacos PN, Beris AE, Xenakis TA, Malizos KN, Touliatis AS. Forearm flap in orthopaedic and hand surgery. *Microsurgery.* 1992;13(4):170-4.
 19. Lin SD, Lai CS, Chiu CC. Venous drainage in the reverse forearm flap. *Plast Reconstr Surg.* 1984;74(4):508-12.
 20. Yamakawa S, Hayashida K. Dorsal hand reconstruction with radial artery perforator-based adipofascial flap. *Plast Aesthet Res.* 2020;7:24.
 21. Chang SM. The distally based radial forearm fascia flap. *Plast Reconstr Surg.* 1990;85(1):150-1.
 22. Chang SM, Hou CL, Zhang F, Lineaweaver WC, Chen ZW, Gu YD. Distally based radial forearm flap with preservation of the radial artery: anatomic, experimental, and clinical studies. *Microsurgery.* 2003;23(4):328-37.
 23. Mahmoud WH. Radial forearm flap versus radial adipofascial perforator based flap for reconstruction of hand soft tissue defects. *Don J Med Med Sci.* 2015;2(3):19-25.
 24. Pilling T, Govender P. Profile and management of the firework-injured hand. *South Afr Fam Pract.* 2016;58(2):48-53.
 25. Matshidza, S, Golele, S, Mennen U. Firecracker injuries of the hand. *J Bone Joint Surg.* 2005;87(B):272.
 26. Al-Najjar OA, Arajy ZY, Jawdat AA. The Distally Based Radial Forearm Flap in Reconstruction of Complex Defects of the Hand. *Iraqi Postgrad Med J.* 2008;7(1).
 27. de Lima SJ, Domingos da Costa RP, de Oliveira E, Prudente FG, Mendonça MP, et al. Posterior Inyrbone artery flap for covering serious forearm, wrist and hand injuries. *Rev Bras Ortop.* 2015;44(1):40-5.
 28. Chang SM, Hou CL. The development of the distally based radial forearm flap in hand reconstruction with preservation of the radial artery. *Plast Reconstr Surg.* 2000;106(4):955-7.
 29. Ignatiadis IA, Giannoulis FS, Mavrogenis AF, Avram AM, Georgescu AV, Perez ML, et al. Ulnar and radial artery based perforator adipofascial flaps. *EEX OT.* 2008; 59(2):101-8.
 30. Akdağ O, Yıldırım G, Sütçü M, Karameşe M. Posterior interosseous flap versus reverse adipofascial radial forearm flap for soft tissue reconstruction of dorsal hand defects. *Ulus Travma Acil Cerrahi Derg.* 2018;24(1):43-48.
 31. Lu LJ, Gong X, Lu XM, Wang KL. The reverse posterior interosseous flap and its composite flap: experience with 201 flaps. *J Plast Reconstr Aesthet Surg.* 2007;60:876-82.
 32. Akinci M, Ay S, Kamiloglu S, Erçetin O. The reverse posterior interosseous flap: A solution for flap necrosis based on a review of 87 cases. *J Plast Reconstr Aesthet Surg.* 2006;59:148-52.
 33. Maamoun MI, Rizk IN, El Minawi HM, Moharram AN. Adipofascial perforator based reversed flow radial forearm flap for the reconstruction of hand defects. *Kasr El Aini J Surg.* 2007;8(1):55-62.
 34. Beaton DE, Katz JN, Fossel AH, Wright JG, Tarasuk V, Bombardier C. Measuring the whole or the parts? Validity, reliability, and responsiveness of the disabilities of the arm, shoulder and hand outcome measure in different regions of the upper extremity. *J Hand Ther.* 2001;14:128-46.

Cite this article as: Gupta M, Jash PK. The posterior interosseous artery flap versus the adipofascial radial artery perforator flap in reconstruction of firecracker and homemade bomb blast injuries of the hand. *Int Surg J* 2021;8:1118-23.