

Original Research Article

Octyl 2-cyanoacrylate versus conventional suturing of port site skin closure in laparoscopic appendicectomy: a prospective study

Swapnil Annasaheb Pattanshetti^{1*}, Abhijit S. Gogate²,
Vidya M. Mahalmani³, Kannikanti Nageswara Rao²

¹Department of Pediatric Surgery, JNMC, Belagavi, Karnataka, India

²Department of General Surgery, JNMC, Belagavi, Karnataka, India

³Department of Pharmacology, JNMC, Belagavi, Karnataka, India

Received: 11 February 2021

Revised: 27 February 2021

Accepted: 02 March 2021

*Correspondence:

Dr. Swapnil Annasaheb Pattanshetti,

E-mail: swapnilpattanshetti@gmail.com

Copyright: © the author(s), publisher and licensee Medip Academy. This is an open-access article distributed under the terms of the Creative Commons Attribution Non-Commercial License, which permits unrestricted non-commercial use, distribution, and reproduction in any medium, provided the original work is properly cited.

ABSTRACT

Background: With rapidly developing minimally invasive surgery, the laparoscopic appendectomy has become a preferred method for appendicectomy. Tissue adhesives have become an ideal alternative to conventional sutures and could possibly become the preferred standard of care in many procedures. However, this concept remains unexplored due to scanty data comparing the use of adhesive glues and sutures. The present prospective study was done to compare octyl-2-cyanoacrylate with conventional suturing of port site wound closure in laparoscopic appendicectomy in terms of wound complications, time taken for wound closure and cosmetic outcome.

Methods: 60 patients diagnosed to have appendicitis (acute, chronic and recurrent) undergoing laparoscopic appendicectomy were divided into two groups (group A-octyl-2-cyanoacrylate) and (group B- conventional sutures) with 30 in each group. Time taken for wound closure, Wound complications and cosmetic outcome were compared in both groups.

Results: Patient demographics were comparable in both the groups. The complications were significantly lower in group A compared to group B. Mean surgical time for wound closure in group A was less compared to group B ($p < 0.001$). Wound closure using octyl-2-cyanoacrylate had lower rate of complications compared to conventional suturing but results obtained were not statistically significant. No significant difference in cosmetic outcome was noted in both groups.

Conclusions: Wound closure using octyl-2-cyanoacrylate required significantly less time for skin closure compared to conventional suturing in patients undergoing laparoscopic appendicectomy. However, wound complications and cosmetic outcome using octyl-2-cyanoacrylate did not show statistically significant results compared to conventional suture.

Keywords: Laproscopic appendicectomy, Octyl-2-cyanoacrylate, Nylon non absorbable suture

INTRODUCTION

Acute appendicitis is the most common cause of an 'acute abdomen' in young adults. Appendectomy is one of the most commonly performed surgical procedures of the abdomen in the world. With rapidly developing,

minimally invasive surgery, the laparoscopic appendectomy has become a selectable method for appendectomy. Previous studies have reported that laparoscopic appendectomy has many advantages in comparison to open appendectomy, such as shorter hospital stays, reduced risks of complications, and better

cosmetic satisfaction.¹ Therefore, the laparoscopic appendectomy, like laparoscopic cholecystectomy, is considered to be a favorable procedure for appendectomy present and future.² Sutures have conventionally been the method of approximating wound edges due to their high tensile strength and favorable cosmetic outcomes. Sutures do, however, have some downfalls in that they require increased time and a skilled individual to accomplish good cosmetic outcomes. Adhesive glues are most recent and advanced method available for closing surgical skin incisions. Tissue adhesive, octyl-2-cyanoacrylate (OCA) ('Dermabond') does not require a skilled person to apply, nor does it cause pain that requires anesthesia as with the suturing technique. Therefore, it can be applied in a much quicker manner and not cause any additional pain or anxiety to the patient.³ With these advantages and with continued improvement, tissue adhesives have become an ideal alternative to conventional sutures and could possibly become the preferred standard of care in many procedures. However, this concept remains unexplored due to scanty data comparing the use of adhesive glues and sutures. This prompted us to compare octyl-2-cyanoacrylate with conventional suturing of port site wound closure in laparoscopic appendectomy in terms of wound complications, time taken for wound closure and cosmetic outcome.

METHODS

This prospective randomized controlled trial was conducted between January 2013 to December 2013 at department of general surgery, KLES Dr. Prabhakar Kore hospital and medical research centre, Belagavi. Patients diagnosed to have appendicitis (Acute, chronic and recurrent) undergoing laparoscopic appendectomy were evaluated. Considering as pilot study, the sample size was planned for a total of 60 patients were randomized by "opaque envelope method" into two groups of 30 each where group A-Patients underwent port site wound closure with octyl 2- cyanoacrylate and group B-Patients underwent port site wound closure with non-absorbable sutures i.e., Ethilon 3-0. Figure 1-3 shows octyl-2-cyanoacrylate (OCA) ('Dermabond') and its method of application respectively. The inclusion and exclusion criteria are summarized in Table 1.

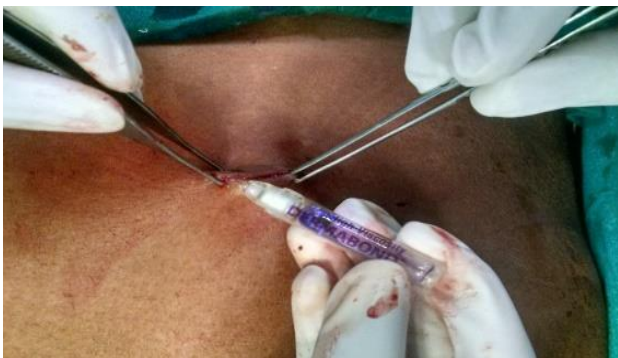

Figure 1: Method of application.

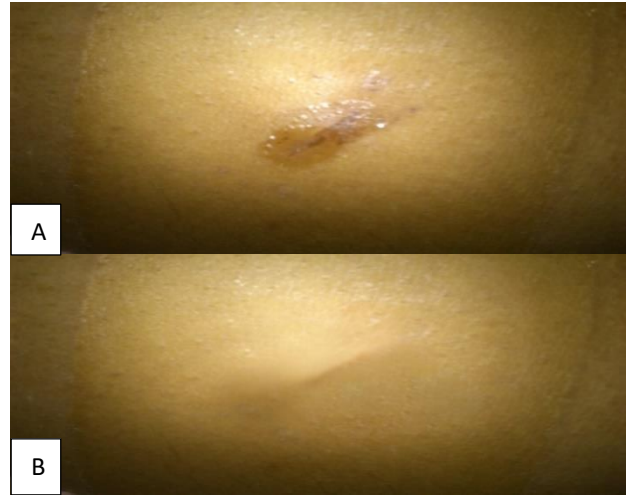

Figure 2: (A) Wound appearance on post-operative day 7 in group A. (B) Wound appearance on post-operative three months in group A.

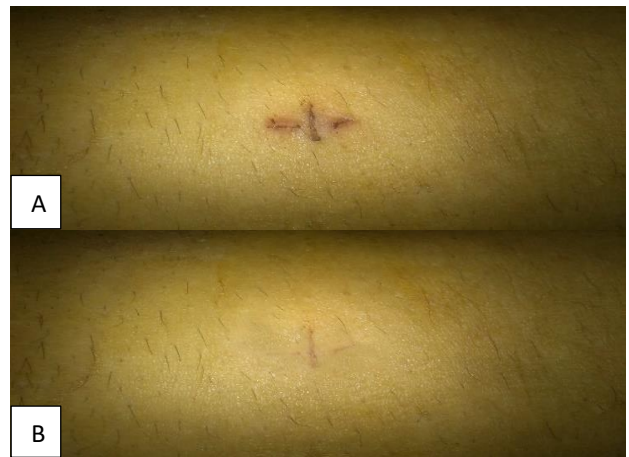

Figure 3: (A) Wound appearance on post-operative day 7 in group B. (B) Wound appearance on post-operative three months in group B.

Table 1: Selection criteria.

Inclusion criteria	Exclusion criteria
Patients diagnosed to have appendicitis and undergoing laparoscopic appendectomy.	Diabetes mellitus or immunodeficiency.
Patients with age between 16 to 60 years.	Pre-existing systemic/local infection.
-	Patients with appendicular abscess, gangrenous appendicitis, appendicular mass.
-	Patients with perforation, peritonitis and/or other apparent foci of active abdominal infection.
-	A known allergy to cyanoacrylate compound.

Demographic data and routine biochemical parameters were collected for all the patients included in the trial. The investigations done before operating the patient are summarized in Table 2. Patients in both the groups underwent similar surgery that is laparoscopic appendectomy. Patients in group A underwent port site wound closure with octyl 2-cyanoacrylate. Patients in group B underwent port site wound closure- mattress sutures with non-absorbable suture i.e., Ethilon 3-0. The wound was assessed for any complications on 3rd, 5th and 7th post-operative day, first and third month for cosmetic outcome. Discharge/pus from the wound, if any, was sent for culture and sensitivity. Intraoperatively both the groups were assessed in terms of time taken for the wound closure of all ports. Postoperatively, patients in both the groups were evaluated for wound in terms of erythema, warmth, tenderness, discharge and infection. Each patient was followed up until discharge post operatively and followed on out-patient department basis after discharge. The wound was assessed for cosmesis on seventh post-operative day and at the end of first and third month using modified Hollander cosmesis scale.⁴ The total score was calculated and wounds with a score of six were considered to have an optimal cosmetic appearance and others suboptimal appearance.

Statistical analysis

The data obtained was coded and entered in Microsoft excel spreadsheet. The categorical data was expressed as rates, ratios and percentages and comparison was done using chi-square test and Fisher's exact test. Continuous data was expressed as mean \pm standard deviation and the independent sample 't' test was used for comparison. A 'p' value of less than or equal to 0.05 at 95% confidence interval was considered as statistically significant.

RESULTS

A total of 60 patients undergoing laparoscopic appendectomy over a period one year from January 2013 to December 2013 were studied.

Sex distribution

In the present study 66.67% in group A and 50% in group B were males. The male to female ratio was found to be 2:1 in group A and 1:1 in group B. However, the sex distribution in group A and B was comparable ($p=0.190$).

Table 2: Clinical presentation.

Presentation	Findings	Group A (n=30)		Group B (n=30)		P value
		No	%	No	%	
Pain	Present	30	100.00	30	100.00	-
	Absent	0	0.00	0	0.00	
	Total	30	100.00	30	100.00	
Nausea	Present	18	60.00	13	43.33	0.196
	Absent	12	40.00	17	56.67	
	Total	30	100.00	30	100.00	
Fever	Present	12	40.00	15	50.00	0.436
	Absent	18	60.00	15	50.00	
	Total	30	100.00	30	100.00	
Vomiting	Present	14	46.67	14	46.67	1.000
	Absent	16	53.33	16	53.33	
	Total	30	100.00	30	100.00	
Anorexia	Present	11	36.67	14	46.67	0.432
	Absent	19	63.33	16	53.33	
	Total	30	100.00	30	100.00	
Tenderness	Present	30	100.00	30	100.00	-
	Absent	0	0.00	0	0.00	
	Total	30	100.00	30	100.00	
Rebound tenderness	Present	1	3.33	2	6.67	0.500
	Absent	29	96.67	28	93.33	
	Total	30	100.00	30	100.00	

Age distribution

Most of the patients presented with age less than 30 years that is 70% in group A and 63.33% in group B. However, this difference was statistically not significant ($p=0.300$).

Mean age

In the present study the mean age of the study population in group A was slightly low (26.96 ± 6.80 years) compared to group B (30.30 ± 9.69 years). However, the difference was statistically not significant ($p=0.129$).

Pulse rate

Mean pulse rate/minute in group A (91.63±8.33) and B (91.06±10.24). It was observed that the mean pulse rate was comparable in both the groups (p=0.815).

Clinical presentation

Table 2 represents clinical presentation of patients in both groups. Data was comparable in group A and B (p>0.050).

Temperature

46.67% of the patients in group A and 43.33% in group B were febrile (p=0.795).

Mean surgical time for wound closure

Mean surgical time for closure of the wound in group A was significantly less compared to group B (123.30±22.46 vs 186.90±21.49 seconds; p<0.001). Table 3 represents Mean surgical time for wound closure.

Table 3: Mean surgical time for wound closure in both groups.

Variables	Group A (n=30)		Group B (n=30)		P value
	Mean	SD	Mean	SD	
Surgical time (sec)	123.3	22.4	186.9	21.4	<0.001

Rate of complications on post-operative day three

In the present study 6.67% of the patients in group A and 13.33% in group B had complication on post-operative day three. However, the difference was statistically not significant (p=0.335).

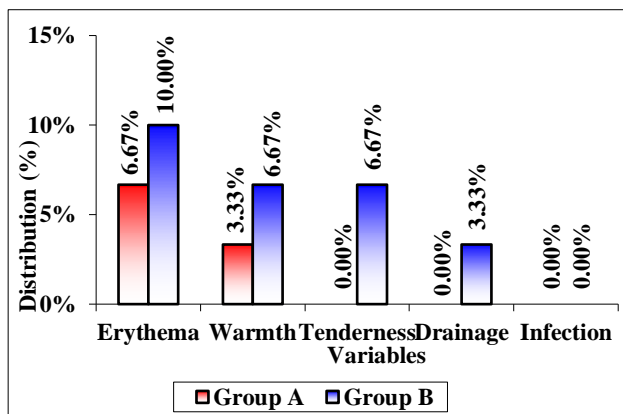


Figure 4: Complications encountered at the end of post operative day three.

Figure 4 represents various complications encountered on postoperative day three. However, complications

including erythema, warmth, tenderness, drainage and infections were comparable in group A and B (p>0.050).

Rate of complications at the end of post-operative day five

In this study 3.33% of the patients in group A had complications on day five follow up compared to 13.33% in group B. However, the difference was statistically not significant (p=0.177).

Figure 5 represents various complications encountered on postoperative day five. The complications of drainage were noted among 3.33% of the patients in group A compared 13.33% in group B. However, complications including tenderness and drainage were comparable in group A and B (p>0.050).

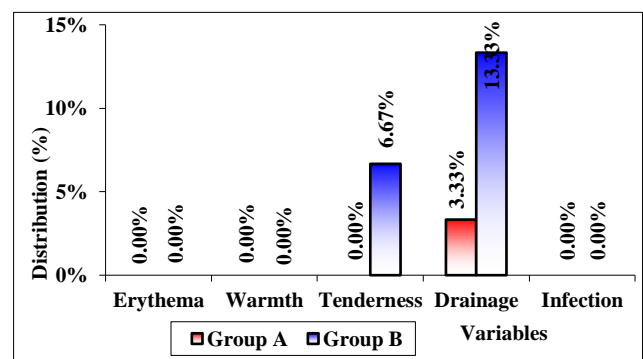


Figure 5: Complications encountered at the end of post-operative day five.

Rate of complications at the end of post-operative one week

In the present study, in group A, 3.33% of the patients had complications at the end of one week follow up compared to 6.67% in group B. However, this difference was statistically not significant (p=0.500).

Figure 6 represents complications encountered at the end of post-operative one week.

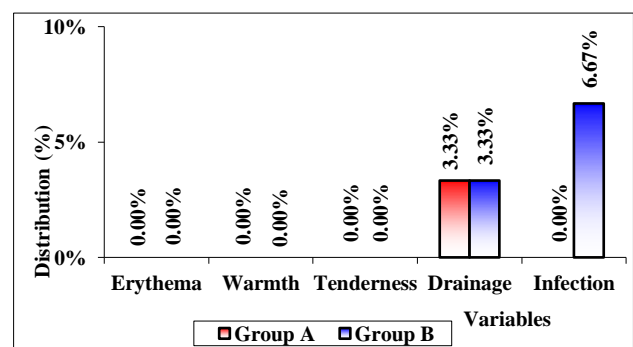


Figure 6: Complications encountered at the end of post-operative one week.

Drainage was noted among 3.33% of the patients each in group A and group B and infection was present in 6.67% of the patients in group B only and culture was positive.

The organism isolated was staphylococcus aureus in 6.67% of the patients. However, complications including drainage and infections were comparable in group A and B (p>0.050).

Modified Hollander cosmesis scale which has six clinical variables as step off borders, edge inversion, contour irregularities, excess inflammation, wound margin separation and good overall appearance.⁴ Wound was assigned 0 or 1 point each for the presence or absence of:

Step off the borders, (0 for yes, 1 for no), Contour irregularities- puckering, (0 for yes, 1 for no), Wound margin separation, (0 for yes, 1 for no), Wound edge inversion, (0 for yes, 1 for no), Excessive wound distortion, (0 for yes, 1 for no) and Good overall appearance (0 for poor, 1 for acceptable).

The total score was calculated and wounds with a score of six were considered to have an optimal cosmetic appearance and others suboptimal appearance. Hollander cosmesis score was optimal (score of 6) in majority of the patients with group A as well as group B at all the follow ups (p>0.050).

Table 4: Hollander cosmesis score.

Interval	Findings	Group A (n=30)		Group B (n=30)		P value
		No	%	No	%	
Day seven	Optimal (score 6)	25	73.33	22	83.33	0.365
	Suboptimal (<6)	5	26.67	2	16.67	
	Total	30	100.00	30	100.00	
One month	Optimal (score 6)	27	80.00	24	93.33	0.278
	Suboptimal (<6)	3	20.00	6	6.67	
	Total	30	100.00	30	100.00	
Three months	Optimal (score 6)	28	90.00	25	83.33	0.228
	Suboptimal (<6)	2	10.00	5	16.67	
	Total	30	100.00	30	100.00	

DISCUSSION

Since the evolution of medicine, great strides have been taken in the field of advanced and minimal access surgeries. Diagnostic or operative laparoscopy as a minimally invasive procedure is one of the most common operations in general surgery. The benefits of minimally invasive surgery as opposed to the traditional open surgical approach are reduced pain, quicker return of oral intake, shorter hospitalization, and improved cosmetic results due to decreased scarring. There are several methods for skin closure of trocar wound. In past the surgical skin incisions were closed using sutures, and then came the staples and adhesive tapes. Recently since 1949, skin adhesive glues are also available. With so many methods available for skin closure and each one of the methods having their own advantages and disadvantages, it becomes imperative to know which methods are better in what circumstances. Closing surgical skin incision using adhesives glues is the most recent and advanced method. However, there is scarcity of data regarding the surgical time, wound complications and cosmetic results in comparison to sutures. Hence the present study was undertaken to compare octyl-2-cyanoacrylate with conventional suturing of port site wound closure in laparoscopic appendectomy in terms of wound complications, time taken for wound closure and cosmetic outcome.

Though male preponderance was noted in group A 66.67% (male to female ratio 2:1) while in group B equal number of patients were males and females (50% each; male to female ratio 1:1), sex distribution in both groups was comparable (p=0.190). we also encountered majority of patients with younger age, 70% of the patients in group A and 63.33% in group B presented with age less than 30 years. The mean age of patients in group A was slightly low (26.96±6.80 years) compared to group B (30.30±9.69 years). However, the age distribution and mean age in group A and B were comparable (p>0.050). all the patients presented with pain and tenderness in both the groups (100%). The next common complaint in group A was nausea (60%), vomiting (46.67%), fever (40%), anorexia (36.67%) and rebound tenderness (3.33%). In group B, group B common complaints were noted as fever (50%), vomiting (46.67%), anorexia (46.67%) nausea (43.33%) and rebound tenderness (6.67%). However, the difference was statistically not significant (p>0.050). Overall, the above findings suggest that the demographic characteristics and clinical presentation pattern of the study population was comparable in group A and B (p>0.050).

Mean surgical time for wound closure in group A was 123.30±22.46 seconds compared to 186.90±21.49

seconds in group B ($p < 0.001$). These findings suggest that, port site wound closure using octyl-2-cyanoacrylate results in significantly lower surgical time compared to conventional suturing in patients undergoing laparoscopic appendectomy. These findings were consistent with several other studies. In one of the first published studies evaluating octylcyanoarylate, Quinn et al performed a prospective randomized controlled trial comparing octyl cyanoarylate and sutures.⁵ One hundred and thirty patients were enrolled. Use of the skin adhesive was found to be significantly faster in this setting (220 seconds versus 744 seconds; $p < 0.001$). Similar observations were reported in a study by Matin et al that is, the mean time taken for skin closure in adhesive glue group was faster than skin suturing group (150 seconds versus 360 seconds).⁶ Torumi et al took 55 seconds for closure of lacerations with glue and 235 seconds sutures with difference being significant ($p < 0.0001$).⁷ Bruns et al conducted a trial for closure of lacerations in children's emergency department in 1995 and concluded that there was significant time difference between glue application and suturing with glue needing lesser time for closure.⁸ The findings of the present study were consistent with these results though these studies were not conducted in the settings of laparoscopic appendectomy. Further the wide variation in the meantime would be explained by the different settings studied by the different authors. In the present study no statistically, significant difference was observed with regard to complications between group A and group B on post-operative day three (6.67 vs 13.33%; $p = 0.335$) day five (3.33 vs 13.33%; $p = 0.177$) and at one week (3.33 vs 6.67%; $p = 0.500$). These findings suggest that wound closure using octyl-2-cyanoacrylate has lower rate of complications compared to conventional suturing in patients undergoing laparoscopic appendectomy but not statistically. complications encountered at post-operative follow up day 1, 5 and 7 i.e., rate of erythema, warmth, tenderness, drainage and infection were less in group A. However, the results were comparable in both the groups at all the follow ups. These findings suggest that, the possible complications using octyl-2-cyanoacrylate are less likely to be seen compared to conventional sutures. It is known that cyanoacrylate glue has antibacterial properties. Quinn et al has shown the antibacterial property of glue in a contaminated wound model.⁵ The exact mechanism of antibacterial property is not known, but it is likely to be a cell wall mechanism because the sensitivities are restricted to gram positive organisms. Gram negative organisms are relatively less affected. Toruimi et al did not find any evidence of gaping in both groups of glue and sutures for laceration repair.⁷

In the present study Hollander cosmesis score showed optimal (score of 6) scorer in majority of the patients with group A as well as group B at all the follow ups ($p > 0.050$). These findings were in agreement with a study by Jallali et al where authors compared the wound with Modified Hollander cosmesis scale and showed no

significant difference in cosmesis.^{7,8,10,11} Overall the results from the present study show that skin closure by adhesive glue, octyl cyanoacrylate is better than traditional skin suturing method. The concept of a surgical tissue adhesive for superficial skin closure is an attractive alternative to the use of sutures for both surgeons and patients in terms of reduced surgical time for skin closure there by resulting in a shorter operative time, forms a flexible, water resistant, sealed skin closure, faster, comfortable and cosmetically best technique for skin closure, and is easier to use. Further, the watertight barrier formed by octyl cyanoacrylate allows patient to shower any time after surgery, no stitches to be removed and no need to apply bandages. Cosmetic benefits include that the glue disappears naturally as incision heals and leaves no mark resulting in better cosmetic outcome. Octyl cyanoacrylate is non-irritating to skin and side effects are extremely less. Hence it can be used in surgical skin closure for the patients undergoing laparoscopic appendectomy.

CONCLUSION

The present study showed that, wound closure using octyl-2-cyanoacrylate requires significantly less time for skin closure and results in shorter operative time compared to with conventional suturing in patients undergoing laparoscopic appendectomy. However, the wound complications and cosmetic outcome using octyl-2-cyanoacrylate were comparable with conventional suture.

Funding: No funding sources

Conflict of interest: None declared

Ethical approval: The study was approved by the Institutional Ethics Committee

REFERENCES

1. Sauerland S, Jaschinski T, Neugebauer EA. Laparoscopic versus open surgery for suspected appendicitis. *Cochrane Database Syst Rev.* 2010;(10):CD001546.
2. Cai YL, Xiong XE, Wu SJ, Cheng Y, Lu J, Zhang J et al. Single-incision laparoscopic appendectomy vs conventional laparoscopic appendectomy: Systematic review and meta-analysis. *World J Gastroenterol.* 2013;19(31):5165-73.
3. Chen K, Klapper AS, Voige H, Del Priore G. A randomized, controlled study comparing two standardized closure methods of laparoscopic port sites. *JSLs.* 2010;14(3):391-4.
4. Hollander JE, Singer AJ, Valentine S, Henry MC. Wound Registry: Development and Validation. *Ann Emerg Med.* 1995;25(5):675-84.
5. Quinn J, Wells G, Sutcliffe T, Jarmuske M, Maw J, Stiell I et al, A randomized trial comparing octylcyanoacrylate tissue adhesive and sutures in the management of lacerations. *JAMA.* 1997;277:1527-30.

6. Matin SF. Prospective Randomized Trial of Skin Adhesive versus Sutures for closure of 217 laparoscopic port-site incisions. *J Am Coll Surgeons*. 2003;196(6):845-53.
7. Toriumi DM, O'Grady K, Desai D, Bagal A. Use of Octyl-2-Cyanoacrylate for skin closure in facial plastic surgery. *Plastic Reconstructive Surg*. 1998;102(6):2209-19.
8. Bruns TB, Simon H, Mclario D. Laceration repair using a tissue adhesive in the children emergency Department. *Paediatrics*. 1996;98;673-75.
9. Quinn J, Wells G, Sutcliffe T, Jarmuske M, Maw J, Stiell I et al, A randomized trial comparing octylcyanoacrylate tissue adhesive and sutures in the management of lacerations. *JAMA*. 1997;277:1527-30.
10. Jallali N, Haji A, Watson CJ. A prospective randomized trial comparing 2-octyl cyanoacrylate to conventional suturing in closure of laparoscopic cholecystectomy incisions. *J Laparoendoscopic Adv Surg Tech Part A*. 2004;14(4):209-11.
11. Quinn J, Wells G, Sutcliffe T, Jarmuske M, Maw J, Stiell I et al. Tissue adhesive versus suture wound repair at 1 year: randomized clinical trial correlating early, 3-month, and 1-year cosmetic outcome. *Ann Emergency Med*. 1998;32(6):645-9.

Cite this article as: Pattanshetti SA, Gogate AS, Mahalmani VM, Rao KN. Octyl 2- cyanoacrylate versus conventional suturing of port site skin closure in laparoscopic appendicectomy: a prospective study. *Int Surg J* 2021;8:1094-100.