

Case Report

XY female with complete androgen insensitivity syndrome with bilateral inguinal hernia

Aafrin Shabbir Baldiwala*, Vipul C. Lad

Department of General Surgery, SMIMER, Surat, Gujarat, India

Received: 05 February 2021

Revised: 11 March 2021

Accepted: 18 March 2021

*Correspondence:

Dr. Aafrin S. Baldiwala,

E-mail: aafreenbaldiwala@gmail.com

Copyright: © the author(s), publisher and licensee Medip Academy. This is an open-access article distributed under the terms of the Creative Commons Attribution Non-Commercial License, which permits unrestricted non-commercial use, distribution, and reproduction in any medium, provided the original work is properly cited.

ABSTRACT

The complete androgen insensitivity syndrome (AIS), previously called testicular feminization syndrome, is an X-linked recessive rare disorder. AIS is the most common male pseudohermaphrodite. Patient has 46, XY chromosome and testis. The individual is phenotypically female and genotypically male. Antimüllerian hormone is produced by the testis. So, uterus and fallopian tubes do not develop in fetus. The fault lies with androgen receptors which are mutated. Male differentiation of external genitals does not occur. The individuals are reared as girls and the condition is suspected when the individual is evaluated for primary amenorrhea, infertility or when unilateral/bilateral inguinal hernia is diagnosed in girls. This disorder includes a spectrum of changes ranging from male infertility to completely normal female external genitalia in a chromosomally male individual. These cases need proper diagnosis and appropriate management. We report this case for its interesting presentation. The patient is a 23 year old female, presented with bilateral labial swellings and primary amenorrhoea. Subsequent investigations were done which revealed that the patient is a genetically male with absence of female internal genitalia but presence of testes. Proper psychological support was also given to her, which is more important.

Keywords: Complete androgen insensitivity syndrome, Female phenotype, Inguinal hernia, 46 XY karyotype

INTRODUCTION

Androgen insensitivity syndrome (AIS), formerly known as testicular feminization syndrome, is an X-linked recessive condition resulting in a failure of normal masculinization of the external genitalia in chromosomally male individuals. It depends on an X-linked mutation in the androgen receptor gene that expresses a variety of phenotypes ranging from male infertility to completely normal female external genitalia. The clinical phenotypes of AIS could vary and be classified into three categories, as complete androgen insensitivity syndrome, partial androgen insensitivity syndrome, and mild androgen insensitivity syndrome, according to the severity of androgen resistance.¹ Data are currently not available on the specific incidence of

androgen insensitivity syndrome in Asian region. Patients with complete androgen insensitivity syndrome are phenotypically normal women and have a risk of developing gonadal malignancy.² Most of the patients are identified in the newborn period by the presence of inguinal masses. But others also present in late adolescent with primary amenorrhoea in addition to inguinal masses. Here we describe a case of CAIS in a 23 year old female. The reason of presenting this case is to make the clinicians aware about this important and interesting clinical entity.

CASE REPORT

A 23 year old female presented to the surgical OPD with complaints of swelling in the groin on right side for the

past 2 years. The swelling was small in size and gradually it increased in its size. The swelling increased on coughing, straining and reduced on lying down. There was no history suggestive of obstruction/irreducibility. She had not attained menarche. She is unmarried and is having one sibling – her sister who is elder 1 year and is having normal menarche. On examination, she was a tall, well-built, and well-nourished female. Her details were as follows: height - 167 cm; weight - 59 kg; arm span - 165 cm; thyroid - normal; secondary sexual character - axillary hair and pubic hair sparse; breasts were developed. The abdomen was soft. The external genitalia were female (Figure 1 and 2). The inguinal region on the right and left side showed pyriform non-tender swellings of 5×4 cm² and 3×2 cm² respectively, descending till the upper part of the labia majora. The swellings were felt above and medial to the pubic tubercle and the cough impulse was present. Thus clinically, bilateral inguinal hernia was diagnosed. The sonography showed absent uterus and ovaries, 2.3 cm sized defect in right inguinal region and 1.0 cm defect in left inguinal region suggestive of bilateral inguinal hernia. Prostate size of 12 cc. The abdominal organs were normal. Laparoscopy confirmed the absence of the uterus and ovaries. The chromosomal analysis, GTG banded karyotyping showed 46 XY pattern. The blood investigations found the following: Serum Testosterone - 1.7 ng/ml (male range 1.8–9.0 ng/ml, female 0.2–1.2 ng/ml); LH - 24.2 m IU/ml (male age 20-70 years 1.5–9.3 m IU/ml, more than 70 years 1.3–34.6 m IU/ml); FSH - 5.2 m IU/ml (male 1.4–18.1 m IU/ml). All the blood tests were of the male range and in accordance with CAIS. After counselling, the patient was posted for surgery: bilateral transabdominal preperitoneal repair. Intraoperatively, the contents of the sac were omentum (Figure 3 and 4). The postoperative period was uneventful. The patient was discharged on the third day.

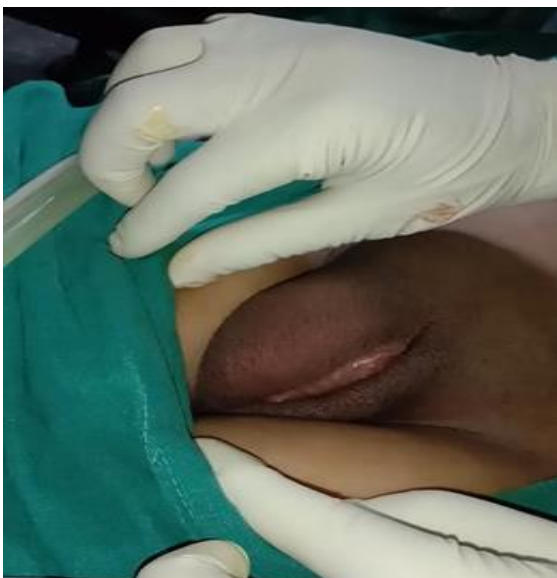

Figure 1: Female external genitalia.

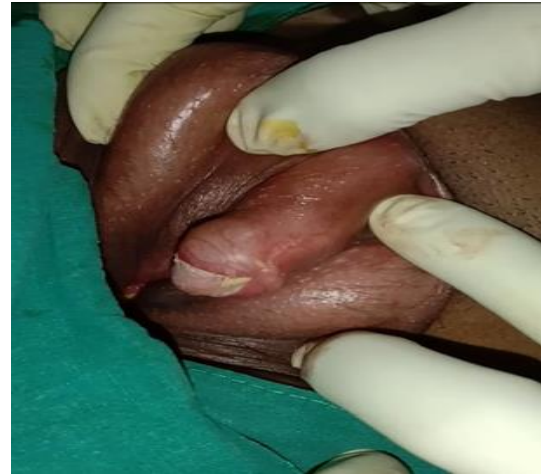

Figure 2: Mons pubis.

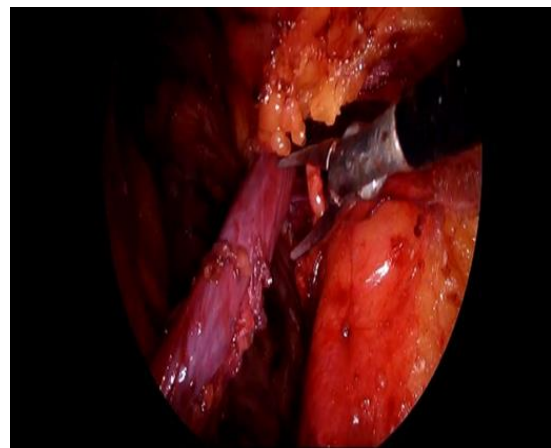


Figure 3: Right sided hernial sac.

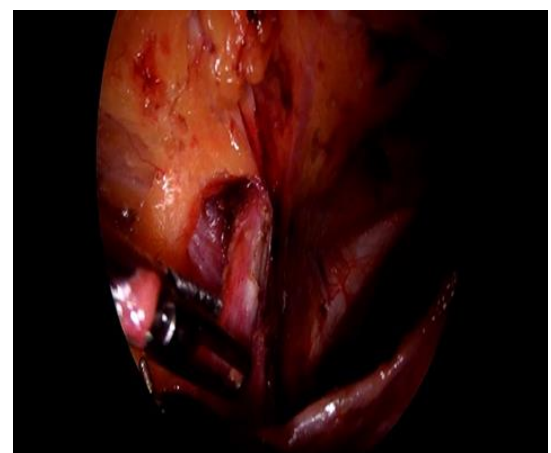


Figure 4: Left sided hernial sac.

DISCUSSION

Androgen insensitivity syndrome is a rare disorder with an incidence of 1 in 20,000–99,000.¹ It accounts for approximately 10% of cases of primary amenorrhea, ranking third after gonadal dysgenesis and the congenital

absence of the vagina. AIS is a disorder of androgen receptor function and represents the most common detectable cause of male pseudohermaphroditism.² In CAIS, the typical mode of presentation is an adolescent female who has breast development with pubertal growth but with no menarche and absence or scanty growth of pubic and axillary hair. CAIS may also be present in early childhood with the appearance of bilateral inguinal or labial swellings. The basic etiology is the loss of function - mutation in the androgen receptor gene. The affected individuals have 46 XY karyotype, normal testes, normal production of testosterone, normal conversion to dihydrotestosterone, and a normal amount of anti-mullerian hormone. Thus, the uterus, cervix, fallopian tubes and proximal vagina do not develop. The lower 1/3 of vagina develops as it originates from the urogenital sinus and presents as a blind vaginal pouch. The breasts are well developed due to conversion of testosterone to estradiol. The testes may be located anywhere along the path of embryonic testicular descent in the abdomen, inguinal canal, or labia. About 80–90% of individuals with CAIS develop inguinal hernia. The testes in CAIS individuals cause pubertal feminization. Some studies have shown carcinomatous changes in the testes of the children of CAIS in the age group of 13–14 years and it is believed that testicular biopsy warranted as soon as the syndrome is diagnosed. Though inguinal hernia is uncommon presentation in female, but they are well known presentation in AIS. It is suggested that female presenting with inguinal hernia should be karyotyped. A few studies using retrospective analysis estimated the incidence of AIS in girls with inguinal hernias to be 0.8% to 2.4%. The risk of germ cell malignancy is relatively high in these patients, increasing with age. The incidence (dysgerminoma, gonadoblastoma) is as low as 0.8% in CAIS and 5.5% in AIS. Overall risk of malignancy increases markedly after puberty and reaches 33% by the age of 50 years.³ Gonadectomy is recommended after post pubertal period to help development of feminization during puberty. Malignant changes in the germ cells are relatively late.⁴ Gonads may lie anywhere in the path of congenital descent. They are usually associated with inguinal hernia in 50% of patients. Hernioplasty should be undertaken to prevent future obstructed hernia.⁵ Laparoscopic approach to gonadectomy is an excellent minimally invasive technique. It provides good visualization of internal genitalia, and even small gonads and mullerian structures can be removed. Postoperatively, recovery is rapid with minimal discomfort to patient affording early mobilization. Gonadectomy predisposes patients to osteoporosis and other menopausal symptoms, therefore hormonal replacement therapy (HRT) is prescribed till the natural age of menopause to prevent the associated accelerated aging process of the whole body.⁶ Many patients require emotional and psychological support to resolve psychosexual identity issues raised by the diagnosis of androgen insensitivity syndrome. There is

need for emphasis on openness in disclosure to both patient and the family.

Limitation of the study

It is a single centre, single surgeon performed study so no control groups available for comparison and the result is totally based on the outcomes and performance of the patients in regular follow ups.

CONCLUSION

Androgen insensitivity syndrome is distressing to the patient as well as to the family. In this case, CAIS was diagnosed on the basis of history of primary amenorrhoea and clinical gynecologic examination. Patient was diagnosed with bilateral inguinal hernia which was treated by transabdominal preperitoneal repair (TAPP). There are increasing number of cases of female having inguinal hernia who are being diagnosed with CAIS. So, more and more karyotyping is needed and repair of hernia should be done with proper psychological support and counseling of female patient and her family.

Funding: No funding sources

Conflict of interest: None declared

Ethical approval: Not required

REFERENCES

1. National Center for Biotechnology Information. US National Library of Medicine, 2007. Available at <http://www.ncbi.nlm.nih.gov/books/NBK1429/>. Accessed on 17 September 2014.
2. Ohba K, Hayashida Y, Hakariya H, Ichinose S, Naitou S. Case of complete androgen insensitivity syndrome. *Hinyokika Kyo*. 2009;55(5):277-80.
3. Oakes MB, Eyvazzadeh AD, Quint E, Smith YR. Complete androgen insensitivity syndrome-a review. *J Pediatr Adolesc Gynecol*. 2008;21(6):305–10.
4. Sharma S, Balwan WK, Kumar P, Gupta S. Androgen Insensitivity Syndrome (Testicular Feminization). *J Obstet Gynaecol India*. 2012;62(2):199-201.
5. Papanastasopoulos P, Panagidis A, Verras D, Repanti M, Georgiou G. A case of complete androgen insensitivity syndrome presenting with incarcerated inguinal hernia: an immunohistochemical study. *Fertil Steril*. 2009;92(3):11-4.
6. Cools M, Drop SLS, Wolffenbuttel KP, Oosterhuis JW, Looijenga LHJ. Germ cell tumors in intersex gonad: old paths, new direction, moving frontiers. *Endocr Rev*. 2006;27(5):468-84.

Cite this article as: Baldiwala AS, Lad VC. XY female with complete androgen insensitivity syndrome with bilateral inguinal hernia. *Int Surg J* 2021;8:1353-5.