

## Case Report

# Treatment of a duodenal perforation after mucosectomy: case report and literature review

João Simões<sup>1,2\*</sup>, Catarina Melo<sup>1</sup>, Cristina Camacho<sup>1,2</sup>, Emília Fraga<sup>1</sup>, António Bernardes<sup>1-3</sup>

<sup>1</sup>General Surgery Department, Centro Hospitalar e Universitário de Coimbra, Coimbra, Portugal

<sup>2</sup>Faculty of Medicine, University of Coimbra, Coimbra, Portugal

<sup>3</sup>General Surgery Department, Oesophago-Gastric and Obesity Unit, Centro Hospitalar e Universitário de Coimbra, Coimbra, Portugal

**Received:** 02 February 2021

**Revised:** 10 March 2021

**Accepted:** 16 March 2021

### \*Correspondence:

Dr. João Simões,

E-mail: joaomsimoes1@gmail.com

**Copyright:** © the author(s), publisher and licensee Medip Academy. This is an open-access article distributed under the terms of the Creative Commons Attribution Non-Commercial License, which permits unrestricted non-commercial use, distribution, and reproduction in any medium, provided the original work is properly cited.

## ABSTRACT

Duodenal neuroendocrine tumors are rare. Its incidence is increasing due to access to upper gastrointestinal endoscopy. In early stages, endoscopic submucosal dissection is a valid approach. However, endoscopic procedures of duodenum have high risk of complications due to its particularly anatomic configuration. Perforation of duodenum is a complication from endoscopic submucosal dissection, and it is a diagnostic challenge. Abdominal computed tomography with oral contrast is the best exam to diagnose duodenum perforation. Late perforation can present with fever and tachycardia, without abdominal pain or tenderness. There is not an optimal or standard management of duodenal perforation. Medical treatment, endoscopic procedures, percutaneous drainage, or surgical approaches can be possible and valid. The patient state, anatomy and localization of perforation and surgeon experience need to be factors to have in count. The authors present a case of a large duodenal perforation after endoscopic submucosal dissection with subhepatic abscess, managed with surgical approach, performing an antrectomy with Y-en-Roux gastrojejunostomy and duodenostomy with a Pezzer tube. The patient started oral feeding on fifth day post-operative, and performed a fistulography on twentieth day post-operative, without contrast leak. Discharged occurred on post-operative day 41 without main complications. The Pezzer tube was removed four months after surgery, and one month later the abdominal wound where Pezzer tube was, closed.

**Keywords:** Duodenal perforation, Neuroendocrine tumour, Emergency surgery, duodenostomy, Endoscopic mucosectomy

## INTRODUCTION

Neuroendocrine tumors (NETs) are epithelial neoplasms with predominant neuroendocrine differentiation.<sup>1</sup> According to WHO classification, they can be divided into well-differentiated (G1, G2) or poorly differentiated (G3), depending on histopathological features.<sup>2</sup> Duodenal neuroendocrine tumors represent 5-20% of all gastrointestinal NETs.<sup>1</sup> Their incidence is increasing due to easier access to diagnostic methods, like upper gastrointestinal (GI) endoscopy.<sup>2-5</sup> Most duodenal NETs

are found incidentally during upper GI endoscopic examination. The majority of them are well-differentiated tumors and are located in the first and second portions of the duodenum.<sup>2,3</sup>

Endoscopic resection is a treatment option for superficial tumors of the GI tract.<sup>4</sup> Endoscopic submucosal dissection (ESD) is a minimally invasive approach to treat early duodenal neoplasms, such as NETs, especially those confined to the submucosal layer and measuring up to 1cm in diameter.<sup>2,6</sup> However, due to its particular anatomy,

endoscopic treatment procedures in the duodenum can be technically difficult and may not achieve successful results.<sup>6</sup>

Perforation and bleeding are two dangerous complications of ESD.<sup>2</sup> Duodenal perforation can immediately recognized, during the procedure, or it can only be detected latter. Delayed perforation is a diagnostic challenge. The patient may present tachycardia, fever, raise in inflammatory parameters in blood tests. Abdominal pain with rebound tenderness may not be present.<sup>4,6</sup> CT scan with intravenous and oral contrast is the method with more sensitivity and specificity to diagnosis duodenal perforation.<sup>4</sup>

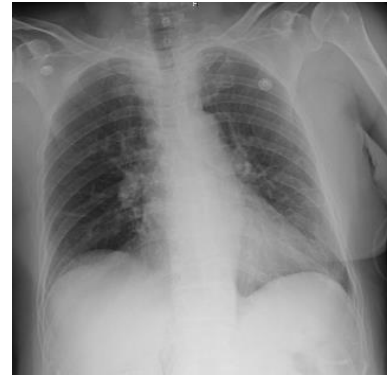Optimal treatment is controversial, and diagnosis is often delayed, increasing mortality rate from 8 to 25%.<sup>7</sup> Also, this condition is associated to prolonged hospitalization periods and significantly increases in medical care costs.<sup>8</sup> Conservative management, percutaneous drainage of intra-abdominal collections and surgical management are the main treatment to duodenal perforations.

The authors describe a clinical case of surgical management of a patient that with perforation of the duodenum, after performing a endoscopic submucosal dissection for a duodenal NET.

### CASE REPORT

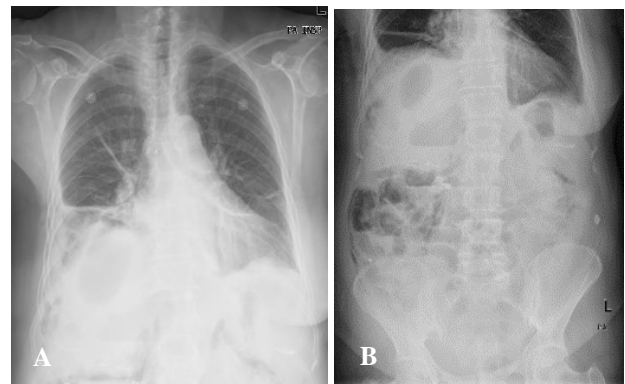
A 74-year-old woman was referred to our Hospital after been diagnosed with a duodenal neuroendocrine tumor. She presented epigastric pain and pyrosis that started nine years before, and episodes of diarrhea alternating with periods of constipation. There was no record of lower GI bleeding. The patient's medical history included right mastectomy due to breast carcinoma, cholecystectomy due cholelithiasis, arterial hypertension, and osteoporosis.

Upper GI endoscopy revealed a 10mm lesion, sessil – 0-Is (Paris classification) – on inferior surface of the first portion of the duodenum. The blood tests results showed elevated gastrinemia – 202ng/mL (normal range: 13-115 ng/ml). PET-DOTANOC captured a lesion on duodenal bulb. Colonoscopy had showed no relevant changes. The patient was evaluated and was sent to perform an endoscopic submucosal dissection, with administration of saline solution and adrenaline in submucosa layer, and excision of the neoplasm with diathermic loop. After excision, a small laceration in the duodenal wall was recognized and was immediately repaired by endoscopy with over-the-scope clips (OTSC) and through-the-scope clips (TTSC). The patient was stable during all the procedure. Conservative management with broad-spectrum antibiotic (1g imipenem) was initiated. Patient was sent to Intensive Gastroenterological Care Unit (IGCU), started parenteral nutrition, empiric broad-spectrum antibiotics and fluid resuscitation. A thoracic x-ray was performed and showed no pneumoperitoneum (Figure 1).

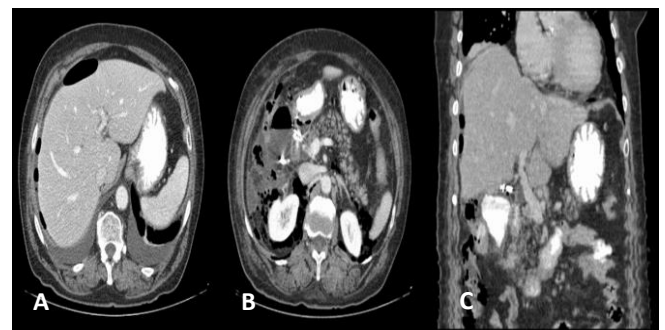


**Figure 1: Thoracic x-ray after ESD, without pneumoperitoneum.**

Four days later, she developed abdominal pain and increase in inflammatory parameters in blood tests: C-reactive protein 22.1 mg/dl (normal range < 0.05 mg/dL) and procalcitonin 4.09 ng/ml (normal range < 0.1ng/mL). Thoracic and abdominal x-rays were performed and (Figure 2).



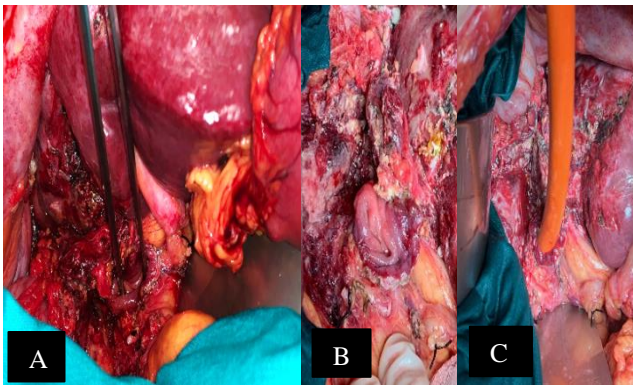
**Figure 2: Thoracic x-ray; (A) four days after ESD showing right pleural effusion and abdominal x-ray; (B) with abdominal gas-fluid levels and gas on liver shadow.**



**Figure 3: CT scan (axial view, portal phase) with pneumoperitoneum and retroperitoneum (A) and portal phase after oral contrast, leakage from duodenum, and periduodenal collection; (B) Frontal view, portal phase; (C) shows periduodenal collection with oral contrast, retroperitoneum and free air near the liver.**

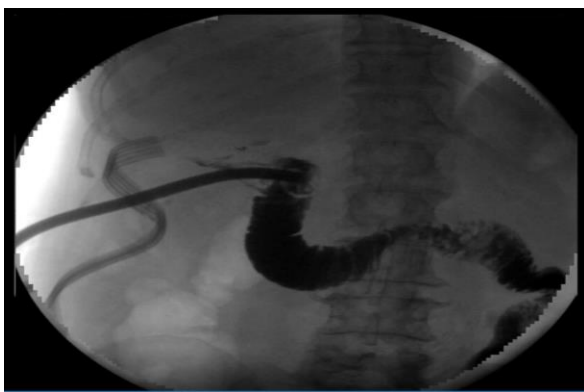An abdominal and pelvic computed tomography with oral and IV contrast was performed and revealed a subhepatic collection with gas inside (abscess), measuring 56x39mm; a thickening of the peritoneum in relation with peritonitis, pneumoperitoneum and bilateral retroperitoneum. An overflow of oral contrast was identified in the duodenum topography, and peritoneal fluid was identified at pelvic floor (Figure 3).

The patient was operated. During surgery a subhepatic abscess and a large perforation in the first portion of the duodenum were found. There was purulent fluid in the peritoneal cavity. Figures 4A and 4B show the findings after laparotomy. It was decided to perform a drainage of the subhepatic abscess and a gastric antrectomy with Roux-en-Y gastrojejunostomy. The duodenum perforation was treated by performing a duodenostomy, with a Pezzer tube (22 Fr) fixed with a double layer cerclage (polypropylene 2/0) in the duodenal stump. The Pezzer tube was exteriorized in the right hypochondrium (Figure 4C).



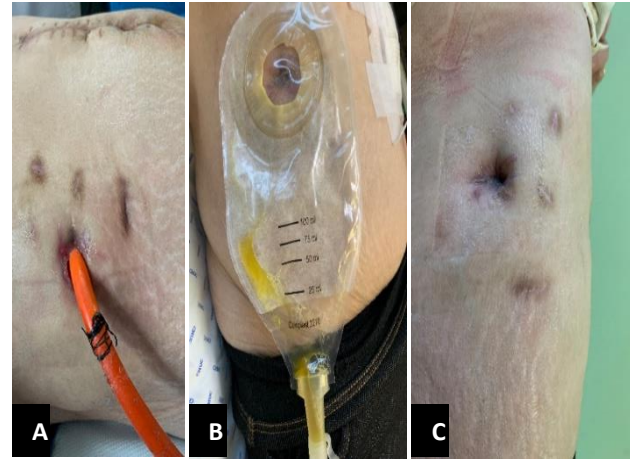
**Figure 4: (A) Dissection forcep pointing to duodenal perforation; (B) with peritonitis and necrotic tissues; (C) Pezzer tube in duodenal stump with double layer cerclage.**

The patient started oral feeding on the fifth day post-operative. A fistulography with hydrossoluble contrast through Pezzer tube was performed on the twentieth day post-operative, and showed no contrast leak. (Figure 5)



**Figure 5: Fistulography performed on the twentieth day post-operative, without contrast leak.**

Patient was discharged on post-operative day 41, clinically asymptomatic, with normal oral feeding intake. She had an infection due to *Clostridium difficile* and made oral metronidazole and a urinary tract infection with *Klebsiella pneumoniae*. The Pezzer tube was removed four months after surgery (Figure 6).



**Figure 6: Pezzer tube in the upper right abdomen (A), after tube remotion (B) and final result (C).**

The histology report of the mucosectomy specimen revealed a G3 neuroendocrine tumor of the duodenum, with 17x15x7mm, and the resection margins were clear. The tumor tested positive for chromogranin A and synaptophysin. The histology report of the surgical specimen shows no residual tumor.

## DISCUSSION

Duodenal NETs are rare, but recent widespread use of upper digestive endoscopy increase its detection.<sup>8</sup> At diagnosis, nearly 80% of the patients have small and localized disease. Endoscopic ultrasound and helical computed tomography (CT) allow staging regional and distant metastatic disease.<sup>3</sup> For localized disease, the median survival is 112 months. According to the European Neuroendocrine Tumor Society (ENETS) guidelines, small (<10 mm) duodenal NETs, well-differentiated, limited to the mucosa or submucosa, without metastatic disease, endoscopic treatment can be an option.<sup>3</sup>

Endoscopic submucosal dissection (ESD) is an effective approach for early neuroendocrine tumors (NET) treatment, because mostly of them develop in the submucosa layer.<sup>3,6</sup> It is a minimally invasive technique that enables complete resection of specimen<sup>9</sup>, and it provides better quality of life compared with surgery.<sup>1,9</sup> It also has advantage about endoscopic mucosal resection (EMR) in achieve a complete resection, with no residual tumor, and lower recurrence.<sup>8,10,11</sup> This technique is indicated mainly for large lesions ( $\geq 15-20$  mm) or flattened lesions that were difficult to remove by EMR, using a 1.5 mm or 2.0 mm short needle knife.<sup>4,12,13</sup>

Compared with surgery, ESD is less invasive and results in better patient quality of life.<sup>11</sup>

However, ESD as an increased complication rate, and is technically challenging, even in expert hand, due to anatomical duodenal specificities – thinner duodenal muscular wall, location in retroperitoneum, narrow lumen, rich submucosal vasculature, abundant Brunner’s glands that inhibit proper mucosal lifting and submucosal fibrosis – and technical difficulties.<sup>3,5,6,8,14</sup> Thermal injury or repeated coagulation, causing ischemic changes in duodenum wall, are also associated.<sup>4,6</sup>

Perforation and bleeding are two potential dangerous complications of ESD.<sup>2</sup> Duodenal perforation is defined as a transmural injury and are more frequent at distal duodenum, second and third portion and bulb at least.<sup>6,7</sup> The patient can have acute abdominal pain associated with free perforation or less acute symptoms associated with abscess or fistula formation. Chemical peritonitis is followed by systemic inflammatory response syndrome, which can progress to secondary bacterial peritonitis and sepsis. Patients with retroperitoneal perforation may haven’t peritoneal signs and present more indolently.<sup>7</sup> Duodenal ESD has an immediate perforation incidence of 6.3 to 50% and a delayed perforation incidence of 0 to 16,7%, that is higher comparing with other digestive tube organs.<sup>6,10,11</sup>

Duodenal perforation after the procedure can be classified into immediate, during the procedure, or delayed, without evidence during procedure or absence of pneumoperitoneum on abdominal radiography but with fever and pneumoperitoneum or retroperitoneum on CT scan.<sup>4,6</sup> Duodenum is a retroperitoneal organ and retroperitoneal perforation leads to accumulation of duodenal fluids, with retroperitonitis or retroperitoneal abscess, which can delayed diagnosis. CT is strongly recommended if there is suspicion.<sup>6,8,12,15</sup> CT scan with intravenous and oral contrast is the most valuable method for diagnosis duodenal perforation, and its necessary to evaluate indication for surgery.<sup>7</sup> CT can demonstrate retroperitoneal collection or intraperitoneal air, and extravasation of oral contrast.<sup>16</sup> Surgery is required for 14, 3 to 33% of perforations and it is more required in delayed than in intraoperative perforation.<sup>10,17</sup> Over-the-scope clip (OTSC) and through-the-scope clips (TTSC) are endoscopic devices that can control and treat duodenal perforation after ESD. Both devices are available to close immediate perforation and both have inverted closure. However, the size of mucosal defect after ESD is not negligible.<sup>6</sup> It has a success rate until 87.8%.<sup>5</sup> Completely closing could be difficult, especially in the distal portion of duodenum but, in order to improve outcomes, it is necessary complete closure of the whole mucosal defect.<sup>6,18</sup> Some studies show using those clips to perform prophylactic clipping after endoscopic resection, although some authors don’t agree that is sufficient to prevent delayed perforation.<sup>4,12</sup>

In some cases duodenal perforation can be treated with endoscopy, conservative management or image-guided drainage, but in some cases those methods are insufficient, requiring surgical intervention.<sup>6</sup> After diagnosis, the first objective in the management of duodenal perforation is establish if the patient could be treated conservatively or would require image guided or surgical intervention.<sup>16</sup> Early diagnosis and prompt management of iatrogenic endoscopic perforations reduce the morbidity and mortality rates.<sup>20</sup> In patients with suspicion of duodenal perforation fluid resuscitation and broad-spectrum antibiotics are mandatory; intravenous PPIs, nasogastric tube insertion and parenteral nutrition it can be successful in some cases.<sup>7,16</sup> However, conservative treatment, with nasogastric tube to decrease the leak of digestive and biliary juice that will accumulate in the retroperitoneal space, and broad-spectrum antibiotic therapy leads to long-term hospital recover.<sup>11</sup> A persistent large fluid collection may require image guided or surgical drainage.<sup>16</sup> Endoscopic approach to delayed perforation is difficult due to progressive inflammation around the site.<sup>20</sup>

Retroperitoneal collections can also be drainage by interventional radiologists but due to its location, percutaneous drainage is difficult and has limited effectiveness.<sup>18,19</sup>

If the patient is with hemodynamic instability, or if endoscopic or interventional procedures fails, surgery for exploration is required.<sup>19</sup> Anatomy site, degree of the leak, patient’s performance status, and surgeon’s experience are factor that determine the optimal management after endoscopic perforation.<sup>16,20</sup> Surgical management has the objectives of control the sepsis and repair de perforation with or without diversion.<sup>20</sup> Surgical approach to the duodenum is invasive, and associated with significant morbidity and mortality.<sup>5</sup> Large duodenal perforations can be approached from drainage and pyloric exclusion to pancreaticoduodenectomy. These operations are technically demanding, require long operative times and are not appropriate for patients in sepsis and hemodynamically unstable.<sup>21</sup> Duodenal diversion (tube decompression, duodenal diverticulation or pyloric exclusion) is usually reserved for high risk patients with delay in diagnosis or larger defects in duodenal wall, by having a controlled fistula.<sup>16</sup> Pancreatectomy with duodenal preservation is a complicated procedure and has no benefit in reduction of morbidity and mortality over pancreaticoduodenectomy.<sup>21</sup>

Emergent pancreaticoduodenectomy is a highly invasive and difficult procedure with a cumulative mortality rate of 29%.<sup>11</sup> Roux en Y duodenojejunostomy is other technique for large duodenal perforation, but delayed diagnosis and hostile abdomen can increase leakage risk.<sup>21</sup> Duodenal decompression tube is an effective and safe technique in the management of the difficult duodenal injury. Duodenal tube decompression was firstly used in 1954 for the management of duodenal stump after gastrectomy. Tube duodenostomy is a simple technique, does not involve an



anastomosis, is easy to perform, with reduced leak rate, decrease morbidity and shorter hospital stay.<sup>21</sup> There are controversies about removal of duodenostomy tube on postoperative period, but no leak should be seen in the imaging studies obtained through the tube and it needs to stay in a minimum of 6 weeks.<sup>11,18</sup> After removing, duodenal leak may cease spontaneously when the output of the leak is low. Larger Pezzer than 22Fr can cause persistent duodenal leakage after remotion.<sup>18</sup> Isik et al demonstrated minimal operative morbidity (12,9%) and mortality (6,4%) using duodenostomy tube. Tube duodenostomy is a damage control procedure for large duodenal perforations when other techniques are not possible. Time interval between perforation and definitive treatment increases mortality.<sup>7</sup>

It was decided to perform a surgical drainage of the collection, since the patient has peritonitis and clinically was worse, with broad-spectrum antibiotics and parenteral nutrition. Our approach, after drainage of the collection, was to restore alimentary tract, performing a Y-en-Roux gastrojejunostomy after antrectomy, to remove the tissues in contact with the collection that can interfere with appropriate wound healing. The perforation was at D1; it was decided did not close duodenal stump because there was high risk of dehiscence, so it was performed a duodenostomy with a Pezzer tube making a controlled fistula. Our approach was successful.

## CONCLUSION

Endoscopic treatment of NETs is associated with significant morbidity. Duodenal perforation can occur, and its management is controverser. It can be conservative, endoscopic, image-guided, or surgical. Surgical approach is mandatory if the patient has peritonitis, is hemodynamic unstable or if other managements had failed. Performing a surgical diversion with duodenostomy was, in this case, a safe and a successful management

*Funding: No funding sources*

*Conflict of interest: None declared*

*Ethical approval: Not required*

## REFERENCES

- HJ Jung et al. Long-term outcome of endoscopic and surgical resection for foregut neuroendocrine tumors; *Journal of Digestive Diseases* 2015;16(10):595-600.
- Iwasaki T et al.; Surgical treatment of neuroendocrine tumors in the second portion of the duodenum: a single center experience and systematic review of the literature; *Langenbecks Arch Surg* 2017; 402(6):925-33.
- Gincul R et al.; Endoscopic treatment of sporadic small duodenal and ampullary neuroendocrine tumors; *Endoscopy* 2016; 48(11):979-86.
- Inoue T et al.; Delayed perforation: a hazardous complication of endoscopic resection for non-ampullary duodenal neoplasm; *Digestive Endoscopy* 2014; 26:220-7.
- Furukawa K et al.; Endoscopic Closure of Duodenal Perforation with the Over-the-scope-clipping System; *Intern Med.* 2016;55(21):3131-5.
- Fujihara S et al.; Management of a large mucosal defect after duodenal endoscopic resection; *World J Gastroenterol.* 2016 7;22(29):6595-609.
- Ansari D et al.; Diagnosis and management of duodenal perforations: a narrative review; *Scand J Gastroenterol.* 2019;54(8):939-44.
- Ichikawa D et al.; Laparoscopic and endoscopic co-operative surgery for non-ampullary duodenal tumors; *World J Gastroenterol.* 2016 21;22(47):10424-31.
- Li QL et al.; Endoscopic submucosal dissection for foregut neuroendocrine tumors: an initial study; *World J Gastroenterol.* 2012 Oct 28;18(40):5799-806.
- Shibagaki K, Ishimura N, Kinoshita Y; Endoscopic submucosal dissection for duodenal tumors; *Ann Transl Med.* 2017;5(8):188.
- Watanabe D et al.; Efficacy and safety of endoscopic submucosal dissection for non-ampullary duodenal polyps: A systematic review and meta-analysis; *Dig Liver Dis.* 2019;51(6):774-81.
- Matsuda Y et al.; Perforation associated with endoscopic submucosal dissection for duodenal neoplasm without a papillary portion; *World J Gastrointest Surg.* 2017;9(7):161-6.
- Yamasaki Y et al.; Current Status of Endoscopic Resection for Superficial Nonampullary Duodenal Epithelial Tumors; *Digestion.* 2018;97(1):45-51.
- Matsumoto S, Miyatani H, Yoshida Y; Future directions of duodenal endoscopic submucosal dissection; *World J Gastrointest Endosc.* 2015;7(4):389-95.
- Mori H et al.; Successful closing of duodenal ulcer after endoscopic submucosal dissection with over-the-scope clip to prevent delayed perforation; *Dig Endosc.* 2013;25(4):459-61.
- Machado No. Management of duodenal perforation post-endoscopic retrograde cholangiopancreatography. When and whom to operate and what factors determine the outcome? A review article; *J of Oncol Pract.* 2012;13(1):18-25.
- Fukuhara S et al.; Management of perforation related to endoscopic submucosal dissection for superficial duodenal epithelial tumors; *Gastrointest Endosc.* 2020;91(5):1129-37.
- Isik B et al.; A life-saving but inadequately discussed procedure: tube duodenostomy. Known and unknown aspects; *World J Surg.* 2007;31(8):1616-24; discussion 1625-6.
- Boumitri C et al.; Closing perforations and postperforation management in endoscopy: duodenal, biliary, and colorectal; *Gastrointest Endosc Clin N Am.* 2015;47-54.
- Kang DH et al.; Clinical outcomes of iatrogenic upper gastrointestinal endoscopic perforation: a 10-

year study; Bio Med Cent Gastroenterol. 2019;19(1):218.

21. Kutlu O, Garcia S, Dissanaik S; The successful use of simple tube duodenostomy in large duodenal perforations from varied etiologies; Int J Surg Case Rep 2013; 4(3):279-82.

**Cite this article as:** Simões J, Melo C, Camacho C, Fraga E, Bernardes A. Treatment of a duodenal perforation after mucosectomy: case report and literature review. Int Surg J 2021;8:1300-5.