

Case Report

Radial fillet flap following double ray amputation of the 2nd and 3rd fingers for invasive squamous cell carcinoma: a case report and review of the literature

Justin Weller*

Musgrave Ave Southport, Queensland, Australia

Received: 25 January 2021

Revised: 09 February 2021

Accepted: 10 February 2021

***Correspondence:**

Dr. Justin Weller,

E-mail: weller.justinj@gmail.com

Copyright: © the author(s), publisher and licensee Medip Academy. This is an open-access article distributed under the terms of the Creative Commons Attribution Non-Commercial License, which permits unrestricted non-commercial use, distribution, and reproduction in any medium, provided the original work is properly cited.

ABSTRACT

Double ray amputation of the hand due to malignancy is extremely rare, with a paucity of published cases. We reviewed the literature and analysed our own experience in order to familiarise clinicians with this rare condition through a discussion of its diagnosis, management and prognosis. We present the case of a 54-year-old male with invasive squamous cell carcinoma (SCC) of the 2nd web space. He underwent a double ray amputation of the 2nd and 3rd fingers with a radial fillet flap and has begun range of motion exercises after six weeks. SCC of the hand requiring a double ray amputation is extremely rare. An MRI is required to accurately diagnose and manage this condition. The ray amputation technique is important for ensuring negative margins. A fillet flap should be used to close the defect as it provides a sensate web-space and improves motor function prognosis.

Keywords: Case report, Ray amputation, Hand, SCC

INTRODUCTION

Squamous cell carcinoma (SCC) requiring partial hand amputation through the Ray technique is extremely rare. Although malignancies of the hand and digits are well recognised, there is a paucity of cases in the literature of those requiring amputation, with our literature review revealing no cases involving SCC.¹ We present the case of a SCC of the left hand with periosteal involvement that required a ray amputation of the 2nd and 3rd fingers, with the defect repaired using a radial fillet flap. We reviewed the literature and analysed our own experience in order to familiarise clinicians with this rare presentation through a discussion of its diagnostic considerations, management and prognosis.

CASE REPORT

We report the case of a 54-year-old right hand dominant male on whom a ray amputation of the left index and

middle digits was performed. The patient had a twelve-month history of a biopsy proven SCC on the 2nd web space of the left hand on a background of multiple previously excised non-melanoma skin cancers.

On examination, the lesion consisted of a 3 cm-by-3 cm fungating mass invading into the 2nd web space with the middle finger joint on show. There was mild limitation on extension and flexion at the metacarpophalangeal joints with no evidence of neurovascular compromise. X-rays showed no evidence of bony or joint abnormality. However, magnetic resonance imaging (MRI) identified osseous involvement of the 2nd and 3rd proximal phalanx, in addition to invasion of the 3rd extensor tendon and the radial neurovascular bundle of the 3rd proximal phalanx (Figure 1).

The patient was taken to theatre three months after the lesion was first seen in clinic. The delay can be attributed to the patient's desire to avoid any amputation. The

patient underwent a double ray amputation of the left index and middle fingers with a fillet flap from the radial index finger defect. The lesion was marked with a 1 cm margin. Median, ulna and superficial radial nerve blocks were performed. The lesion was excised via the volar aspect, whereby the radial neurovascular bundle of the ring finger was identified and preserved. Following this, the flexor tendons of the 2nd and 3rd fingers were excised and the neurovascular bundles of the middle and index fingers were ligated. At this time, the radial index finger fillet flap was raised in preparation for closure. The dorsal incision extended to the base of the 2nd and 3rd metacarpals, and the extensor tendons were cut. The metacarpals were then amputated at an oblique angle and the dorsal metacarpal ligaments were transected (Figure 2). The wound was closed with the radial fillet flap.

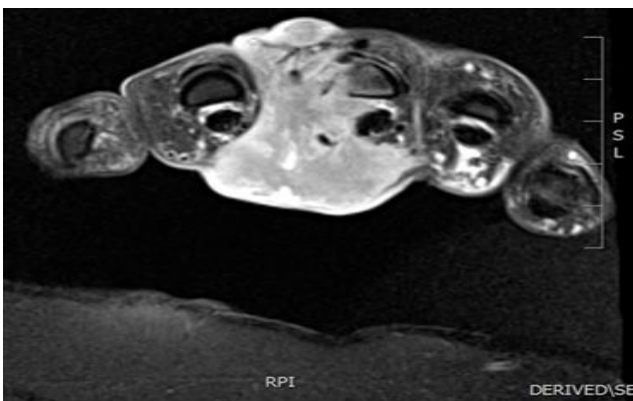


Figure 1: Initial transverse plane MRI of left hand, of malignancy invading the 2nd and 3rd metacarpals.

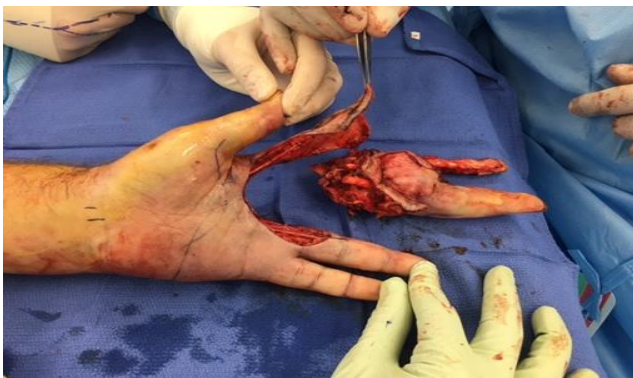

Figure 2: Intraoperative image following amputation, with amputated specimen.

Following routine discharge, the post-operative period was complicated by cellulitis of the left hand that required intravenous (IV) antibiotics and hypernatremia, both of which were treated in the same hospital admission. The histopathology revealed negative margins. After 6 weeks, the patient's flap has healed over 90% (Figure 3) and he has begun full range of motion activities but continues to splint the hand at night.

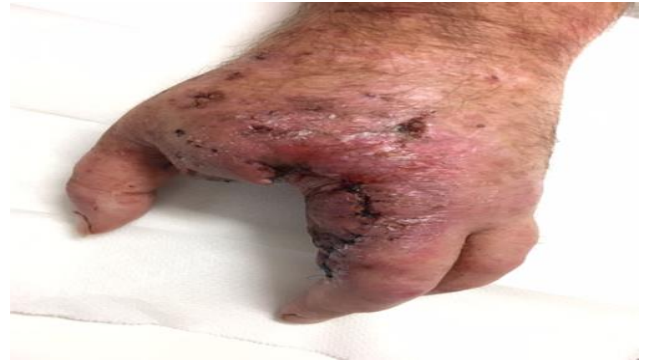

Figure 3: Six weeks post-operative showing dorsal aspect of hand and flap repair.

DISCUSSION

We conducted a thorough review of the English literature on PubMed, EMBASE and TRIP Premium using the keywords 'double ray amputation', 'malignancy' and 'flap'. This search revealed three retrospective studies examining the outcomes from partial hand amputations due to malignancy. None of the patients in these studies were diagnosed with SCC.

SCC of the hand typically presents with a slow growing, erythematous lesion.^{1,2} However, invasive SCC requiring amputation in the hand is extremely rare, as can be seen in the paucity of literature on such cases. Diagnosis of tumour extension in these cases normally requires the use of MRI.³ MRI is used to identify the involvement of the tendon sheaths and the neurovascular bundle, which determines the extent of the amputation required.

As with any malignancy, the aim of surgical management of SCC is to prevent local recurrence and metastasis.⁴ The literature in these cases clearly supports the importance of negative margins.^{5,6} The ray amputation technique is commonly used in order to ensure negative tumour margins and retain maximal hand function. This technique involves removal of the finger at the metacarpal base and closure of the gap between the fingers.³ This technique was used in our case and is consistent with the literature. Dorsal and circumferential incisions are used in order to increase the size of the available skin flap. A radial Fillet flap, which was used in the current case, can be used to close such defects, as seen in Puhaindran et al, but is more commonly used in traumatic amputations.^{6,7} The neurovascular bundles were deliberately spared in our procedure in order to improve the outcome of the fillet flap. A local fillet flap has the advantage of being technically simple and retains function well.

Puhaindran et al examined the hand function of patients following partial hand amputation.⁶ Although the patients who received a double ray amputation had the worst functional outcomes, they still retained a significant level of function. In our case, a radial Fillet flap was used. This

was chosen in order to retain sensation and improve motor function in the three remaining fingers. Koegel et al found that the sensation and function of a fillet flap was generally equal to the surrounding skin, while function was also comparable.⁸ In the current case, sensation has been retained in the flap but is decreased when compared with the surrounding skin. It is difficult to evaluate the patient's motor function as he has only recently begun range of motion exercises, although initial examination appears promising. The literature would suggest that a return to pre-operative function is not expected, although crucial functions such as pincer grip and overall grip strength will be somewhat retained.

CONCLUSION

SCC of the hand requiring a double ray amputation is a rare necessity. We describe the case of a 54-year-old man with an SCC on the 2nd web space of the left hand which was treated with a double Ray amputation. The literature review revealed 3 studies detailing such procedures. An MRI is essential to properly evaluate this condition. Our experience with this case suggests that a Fillet Flap should be used to close the defect, as it provides web-space sensation, comparable sensation with the surrounding tissue and improves motor function prognosis.

ACKNOWLEDGEMENTS

Author would like to thank Raja Sawhney, director of plastic surgery GCUH, fellow of the royal Australian college of surgeons (RACS), fellow of Australian society of plastic surgeons (FASPS).

Funding: No funding sources

Conflict of interest: None declared

Ethical approval: Not required

REFERENCES

1. Askari M, Kakar S, Moran SL. Squamous cell carcinoma of the hand: A 20-year review. *J Hand Surg Am.* 2013;38(11):2124-33.
2. Moy RL. Clinical presentation of actinic keratosis and squamous cell carcinoma. *J Am Acad Derm.* 2000;42(1):3-10.
3. Puhaindran ME, Athanasian EA. Double ray amputation for tumours of the hand. *Clin Orthop Relat Res.* 2010;468(11):2976-2929.
4. CHartier TK, Aasi SZ. Treatment and prognosis of cutaneous squamous cell carcinoma. 2016.
5. Puhaindran ME, Rohde RS, Chou J, Morris CD, Athanasian EA. Clinical outcomes for patients with soft tissue sarcoma of the hand. *Cancer.* 2011;117(1):175-9.
6. Puhaindran ME, Steensma MR, Athanasian EA. Partial hand preservation for large soft tissue sarcomas of the hand. *J Hand Surg Am.* 2010;35(2):291-5.
7. Kuntscher MV, Erdmann D, Homann HH, Steinau HU, Scott L, Gunter G. The concept of Fillet flaps: Classification, indications and analysis of their clinical value. *J Am Soc Pl Surg.* 2001;108(4).
8. Koegel AM, Banducchi DR, Kahler SH, Huack RM, Manders EK. Sensibility of finger fillet flaps on late follow-up evaluation. *J Hand Surg.* 1995;20(4):679-82.

Cite this article as: Weller J. Radial fillet flap following double ray amputation of the 2nd and 3rd fingers for invasive squamous cell carcinoma: a case report and review of the literature. *Int Surg J* 2021;8:1054-6.