

## Original Research Article

# Clinicopathological study of thyroid swellings and its correlation with ultrasonography

Snehil Shukla<sup>1</sup>, Badri Prasad Patel<sup>2\*</sup>, Samir Shukla<sup>2</sup>,  
Vinod Kumar Patel<sup>3</sup>, Kunal Vaidya<sup>2</sup>, Deepak Rathore<sup>2</sup>,  
Fahaduddin Ansari<sup>2</sup>, Jitendra Kumar Chaurasia<sup>4</sup>, Divya Chaurasia<sup>4</sup>

<sup>1</sup>School of Medical Science and Research, Greater Noida, Uttar Pradesh, India

<sup>2</sup>Department of Surgery, Gandhi Medical College, Bhopal, Madhya Pradesh, India

<sup>3</sup>People's College of Medical Science and Research, Bhopal, Madhya Pradesh, India

<sup>4</sup>Osh state medical university, Osh, Kyrgyzstan

**Received:** 28 January 2021

**Revised:** 06 March 2021

**Accepted:** 08 March 2021

### \*Correspondence:

Dr. Badri Prasad Patel,

E-mail: 1badri1@gmail.com

**Copyright:** © the author(s), publisher and licensee Medip Academy. This is an open-access article distributed under the terms of the Creative Commons Attribution Non-Commercial License, which permits unrestricted non-commercial use, distribution, and reproduction in any medium, provided the original work is properly cited.

## ABSTRACT

**Background:** Thyroid diseases are common and comprise a spectrum of entities. After diabetes mellitus, the thyroid gland is the most common gland to cause endocrine disorder. Lesions of thyroid are predominantly confined to female in the ratio 5:1 to male. Thyroid enlargement is the most common sign, it may be diffuse or generalized or localized. Both benign and malignant lesions of thyroid commonly present with a nodule. Prevalence of thyroid nodule ranges from 0.2% to 1.2% in children and from 4-10% in general adult population. Presently due to common use of ultrasonography in the clinical practice the incidence of thyroid nodule has risen to 14-50%.

**Methods:** A prospective, observational, single hospital base study done during the period from 2018 to 2020 in the Department of Surgery, Gandhi medical college Bhopal. Sample size was taken 60 patients.

**Results:** In this study as patients present with thyroid enlargement and ultrasonography scoring according to TIRAD score, as TIRAD score is increased possibility of malignancy increased. On the basis of ultrasonography of thyroid to detect the malignancy sensitivity is 88.9% and specificity is 98%.

**Conclusions:** Commonest clinical presentation is multinodular goitre is about 53% and ultrasonography scoring is TIRAD-2 and TIRAD-3 which was consistent with nodular hyperplasia. Second commonest clinical presentation is colloid goitre (31%) and ultrasonography score is TIRAD-2 and TIRAD-3. On the basis of ultrasonography TIRAD-4 and TIRAD-5 are about 13.4% and these findings consistent with Neoplastic thyroid swelling in histopathology.

**Keywords:** Goitre, Iodine deficiency, TIRAD score, Thyroid malignancy

## INTRODUCTION

Thyroid gland diseases are common and affect a large portion of general population. After diabetes mellitus, the thyroid gland is the most common gland to cause endocrine disorder. Disorders of the thyroid gland are the most common endocrine disease particularly in countries where iodine intake through diet is low. Normally thyroid

gland is not palpable. The term “goiter” (from the Latin word gutter = the throat) is used to describe generalized enlargement of thyroid gland. Disorders of thyroid gland present with either an alteration of hormone secretion or as enlargement (increase size) of the thyroid gland. Thyroid enlargement is the most common sign that are indicated for thyroid disease, it may be diffuse or generalized or localized. Which again classified as toxic or nontoxic. The non-toxic goiter is further classified on etiological basis as

endemic goiter and sporadic goiter. The sporadic goiter is due to dys-hormonogenesis or impaired utilization of trapped iodine. When more than 10% of population shows enlargement of thyroid gland called endemic goiter.

Lesions of thyroid are predominantly confined to female in the ratio 5:1 to male and this has been attributed to variation of thyroid hormones during female reproductive function and physiological event such as puberty, pregnancy and lactation. Typical problems related to thyroid disorder are fatigue, weight gain, depression, lethargy, dry skin, cold or heat intolerance, change in menstrual cycle, muscle cramps. Thyroid enlargement may be present in both hypothyroidism or hyperthyroidism.

Goitre commonly develops as a result of iodine deficiency, biosynthetic defects, autoimmune disease, and nodular diseases. Graves' disease and Hashimoto's thyroiditis are also associated with goitre. Both benign and malignant lesions of thyroid commonly present with a nodule. Various forms of thyroid cancer are relatively common and are amenable to be detected by physical examination. Prevalence of thyroid nodule ranges from 0.2% to 1.2% in children and from 4-10% in general adult population.<sup>1</sup> Now a days due to common use of ultrasonography in the clinical practice the incidence of thyroid nodule has risen to 14-50%.<sup>2</sup> The benign lesions of thyroid are more common and less than 5% are actually malignant.<sup>3,4</sup> The scenario in India is quite different. India has world's biggest "goitre belt" in the sub-Himalayan belt and average prevalence of goitre is around 40%. Though goitre is quite common, cancer of thyroid comparatively rare constituting less than 1% cancer.<sup>5,6</sup>

A thyroid enlargement may be localized in the form of nodule or diffuse must investigated to rule out neoplasm. FNAC is the first line investigation for patient with thyroid swelling along with ultrasound, thyroid function test, thyroid scan and level of antibodies are done subsequently with an aim to select who require surgery and those that can be managed conservatively.

Benign nodules can be due to adenomas, colloid nodules, cysts, infectious nodules, lymphocytic or granulomatous thyroiditis, hyperplastic nodules and congenital anomalies.

Malignant nodules can be classified as:

Differentiated- Papillary carcinoma, follicular carcinoma, papillo-follicular carcinoma variant of papillary carcinoma and hurthle cell carcinoma behaves like follicular carcinoma.

Undifferentiated- anaplastic carcinoma, medullary carcinoma, malignant lymphoma, secondaries in thyroid (rare)

Differentiated tumours, such as follicular thyroid cancer (FTC) or papillary thyroid cancer (PTC), are often curable,

and the prognosis is good for patients identified with early stage of disease.

Some unique features of thyroid cancer are:

Since thyroid nodules are readily palpable, it allows early detection and biopsy by FNAC.

As the thyroid gland has the unique and special property of taking up iodine radioisotopes anion, it can be used to diagnose (I123) and treat (I131) differentiated thyroid cancer. There are many serum markers which helps in the diagnosis of residual or recurrent disease which is an exciting future direction for thyroid nodule evaluation and treatment.

The management of goitre depends on the Aetiology and the detection of any thyroid enlargement on physical examination should give further evaluation to identify its cause. A plenitude of diagnostic tests, such as CT, thyroid sonography, thyroid nuclear scan and FNAC is available to the clinician for the evaluation of thyroid nodule.

Thyroid Ultrasonography should not be performed as a screening test. All patients with a palpable thyroid nodule, however, should undergo ultrasonography examination. US-guided FNA (US-FNA) is recommended for nodules > or = 10 mm; US-FNA is suggested for nodules < 10 mm only if clinical information or US features are suspicious.<sup>6</sup>

Ultrasound finding of thyroid is based on TIRADS (Thyroid Imaging Reporting and Data System).<sup>7,8</sup>

TIRADS 1: normal thyroid gland

TIRADS 2: benign lesion (0% risk of malignancy).

Avascular anechoic lesion with echogenic specks (colloid type I). Vascular hetero-echoic non-expansile, nonencapsulated nodules with peripheral halo (colloid type II). Isoechoic or hetero-echoic, nonencapsulated, expansile vascular nodules (colloid type III)

TIRADS 3: probably benign lesions (<5% risk of malignancy)

None of the suspicious malignant sonographic feature. These lesions are mostly benign with <5% risk of malignancy.

TIRADS 4: suspicious lesion (5% to 80% risk of malignancy)

Solid nodule with marked stiffness on elastography; markedly hypoechoic nodule; micro-lobulations or irregular margins; microcalcifications; taller than wider shape

TIRADS 4a: one suspicious feature (5-10% risk of malignancy)

TIRADS 4b: two suspicious feature (10-80% risk of malignancy)

TIRADS 4c: three/four suspicious feature (10-80% risk of malignancy)

TIRADS 5: probably malignant lesions (>80% risk of malignancy)

All five suspicious features (>80% risk of malignancy)

TIRADS 6: biopsy proven malignancy.

Ultrasound of thyroid gland is equally important as FNAC for diagnosis of any thyroid enlargement which may be benign, malignant or inflammatory. USG is the non-invasive, easily available, performed by radiologist, cost effective investigation for evaluation of thyroid pathology. It can be differentiated benign nodule from malignant nodule on the basis of reduced echogenicity, microcalcification, irregular margins, central hypervascularity, incomplete halo, tall rather than wide shape. For thyroid enlargement ultrasound guided FNAC can be taken for avoid injury of nearby vessels or nerve and for more accuracy of taking tissue for cytopathologic examination.

### ***Aims and objectives***

To analyse the clinical presentation of thyroid swellings. To analyse the presentation of hypothyroidism and hyperthyroidism with respect of thyroid swelling. Distribution of differentiated and undifferentiated malignancy, lymphoma, secondary with respect of age and sex. Co-relation of ultrasound finding of thyroid swelling with histopathological examination.

## **METHODS**

### ***Study design***

A Prospective, observational, single hospital base study done during the period from 2018 to 2020 in the Department of Surgery, Gandhi medical college Bhopal. All the patients who had come with complaint of thyroid swelling were selected for the study.

### ***Inclusion criteria***

Patients who had come with thyroid swelling in Hamidia Hospital, Bhopal. Patients who has been given consent for the study.

### ***Exclusion criteria***

Pregnant females. Patients who did not given consent for the study.

Ethical approval by ethical committee of Gandhi Medical College, Bhopal.

## ***Procedure***

Patient admitted and managed in Hamidia hospital Bhopal from June 2018 to September 2020. Patient including name, age, sex, address, presenting complaints, duration of thyroid swelling, general examination, local examination stating site, size and other characteristics of thyroid swellings were retrieved from records and noted in a prescribed proforma. Patients were subjected to clinical palpation, mobility during swallowing was assessed, lymph node examination, thyroid profile, ultrasound of thyroid and FNAC were done.

When patient admitted with complain of thyroid swelling after detail history and examination of thyroid ordered routine blood investigation, thyroid function test, ultrasound of anterior part of neck, fine needle aspiration cytology. For preoperative workup of patient with thyroid swelling indirect laryngoscopy done for assessment of normal anatomy and function of vocal cord and informed consent taken by patient and attender about the risk of operation and post-operative complication.

Patients who having symptom of hypothyroidism or hyperthyroidism and deranged thyroid function test first treated for the symptom or make patient in euthyroid state than we have to planned any surgical interventions. Recommendations regarding the initial management of thyroid cancer include those relating to screening for thyroid cancer, staging and risk assessment, surgical management, radioiodine remnant ablation and therapy, and thyrotropin suppression therapy using levo-thyroxine.<sup>9</sup>

### ***Data collection***

Data will be collected on individual basis by filling of the form by using proforma which will be recorded & compiled using Microsoft excel data sheet.

## **RESULTS**

Patients presented with thyroid swelling are predominantly females, out of sixty patients there is fifty are females and ten are male patients.

### ***Age and sex wise distribution of cases***

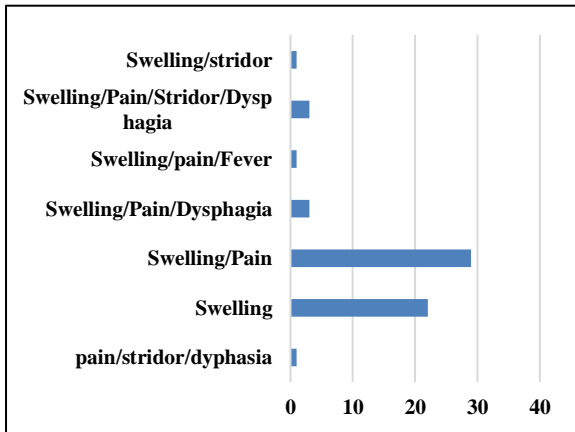
Female to male ratio is 5:1. Female dominating due to variable thyroid hormonogenesis. Average age of patients is 35.9 years. Average age of male patients is 37.2 years. Average age of female patients is 35.6 years.

### ***Clinical presentation***

Most of the patients present with swelling and pain of thyroid gland, some has pressure symptom such as stridor, dysphagia. Old aged patient present with additionally stridor and dysphagia with pain and swelling.

**Table 1: Age distribution.**

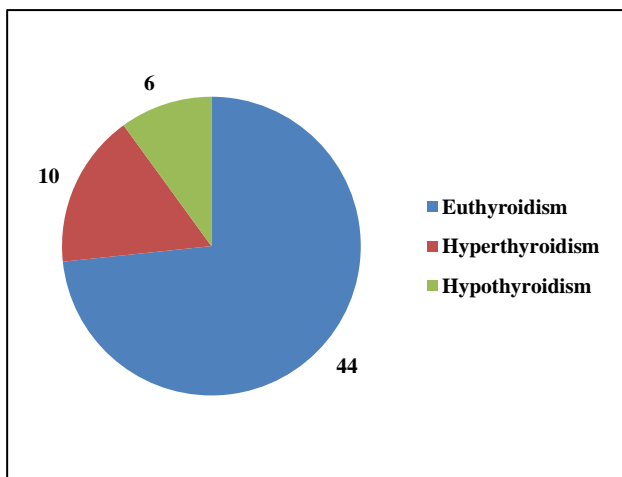
Age in years	Female	Male	Total
1-10	01	0	01
11-20	06	01	07
21-30	09	0	09
31-40	16	06	22
41-50	10	02	12
51-60	07	0	07
61-70	1	1	2
Total	50	10	60



**Figure 1: Count of chief complaints.**

**Thyroid profile**

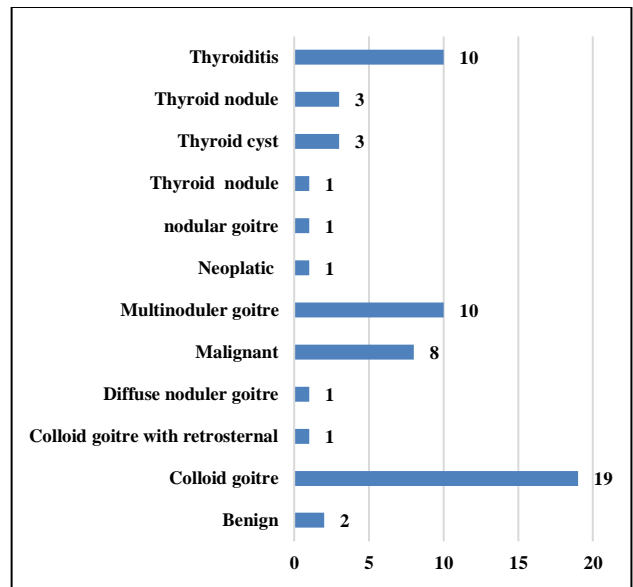
Thyroid function test is within normal in majority of patient that's called euthyroid. Patient was planned for surgery after normalise of thyroid function.



**Figure 2: Count of thyroid function.**

**Ultrasound correlation**

According to ultrasound of thyroid gland 8 patients suggested neoplastic pathology, one patient shows suspicious of malignancy, 2 patients shows thyroid nodules.



**Figure 3: Count of USG finding.**

**Incidence of benign and malignant pathology**

**Table 2: Incidence of benign and malignant pathology.**

Type	Number of patients	Percentage
Benign	51	85
Suspicious	1	1.6
Malignant	8	13.4
Total	60	100

**True positive diagnosis**

Defined as percentage of patients which shows feature of malignancy in both ultrasound and tissue report.

Our study show: 8 patients (13.4%) ultrasound finding and biopsy report suggested of feature of malignancy are true positive.

**True negative diagnosis**

Defined as percentage of patients whose shows benign findings in both ultrasound and tissue examination report. Our study show: 50 patients (83.4%) ultrasound finding and cytology report suggest benign disorder of thyroid are true negative.

**False negative diagnosis**

Defined as percentage of patients with benign findings who are confirmed to have malignant lesions of thyroid.

Our study show: One patient (1.7%) ultrasound finding suggested of benign thyroid swelling but after surgery biopsy report suggested of well differentiated carcinoma is false negative.

*False positive diagnosis*

Defined as percentage of patients with malignant finding on ultrasound who are found to have benign lesions at surgery.

Our study show: One patient (1.7%) ultrasound finding suggested of malignancy but biopsy report reveals hyperplastic nodular goitre is false positive.

*Sensitivity*

Sensitivity is the ability of a test to correctly classify an individual as diseased.

Sensitivity = true positive (a)/ true positive (a) + false negative (c)

Our study show: Sensitivity: 88.9%

*Specificity*

Specificity the ability of a test to correctly identify people without the disease.

Specificity = true negative (d)/ true negative (d) + false positive (b)

Our study show: Specificity: 98.0%

Sensitivity and specificity results depend on the suspicious category. If suspicious lesions are positive, then sensitivity increases and specificity decreases and vice versa.

**Table 3: Comparison of USG finding with histopathology.**

Diagnosis	True positive (a)	False positive (b)	False negative (c)	True negative (d)
Number of patients	8	1	1	50

Applying these values, the results are:

Sensitivity: 88.9%, specificity: 98.0%, false negative: 1.6%, false positive: 1.6%

*Positive predictive value*

Positive predictive value defined as the probability that subjects with a positive screening test truly have the disease.

PPV = true positive (a) / true positive (a) + false positive (b)

Our study show: PPV is 88.9%

*Negative predictive value*

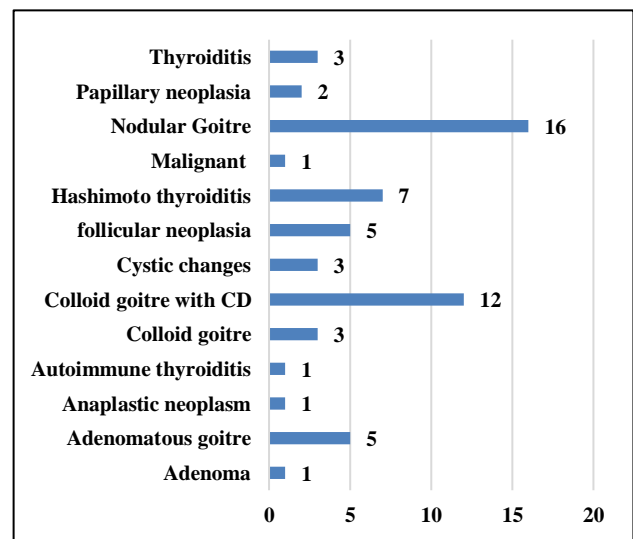
Negative predictive value defined as the probability that subjects with a negative screening test truly don't have the disease.

NPP = true negative (d) / true negative (d) + false negative (c)

Our study show: NPP is 98.0%

*FNAC findings*

Nodular goitre and colloid goitre with cystic degeneration is most common finding. 7 patients show feature of thyroiditis, 3 patients show feature of cystic collection.



**Figure 4: Count of FNAC.**

Cytopathology diagnosis is grounded on the “the national cancer institute thyroid fine needle state of science conference “Bethesda conference classification”.

*Incidence of malignancy*

Cytopathology report suggest that most of the patient having benign pathology, it's about 88%. On the basis of FNAC report about 14% patients shows feature of malignancy.

*Management*

Management of thyroid enlargement mainly by the surgical intervention required but sometimes there may be improvement of symptom by medical treatment.

*Type of surgical intervention*

Hemithyroidectomy (right or left hemithyroidectomy), subtotal thyroidectomy and total thyroidectomy.

**Table 4: Incidence of malignancy.**

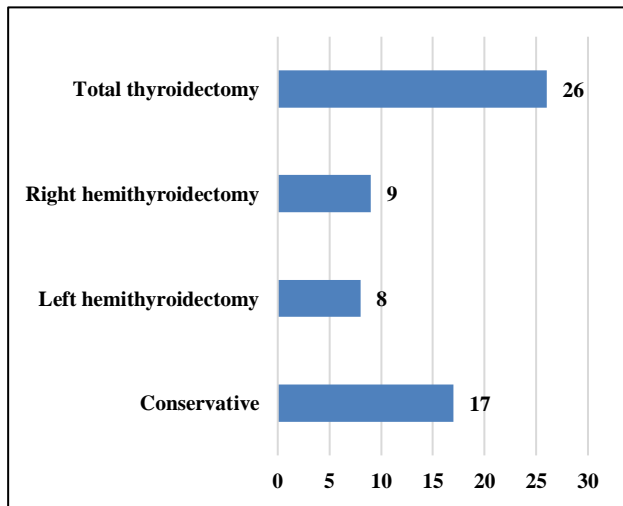
Type	Number of patients	Percentage
<b>Benign</b>	51	86
<b>Suspicious</b>	1	1.6
<b>Malignant</b>	8	13.4
<b>Total</b>	60	100

Out of 60 patients 43 patients required surgical intervention. After surgical intervention the thyroid specimen sent for histopathological examination. 8 patients biopsy report suggested of malignant disease of thyroid.

**Histopathology**

All patients who was operated for thyroid swelling specimen sent for histopathological examinations.

35 patients show feature of benign pathology on histopathology examination. 8 patients show feature of malignancy on histopathological examination.



**Figure 5: Count of operative procedure.**

**Table 5: Histopathology of specimen.**

Type	Number	Percentage
<b>Benign</b>	35	81.4%
<b>Malignant</b>	8	18.6%
<b>Total</b>	43	100%

**DISCUSSION**

Management of thyroid enlargement most depends on FNAC and ultrasound finding, whether it is benign or malignant. Benign condition such as goiter are mainly managed by medical and surgical treatment depends upon extent of enlargement, compressive symptom and for cosmetic purpose. Mostly malignant condition was treated by surgical removal of thyroid gland.

On the basis of ultrasound of thyroid most of the swelling are non-neoplastic. TIRADS (Thyroid Imaging Reporting and Data System) classified thyroid as normal thyroid, benign lesion, probably benign, suspicious for malignancy, probably malignant and biopsy proven malignant. In our study 85% patients shows benign, 1.6% patients are probably benign and 13.4% patients are malignant. Present study shows same results in study done in 2019 by Chaudhary that’s show 68% patients belonged to the benign, 16% patients are probably benign, 10% patients are suspicious for malignancy and 6% patients are found to be malignant.<sup>10</sup>

The sensitivity and specificity of ultrasound was 97.44% and 45.45% respectively with positive predictive value was 86.36% and negative predictive value was 83.33% in study done by Santosh et al in 2014. Present study also shows the sensitivity of 88.9%, specificity of 98% and positive predictive value and negative predictive value are 88.9% and 98%.<sup>11,12</sup>

The sensitivity and specificity of TIRADS was 92.31% and 45.45% respectively with positive predictive value was 85.71% and negative predictive value was 62.50% in study done by Chaudhary et al 2019 and Basharat et al in 2011.

Published literature on ultrasonography in the detection of neoplastic thyroid nodules revealed sensitivity ranges from 82 to 100%, specificity from 81 to 100%, PPV from 55 to 100%, and NPV from 93 to 100%.<sup>13-15</sup> Similar results also shows in our study.

In present study 84% are females and only 16% are males with male to female ratio is 5:1. Sex distribution was comparable to study by Sinna et al whose study showed male to female ratio was 5.2:1, and Screaton et al also showed male to female ratio was 5.2:1.<sup>15</sup>

For patients with thyroid nodules and differentiated thyroid cancer recommend FNAC as the procedure of choice in the evaluation of thyroid nodules. Patients ages varies between 10- 75 years. Present study also shows same result that in various other studies, it was most common in 3rd and 4th decades. Median age is 35.9 years in the study which is comparable to AMartinek.<sup>16</sup> Various studies of the thyroid swelling documented that thyroid lesions are more commonly occurred in females.<sup>17</sup>

The sensitivity rate in above series ranged from 75% to 98% with the exception of 55% in the study by Morgan et al (2003), in Australia.<sup>18</sup> Our results with a sensitivity of 88.9%. The specificity rates varied from 73% to 98.9% with the exception of Holleman et al (1995), who reported the specificity rate as low as 52%. Our results were comparable to the series with specificity rate of 98%. Analysis of the above series reveals an overall positive predictive value (PPV) ranging from 34% to 98% which implies presence of malignancy. A negative predictive value (NPV) i.e. negative for malignancy in the above

series ranged from 67.4% to 98.7%. Our results are comparable with a PPV of 88.9% and a NPV of 98%. This confirms FNAC as a good screening procedure for thyroid lesions. The diagnostic accuracy of FNAC ranged from 65% to 99% depending upon the expertise of the aspirator and cyto-pathologist interpreting the sample.<sup>18</sup> The diagnostic accuracy in present study was 96%. These data suggest that fine needle aspiration cytology is more specific than sensitive in detecting thyroid cancer and confirm it as a reliable diagnostic test.

The limitations of cytology are well recognized in the detection of some thyroid malignancies, in particular not to differentiate between follicular carcinoma and adenoma and also in the diagnosis of some papillary carcinoma. This is because of associated thyroid pathologies including MNG (multinodular goiter), marked cystic changes and thyrotoxicosis.

## CONCLUSION

Clinical presentation of thyroid pathology varied swelling of anterior aspect of neck, pain and compressive symptom like stridor and dysphagia. Patients presented with thyroid swelling is predominantly females, out of sixty patients there are 50 female and 10 male patients. Most of the childhood thyroid swelling managed conservatively. The average age of female patients is 35.6 and average male patients is 37.2 years.

The commonest clinical presentation is multinodular goitre is about 53% and ultrasonography scoring is TIRAD- 2 and TIRAD- 3 which was consistent with nodular hyperplasia of thyroid in histopathology. Second commonest clinical presentation is colloid goitre (31%) and ultrasonography score is TIRAD - 2 and TIRAD - 3 which was consistent with colloid goitre with degenerative change in histopathology finding. On the basis of ultrasonography TIRAD4 and TIRAD 5 are about 13.4% and these findings consistent with Neoplastic thyroid swelling in histopathology. On the basis of ultrasonography of thyroid to detect the malignancy sensitivity is 88.9% and specificity is 98%. Malignant pathology of thyroid consist papillary carcinoma (6.7%), follicular carcinoma (3.4%) anaplastic carcinoma 1.6%.

## ACKNOWLEDGEMENTS

We thank to Dr. Samir Shukla, Professor Department of Surgery, Gandhi Medical College, Bhopal for your guidance and support to complete this study. We also thank Mr. Nonelal Patel, Miss Ram bai Patel, Miss Reena Patel, Er. Satyabhan Patel for support to complete this study.

*Funding: No funding sources*

*Conflict of interest: None declared*

*Ethical approval: The study was approved by the Institutional Ethics Committee*

## REFERENCES

- Gharib H. Fine-needle aspiration biopsy of thyroid nodules: advantages, limitations, and effect. *Mayo Clin Proc.* 1994;69(1):44-49.
- Ezzat S, Sarti DA, Cain DR, Braunstein GD. Thyroid incidentalomas prevalence by palpation and ultrasonography. *Arch Intern Med.* 1994;154(16):1838-1840.
- Yeung MJ, Serpell JW. Management of the solitary thyroid nodule. *Oncologist.* 2008;13(2):105-12.
- Cappelli C, Castellano M, Pirola I, Gandossi E, De Martino E, Cumetti D, et al. Thyroid nodule shape suggests malignancy. *Eur J Endocrinol.* 2006;155(1):27-31.
- Agrawal S. Diagnostic accuracy and role of fine needle aspiration cytology in management of thyroid nodules. *Journal of Surgical Oncology.* 1995;58(3):168-172.
- American Association of Clinical Endocrinologists medical guidelines for clinical practice for the diagnosis and management of thyroid nodules. *Endocr Pract.* 2006;12(No. 1)
- Horvath E, Majlis S, Rossi R, Franco C, Niedmann JP, Castro A, et al. An ultrasonogram reporting system for thyroid nodules stratifying cancer risk for clinical management. *J Clin Endocrinol Metab.* 2009;94:1748-51.
- Kwak JY, Han KH, Yoon JH, Moon HJ, Son EJ, Park SH, et al. Thyroid imaging reporting and data system for US features of nodules: a step in establishing better stratification of cancer risk. *Radiology.* 2011;260:892-9.
- Management guidelines for patients with thyroid nodules and differentiated thyroid cancer. *Thyroid* 2006;16(2):109-42.
- Monika Chaudhary, Nitish Baisakhiya, Gurchand Singh Clinicopathological and Radiological Study of Thyroid Swelling. 2019 Indian J Otolaryngol Head Neck Surg. 2019;71(Suppl 1):S893-S904.
- Basharat R, Bukhari MH, Saeed S, Hamid T. Comparison of fine needle aspiration cytology and thyroid scan in solitary thyroid nodule. *Patholog Res Int.* 2011;754041.
- Takashima S, Fukuda H, Nomura N, Kishimoto H, Kim T, Kobayashi T. Thyroid nodules: re-evaluation with ultrasound. *J Clin Ultrasound.* 1995;23(3):179-184.
- Hong Y, Liu X, Li Z, Zhang X, Chen M, Luo Z. Real-time ultrasound elastography in the differential diagnosis of benign and malignant thyroid nodules. *J Ultrasound Med.* 2009;28:861-7.
- Asteria C, Giovanardi A, Pizzocaro A, Cozzaglio L, Morabito A, Somalvico F, et al. US-elastography in the differential diagnosis of benign and malignant thyroid nodules. *Thyroid.* 2008;18:523-31.
- Rago T, Santini F, Scutari M, Pinchera A, Vitti P. Elastography: New developments in ultrasound for predicting malignancy in thyroid nodules. *J Clin Endocrinol Metab.* 2007;92:2917-22.

16. Martinek A, Dvorackovia J, Honka M. Importance of Guided Fine needle aspiration Cytology (FNAC) for the diagnosis of Thyroid Nodules-Own Experience. *Biomed Papers.* 2004;148(1):45-50.
17. Wahid FI, Khan SF, Rehman HU, Khan IA. Role of fine needle aspiration cytology in diagnosis of solitary thyroid nodules. *Iranian Journal of Otorhinolaryngology.* 2011;23(4):111-8.
18. Morgan JL, Serpell JW, Cheng MSP. Fine-needle aspiration cytology of thyroid nodules: how useful is it? *ANZ Journal of Surgery.* 2003;73(7):480-3.

**Cite this article as:** Shukla S, Patel BP, Shukla S, Patel VK, Vaidya K, Rathore D et al. Clinicopathological study of thyroid swellings and it's correlation with ultrasonography. *Int Surg J* 2021;8:1218-25.