

Case Report

H type tracheo-oesophageal fistula: 2 cases with review of literature

Apoorva Makan, Syamantak Basu, Pankaj Dwivedi, Akriti Tulsian, Vini Joseph, Suraj Gandhi, Neha Sisodiya Shenoy, Hemanshi Shah*

Department of Paediatric Surgery, Topiwala National Medical College and B.Y.L. Nair Ch. Hospital, Mumbai, Maharashtra, India

Received: 25 January 2021

Revised: 03 March 2021

Accepted: 04 March 2021

***Correspondence:**

Dr. Hemanshi Shah,

E-mail: hemanshishah@gmail.com

Copyright: © the author(s), publisher and licensee Medip Academy. This is an open-access article distributed under the terms of the Creative Commons Attribution Non-Commercial License, which permits unrestricted non-commercial use, distribution, and reproduction in any medium, provided the original work is properly cited.

ABSTRACT

Tracheo-oesophageal fistula (TEF) with oesophageal atresia is a common life threatening congenital malformation. H type TEF is a rare subtype (1.8 to 4.2% of all TEF) with the least association with congenital anomalies. We report two cases of H type TEF, first patient was a 2 month old girl who presented with the classical triad of symptoms, and the second patient was a 2 year old girl who presented with recurrent attacks of pneumonia, choking on feeding and noisy breathing. After radiological confirmation, optimization of pulmonary status and nutritional improvement, both underwent right cervicotomy with disconnection of the H fistula. Both patients are doing well on regular follow up. Detection of H fistula is difficult as compared to TEF since the clinical symptoms are variable, radiological detection difficult and diagnosis is based on a high degree of clinical suspicion. We present these two cases to document the history, presentation, clinical management and surgical procedure done in these patients.

Keywords: H fistula, Rare, Difficult to diagnose

INTRODUCTION

H type TEF is a rare disorder with an incidence of 1 in 3500 to 1 in 4500 births.¹ It has several diagnostic and management related problems which warrant keen clinical attention.

Although labelled as H fistula, the tract runs an oblique course like the alphabet N from the cephalad opening on the posterior wall of the trachea to a more caudal position on the anterior wall of the oesophagus. The fistula has is usually located at the level of the neck root (C7-T1). Pressure changes between the two tubes leads to entry of air into oesophagus or vice versa entry of oesophageal contents into trachea.

The commonest presentation is a paroxysm of severe choking and cough precipitated by feeds. Abdominal distension due to passage of air from the trachea to the

oesophagus, and recurrent attacks of pneumonia due to aspiration are also common presentations.² Early detection and well planned management is necessary to prevent respiratory failure and morbidity. Some cases may remain undiagnosed until late infancy or childhood.³

CASE REPORT

Case 1

A 2 month girl presented with acute respiratory distress, choking on feeding and abdominal distention since birth. She was admitted for suspected pneumonia on 3 occasions within 2 months. The patient was referred for non-resolution of symptoms. Chest X-ray showed bilateral pneumonitis (right>left). 2D echo showed congenital acyanotic heart disease. Computed tomography (CT) neck and thorax showed ground glass opacities in the posterior segment of right upper lobe and lower lobe. Contrast

oesophagogram showed a 4.8 mm midline fistula, coursing anterosuperiorly between oesophagus and trachea at D2 level (Figure 1).

The child was medically optimized. Bronchoscopy revealed a fistula which could not be cannulated as the fistulous opening was very narrow. Right lower cervical transverse incision was taken and trachea and oesophagus were identified. Oesophagus was looped away to help identify the fistula (Figure 2). Fistula was looped and divided with closure of both tracheal and oesophageal ends. Tube feedings were started on post-operative day (POD) 2. Oesophagogram done on POD6 showed no leak or fistula. Patient is thriving well on follow up.

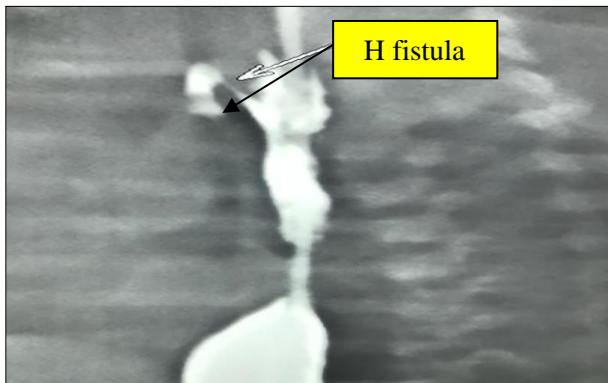


Figure 1: Contrast oesophagogram.

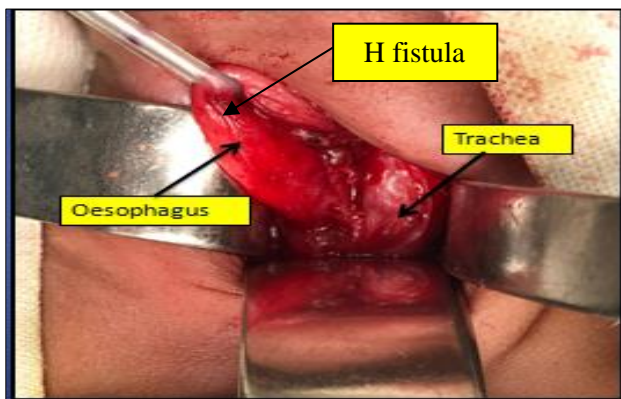


Figure 2: Intraoperative photograph showing H fistula.

Case 2

2 year girl presented with recurrent episodes of pneumonia, failure to thrive, coughing during feeding and noisy breathing. She had history of recurrent admissions for pneumonia and was referred for suspicion of H type TEF.

X ray chest was suggestive of pneumonitis. CT neck and thorax showed ground glass opacities in the right upper lobe and collapse of the right lower lobe. 2D echo was normal. Contrast oesophagogram demonstrated a 6 mm

fistula between oesophagus and trachea at D1 level coursing from oesophagus to trachea. After resolution of pneumonia, right cervicotomy with disconnection of the fistula was performed (Figure 3). Post-operative course was uneventful. Oesophagogram done on post-operative day 7 showed no leak (Figure 4). Patient is asymptomatic on follow up with good weight gain.

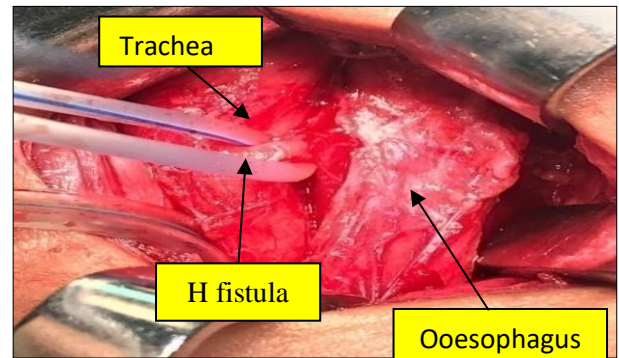


Figure 3: Intraoperative picture of H TEF.

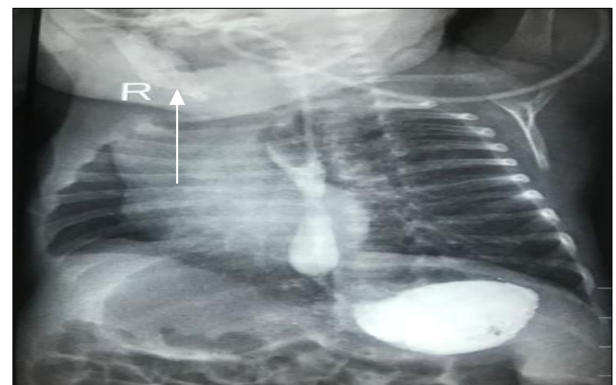


Figure 4: Post-operative oesophagogram.

DISCUSSION

H type TEF accounts for 4-5% of all congenital tracheo-oesophageal malformations and 1.8% to 4.2% amongst all types of TEF.³⁻⁵ The classical symptoms of an H type TEF include recurrent chest infections, choking on feeding and abdominal distension due to aerophagia through the fistula.³ H type TEF has least association (30%) with other congenital anomalies.³ Major series report VACTERL, ventricular septal defect, vascular rings, Fallot's tetralogy, chromosomal anomalies, duodenal atresia, renal anomalies, vertebral anomalies, CHARGE association, Goldenhar's syndrome, syndactyly, laryngeal cleft, imperforate anus and trisomy 21 as major anomalies.³

Killen and Greenlee, in a large survey, noted that the neonatal diagnosis was made in 43% and within the first year in 83% of the patients.⁶ Demonstration of H type fistula is difficult and may need repeated examinations. Recognition of symptoms and high clinical suspicion helps in early diagnosis. Failure to identify a type E TEF,

an unsatisfactory radiology and common vague symptoms related to associated anomalies may cause delay in diagnosis leading to increase morbidity and mortality.

Many diagnostic methods have been advocated for the diagnosis of H type fistula. Clinically, it may be occasionally possible to diagnose an H type TEF by passing a wide bore nasogastric tube and placing the end into a jar of water or attaching it to a stethoscope.⁷ As the tube passes the fistula, air will be seen, or heard, to escape. Unfortunately, high false positive and false negative rates mean that this method cannot and is not relied for diagnosis.⁷

The mainstay of diagnosis is a tube injection oesophagogram, during withdrawal of the tube, a technique that is most easily applicable to infants. Tube oesophagogram should be performed early when there is a clinical suspicion of H fistula. Other investigations should be considered if tube oesophagogram is inconclusive. Contrast enhanced studies have a potential risk of aspiration pneumonia and pulmonary injury and should be performed with adequate neonatal emergency resuscitation at hand.

Perioperative tracheobronchoscopy is an important investigation, which can be performed with fiberoptic endoscope or rigid ventilating bronchoscope. Bronchoscopic cannulation of the fistula with a radiological guide wire and passage of a nasogastric tube minimizes the risk of gastric distention and helps in easy identification of the fistula intraoperatively.⁷ Bronchoscopy is helpful in determining the: level of fistula; presence of unusual variants, e.g. double fistula, trifurcation fistula; presence and severity of tracheobronchitis and; position of the aortic arch as well as in placement of Fogarty's catheter.

Radiological and endoscopic procedures complement each other in both diagnosis and treatment of H type TEF. Upper gastro-intestinal endoscopy or rigid oesophagoscopy has no role in the diagnosis of H type TEF as the oesophageal ostium of a TEF is simply too small and is hidden in the oesophageal mucosal folds.

Three dimensionally computed tomography (3D CT) and virtual bronchoscopy have been used for the diagnosis of H TEF.⁸ MRI for diagnosis and localization of an H type TEF could also be used.⁹

Closure of the fistula is best achieved by surgical division. Surgery consists of division of the fistula and repair of both the tracheal and oesophageal walls. Different surgical approaches have been described for this anomaly. Proximally located fistulae are approached by cervicotomy and distal fistulas necessitate a thoracotomy.^{3,7}

Cervicotomy has a lower postoperative morbidity as compared to a thoracotomy.

Endoscopic closure of fistula has also been reported with tissue adhesives, electrocautery, sclerosants and lasers being used.

CONCLUSION

Congenital isolated H type TEF poses as a diagnostic dilemma. It is detected by a high index of clinical suspicion and classical symptoms. Some cases may remain undiagnosed until late infancy or childhood. Failure for early identification may cause delay in diagnosis and lead to morbidity and mortality. Surgical as well as endoscopic procedures have been described for the management of this condition.

Funding: No funding sources

Conflict of interest: None declared

Ethical approval: Not required

REFERENCES

1. Spitz L. Esophageal atresia and tracheoesophageal malformations. In: Ashcraft KW, Holcomb GW, Murphy JP, editors. Pediatrics Surgery. Saunders: Philadelphia, PA, USA. 2005;352-70.
2. Tarcan A, Gurakan B, Arda S, Boybat F. Congenital H type fistula: delayed diagnosis in a preterm infant. J Matern Fetal Neonatal Med. 2003;13:279-81.
3. Riazulhaq M, Elhassan E. Early recognition of H-Type tracheoesophageal fistula. APSP J Case Rep. 2012;3(1):4.
4. Waterston DJ, Carter REB, Aberdeen E. Esophageal atresia: tracheoesophageal fistula. Lancet. 1962;1:819.
5. Holder T, Cloud DT, Lewis JE, Pilling GP. Esophageal atresia and tracheoesophageal fistula. Pediatrics. 1964;34:542.
6. Killen D, Greenlee HB. Transcervical repair of H type congenital tracheoesophageal fistula. Ann Surg. 1965;162:67-9.
7. Crabbe DCG. Isolated tracheoesophageal fistula. Paediatr Respir Rev. 2003;1:74-8.
8. Le SD, Lam WW, Tam PK, Cheng W, Chan FL. H-type tracheo-oesophageal fistula: appearance on three-dimensional computed tomography and virtual bronchoscopy. Pediatr Surg Int. 2001;17(8):642-3.
9. Gunlemez A, Anik Y, Elemin L, Tugay M, Gokalp AS. H type tracheoesophageal fistula in an extremely low birth weight premature neonate: appearance on MRI. J Perinatol. 2009;29(5):393-5.

Cite this article as: Makan A, Basu S, Dwivedi P, Tulsian A, Joseph V, et al. H type tracheo-oesophageal fistula: 2 cases with review of literature. Int Surg J 2021;8:1350-2.