

Case Report

Acute appendiceal diverticulitis diagnosed in the postoperative context of appendectomy

Sofia M. Frade^{1*}, Ana K. Andrade¹, João S. Pimentel², Luis M. Moniz¹, Helder J. Viegas¹

¹Department of General Surgery, Centro Hospitalar Universitário de Lisboa Central, Lisbon, Portugal

²Department of Anatomical Pathology, Centro Hospitalar Universitário de Lisboa Central, Lisbon, Portugal

Received: 17 January 2021

Accepted: 03 February 2021

***Correspondence:**

Dr. Sofia M. Frade,

E-mail: samfrade@gmail.com

Copyright: © the author(s), publisher and licensee Medip Academy. This is an open-access article distributed under the terms of the Creative Commons Attribution Non-Commercial License, which permits unrestricted non-commercial use, distribution, and reproduction in any medium, provided the original work is properly cited.

ABSTRACT

Acute appendiceal diverticulitis is a rare cause of acute abdomen that is commonly interpreted as acute appendicitis until definitive histological result. We herein present two cases of patients of distinct age groups and gender who presented to the emergency department with right lower quadrant abdominal pain. Laboratory and imaging studies led to the diagnosis of acute appendicitis. In both cases, intraoperative findings were compatible with the initial diagnosis and therefore appendectomy was performed. Later pathological exam showed diverticulitis of the vermiform appendix. Although appendiceal diverticulitis is associated with a higher risk of perforation and neoplasms, both patients had linear postoperative period, without complications or dysplastic findings. Despite its similarities to the acute appendicitis, appendiceal diverticulitis presents itself as a distinct entity and should be suspected in patients with right lower abdominal pain in older age and with longer duration of symptoms.

Keywords: Appendiceal diverticulitis, Appendix, Appendectomy

INTRODUCTION

Acute appendiceal diverticulitis (AAD) is a rare entity than can mimic and lead to the diagnosis of acute appendicitis.¹⁻³ It was first described by Kelynack in 1893 and its incidence ranges from 0.004% and 2.1% depending of the series.³⁻⁷ Appendiceal diverticulosis can be classified in congenital or acquired.^{5,8} The congenital forms are true diverticula and extremely rare. Acquired diverticula are normally false diverticulum located on the mesenteric margin of the appendix.^{5,9,10}

The clinical manifestation are similar to those of acute appendicitis however it's presented at a greater age, with a more indolent course that can lead to delay in the diagnosis and a higher risk of complication such as perforation and it's also associated with appendiceal neoplasms.^{1,7,8,11,12} The surgical treatment is appendectomy.²

The diagnosis of AAD can be made imagiologically or intraoperatively, however, it is most commonly diagnosed during histologic specimen examination.^{1,2,3,13,14}

The aim of this paper is to report two cases of ADD diagnosed in the postoperative context of appendectomy.

CASE REPORT

We report two cases of acute appendiceal diverticulitis, in which acute appendicitis was suspected.

Case 1

A 28-year-old male, with no past medical history presented in the emergency room (ER) with right lower abdominal pain with 8 hours of evolution and no other associated symptoms. On physical examination the patient was hemodynamically stable, afebrile and abdominal examination revealed a distended abdomen with positive

Blumberg sign. Laboratory test results showed leukocytosis with neutrophilia and elevated PCR. Abdominopelvic computed tomography (CT) scan findings were compatible with a noncomplicated acute appendicitis.

Laparoscopic appendectomy was performed in this patient. Intraoperative findings were compatible with acute appendicitis. The appendix was in a pelvic position, markedly inflamed with associated gangrenous process. The appendix was resected without complications.

An appendiceal diverticulum was documented in the distal portion of the appendix with associated acute inflammatory process with an area of erosion and perforation (Figure 1).

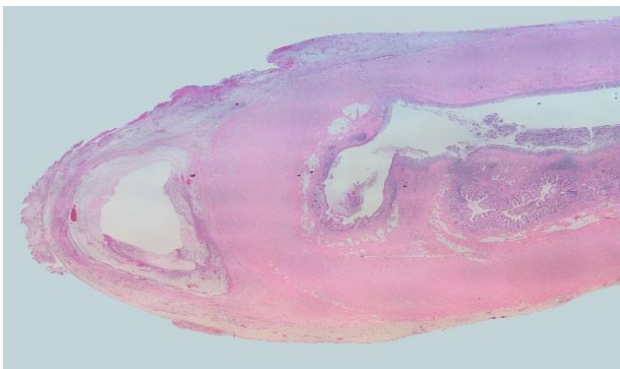


Figure 1: Histologic image of false diverticulum located at the tip of the appendix, with erosion of most of its mucosal surface and with an acute inflammatory infiltrate (patient 1).

Case 2

A 72-year-old female, with known history of arterial hypertension and dyslipidemia came to the ER with persistent right lumbar pain that irradiated to the right iliac fossa and increased with movement, with 2 days of evolution and without associated symptoms. On clinical examination she was stable with pain on the palpation in the right lower abdomen.

Laboratory findings included leukocytosis with neutrophilia and elevated PCR. CT scan showed a phlegmonous acute appendicitis with small amount of pelvic fluid (Figure 2).

We performed an open appendectomy through Mcburney's incision. The appendix was in a retrocecal position with inflammation of the entire appendix. During the procedure there was an iatrogenic lesion of the cecum that was corrected without further complications.

The vermiform appendix had two diverticular formations at its tip, both with focal erosion of the mucosa and marked adjacent acute inflammatory infiltrate, affecting the adjacent tissues (Figure 3).

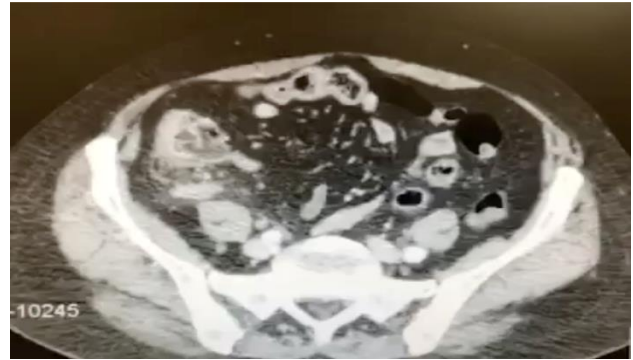


Figure 2: Pelvic CT scan of the patient showing signs of acute appendicitis.

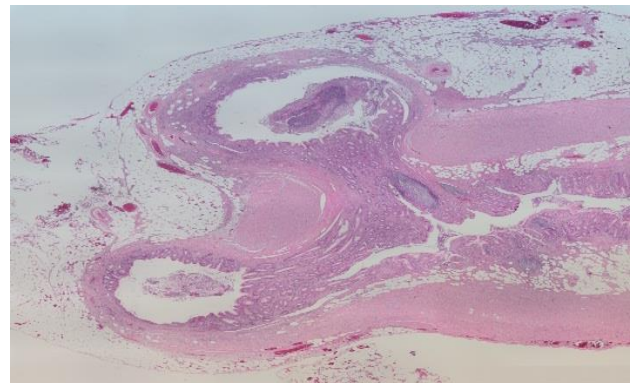


Figure 3: Histologic image of two false diverticula located at the tip of the appendix, with both of their mucosa slightly eroded and with an acute inflammatory infiltrate surrounding them (patient 2).

Both patients completed a 5-day antibiotic cycle and had a linear postoperative course with no complication.

In the first postoperative follow-up appointment (2 weeks following surgery) both patients were asymptomatic.

Follow-up was carried out up to 6 months postoperatively without any clinical complications. Colonoscopy was performed in both patients, only showing colonic diverticulosis in the patient of case 2.

DISCUSSION

Since first described by Kelynack in 1893, acute diverticulitis of the vermiform appendix has been overlooked.⁴ Its rare incidence (estimated among 0.004 to 2.1%) as well as its similarities to those of acute appendicitis both in clinical manifestations and treatment are the leading contributors to this fact.^{2,3}

Patients with appendicular diverticulitis have an average age of 38 years (higher compared to acute appendicitis which is in the twenties). It is more common in men and in patients with Hirschprung's disease and cystic fibrosis.⁵ Curiously, in the cases presented above, one was a men

and the other was a women, of different age groups, and without associated risk factors.

No association has been found between appendix diverticula and colon diverticular disease.¹³

Diverticulosis of the appendix can be classified as congenital and acquired based on the number of layers that herniate through the appendix wall. Congenital diverticula are extremely rare, usually located at the anti-mesenteric edge and involves all layers of the appendix wall (mucosa, submucosa, muscular and serosa) and as such it is associated with a lower perforation rate.^{11,14} Acquired diverticula are small (2-5 mm), normally located in the distal third of the appendix (60%), on the mesenteric edge and are pseudodiverticula (with herniation of the mucosa and submucosa through a defect on the muscular layer), which explains its higher tendency to perforate.^{3,15}

In the two cases presented both diverticula were acquired, which is the most common form, both being in the distal third, both on the mesenteric border. It should also be noted that in one of the cases the appendix was perforated.

Appendiceal diverticulitis were also classified by Phillips et al in 5 types based on microscopic findings (Table 1).¹⁶ The cases presented herein correspond to primary acute diverticulitis, with acute peridiverticulitis (type 1).

Table 1: Appendiceal diverticular disease classification according with Phillips et al.

Type	Classification
Type 1	Primary acute diverticulitis, with or without peridiverticulitis
Type 2	Acute diverticulitis secondary to acute appendicitis
Type 3	Diverticulum without inflammation
Type 4	Diverticulum with acute appendicitis
Type 5	Chronic peridiverticulitis with acute appendicitis

Preoperative diagnosis is difficult and most diagnoses are established after histological examination because of the mesenteric position, the small size and of course, the similar clinical features with acute appendicitis.²

In patients with acute diverticulitis when compared with acute appendicitis the diagnosis is frequently delayed due to a more indolent course, resulting in a higher duration of symptoms. Some studies advocate that the predominant symptom is abdominal pain, without nausea, vomit or anorexia.¹⁴

Preoperative diagnosis using ultrasound or CT scan have been reported, however in our cases, despite both having performed CT imaging, there was no evidence of diverticulitis and acute appendicitis was assumed.^{3,12,17,18}

Concomitantly, intraoperative evaluation showed no signs of a distinct diagnosis other than acute appendicitis.

Acute diverticular disease of the appendix is associated with some complications such as perforation, intraperitoneal abscess and appendiceal neoplasms (especially carcinoid tumors and mucinous adenomas). When compared to acute appendicitis, appendiceal diverticulitis is associated with 4 times higher risk of perforation (occurring around 66% of cases) and increased mortality.^{14,3}

The recommended treatment is appendectomy, which is also recommended in cases of incidental discovery of appendix diverticula (both intraoperatively and imaging), due to its progression in about 2/3 of the cases to diverticulitis, with high risk of perforation and the possibility of associated neoplasms.^{2,5,11}

CONCLUSION

Despite its similarities to the acute appendicitis, appendiceal diverticulitis presents itself as a distinct entity. Right lower abdominal pain in older age and with longer duration of symptoms should raise the suspicion of an acute appendiceal diverticulitis.

The diagnosis is usually histological however there are imaging tools that can support the preoperative diagnosis.

Appendiceal diverticulitis is associated with an elevated risk of perforation and appendicular neoplasms.

Appendectomy should be performed when diverticular disease of the appendix is found.

Funding: No funding sources

Conflict of interest: None declared

Ethical approval: Not required

REFERENCES

1. Arenas-Garcia V. Diverticulitis apendicular: una causa infrecuente de abdomen agudo. Rev Gastro Mex. 2019;84:243-4.
2. Sohn TJ. Clinical characteristics of acute appendiceal diverticulitis. J Korean Surg Soc. 2013;33-7.
3. Yardimci AH, Bektas CT, Pasaoglu, E. Retrospective study of 24 cases of acute appendiceal diverticulitis: CT findings and pathological correlations. Jpn J Radiol. 2017;35:225-32.
4. Kelynack. A Contribution to the Pathology of the Vermiform Appendix. London UK: Lewis HK, 1983;60-1.
5. Constantin VD. Appendiceal Diverticulitis - A case report. Chirurgia. 2017;112:82-4.
6. Abdull Gaffar B. Diverticulosis and diverticulitis of the appendix. Int J Surg Pathol. 2009;17:231-7.
7. Place RJ. Appendiceal diverticulitis. South Med J. 2000;93(1):76-9.

8. Dupre MP. Diverticular disease of the vermiform appendix: A diagnostic clue to underlying appendiceal neoplasm. *Hum Pathol.* 2008;39:1823-6.
9. Escobar F. Diverticulitis apendicular, revisión de la literatura científica y presentación de 2 casos. *Rev Colomb Cir.* 2013;28:223-8.
10. Alteieri ML. Appendiceal diverticulitis, a rare relevant pathology: presentation of a case report and review of literature. *Int J Surg Case Rep.* 2017;33:31-4.
11. Lamps LW. The coexistence of low-grade mucinous neoplasms of the appendix and appendiceal diverticula: A possible role in the pathogenesis of pseudomyxoma peritonei. *Mod Pathol.* 2000;13:495-501.
12. Lobo-Machín I. Appendiceal diverticulitis and acute appendicitis: Differences and similarities. *Rev Esp Enferm Dig.* 2014;106(7):454-8.
13. Lee KH. Appendiceal diverticulitis: diagnosis and differentiation from usual acute appendicitis using computed tomography. *J Comput Assist Tomogr.* 2007;31:763-9.
14. Deng YW. Appendiceal diverticular disease. *Form J Surg.* 2013;46:4-9.
15. Albeeshi MZ. Appendiceal diverticulitis presenting as acute appendicitis diagnosed postoperatively. *J Surg Case Rep.* 2019;12:1-3.
16. Phillips BJ. Appendiceal diverticulitis. *Mayo Clin Proc.* 1999;74(9):890-2.
17. Kubota T. Sonographic findings of acute appendiceal diverticulitis. *World J Gastroenterol.* 2006;12:4104-5.
18. Osada H. Appendiceal diverticulitis: multidetector CT features. *Jpn J Radiol.* 2012;30:242-8.

Cite this article as: Frade SM, Andrade AK, Pimentel JS, Moniz LM, Viegas HJ. Acute appendiceal diverticulitis diagnosed in the postoperative context of appendectomy. *Int Surg J* 2021;8:1004-7.