

## Case Report

# A solitary primary subcutaneous hydatid cyst in the thigh: a case report

Ahmed AE. Taki-Eldin\*

General Surgery Department, Faculty of Medicine, Northern Border University, Arar, Kingdom Saudi Arabia

**Received:** 22 November 2015

**Accepted:** 16 December 2015

**\*Correspondence:**

Dr. Ahmed AE. Taki-Eldin,

E-mail: [ahmedag4000@yahoo.com](mailto:ahmedag4000@yahoo.com)

**Copyright:** © the author(s), publisher and licensee Medip Academy. This is an open-access article distributed under the terms of the Creative Commons Attribution Non-Commercial License, which permits unrestricted non-commercial use, distribution, and reproduction in any medium, provided the original work is properly cited.

### ABSTRACT

Hydatid disease is a parasitic infestation caused by *Echinococcus granulosus*. It occurs frequently in liver and lung. Hydatid disease of the soft tissue is uncommon. In this paper, we report a case of a primary subcutaneous hydatid cyst in the thigh. We report a case of a 45-year-old female who presented to our hospital with a painless subcutaneous mass in the medial aspect of the right thigh for one year. Computed tomography scan demonstrated a subcutaneous cystic lesion close to adductor magnus muscle. The diagnosis of hydatid cyst was suspected peroperatively, complete surgical excision of the mass was done and the patient had an uneventful post-operative recovery. The suspected diagnosis was confirmed by histopathological examination. This case shows that hydatid cyst should be considered in the differential diagnosis of any cystic mass at different anatomical sites, especially in endemic regions. Total excision of the cyst with an intact wall remains the mainstay of treatment.

**Keywords:** Hydatid disease, Echinococcosis, Cyst, Thigh mass, Subcutaneous cyst

### INTRODUCTION

Hydatid disease is a parasitic infestation caused by *Echinococcus granulosus*, a cestode of the Taeniidae family.<sup>1</sup> It is characterized by cystic lesions occurring in different parts of the human body. The main hosts for *E. granulosus* are dogs, wolves, and foxes, the intermediate hosts include sheep, goats, and cattle. Humans are a coincidental intermediate host. Endemic areas are countries of the temperate zones, where the intermediate hosts are raised, such as in the Middle East, Central Europe, Australia and South America.<sup>2</sup>

The liver is the most common involved organ (70-75%), followed by the lung (10-15%). Other locations are rare, primary subcutaneous hydatid cyst is extremely rare, and its incidence is unknown.<sup>2-4</sup>

In this report, we present a case of primary hydatid cyst located subcutaneously in the medial aspect of the right thigh.

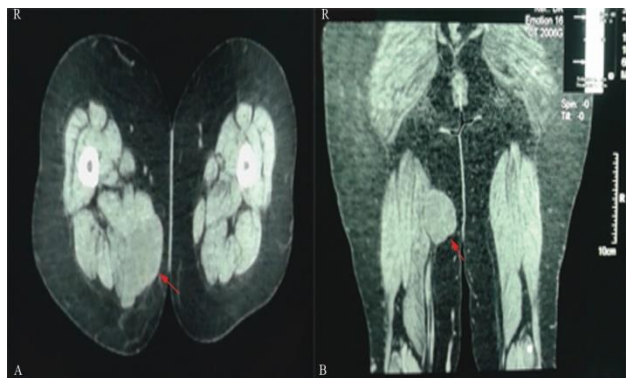
### CASE REPORT

A 45 year old female patient presented to the surgical clinic of arar central hospital, northern border region, Saudi Arabia, with a subcutaneous slowly growing painless cystic mass in the medial aspect of the right thigh for about one year. There was a history of excision of subcutaneous lipoma at the same site three years ago; there was no history of trauma in the thigh, no history of fever or loss of weight. There was no history of surgery for a hydatid cyst in any other organ.

On physical examination, a mobile, painless cystic mass was palpated in the medial aspect of right thigh. It was 8 × 6 cm mass. The overlying skin was normal apart from 5 cm scar.

The preoperative investigations (complete blood count (CBC), blood biochemistry and chest X-ray) revealed no abnormalities apart from eosinophilia. Enzyme-linked immunosorbent assay (ELISA) was negative for *Echinococcus granulosus* antigens.

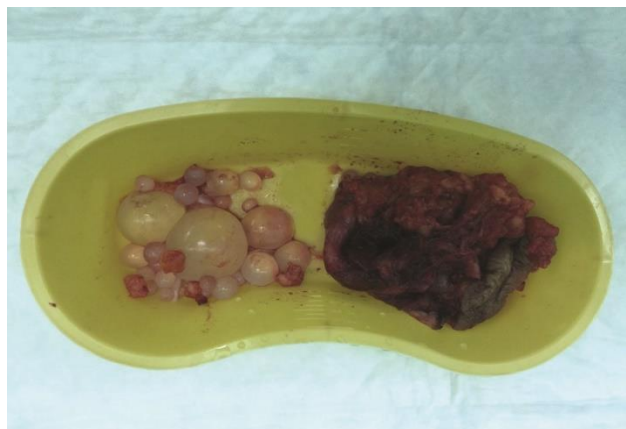
Ultrasound (US) and computed tomography (CT) on the right thigh demonstrated a subcutaneous cystic lesion close to adductor magnus muscle (Figure 1). Abdominal ultrasonography and chest x ray did not reveal any abnormality.



**Figure 1: Computed tomography (A) axial section (B) coronal section, showing a subcutaneous hydatid cyst in the medial side of the right thigh (red arrows).**

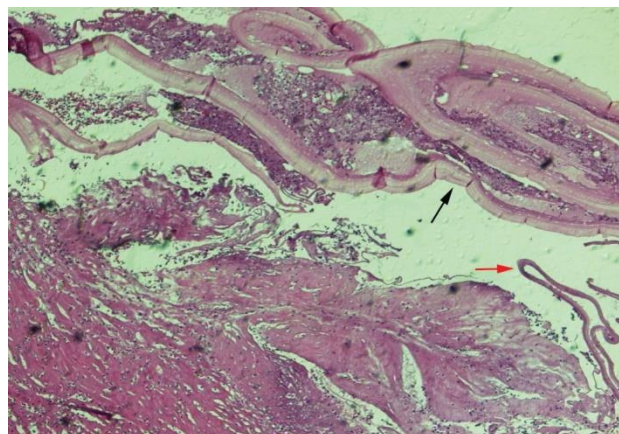
Surgical exploration of the mass was performed under general anesthesia. The diagnosis of hydatid cyst was confirmed peroperatively after visualization of the cyst wall.

The surgical field was packed with 20% hypertonic saline solution, the cyst was aspirated and irrigated with hypertonic saline solution and was completely excised (Figure 2). The cyst was found to be a primary subcutaneous hydatid cyst with intramuscular extension into adductor magnus muscle. The surgical site was irrigated with hypertonic saline and the subcutaneous layers and the skin were closed in the standard manner.



**Figure 2: Image of the totally excised hydatid cyst with daughter cysts.**

Histopathological examination of the specimen showed a hydatid cyst (Figure 3). Postoperative CT showed no involvement of the lung and brain.



**Figure 3: Histopathologic section (hematoxylin and eosin stain) of the cyst showing Inner germinal (red arrow) and lamellated (black arrow) layers of cyst wall.**

Following the surgical procedure, albendazole (15 mg/kg/day) was administered for 3 months. The patient has been followed for one year, and no findings associated with local or systemic hydatid cyst recurrence were detected.

## DISCUSSION

The Incidence of subcutaneous hydatidosis is unclear, it is ranging from 2% to 9% according to different studies.<sup>5,6</sup>

Subcutaneous hydatid cyst may be primary or secondary. In secondary cysts, there is a primary location of hydatid disease such as liver, lung, or spleen which may be operated or not. In our case, the hydatid cyst was situated subcutaneously, the patient had not any history of previous surgical intervention for hydatid cyst, and no hydatid cysts were found in other organs. Therefore, this case was diagnosed as primary subcutaneous hydatid cyst.

The mechanism of primary subcutaneous localization is unclear. The ingested parasite's ova penetrate the intestinal wall, and reach the liver through the portal vein. In the liver, most of them are caught in the hepatic sinusoids. A few ova may pass through the liver (first filter) and reach the lung (second filter) and the systemic circulation, causing hydatid disease in other organs.<sup>3,5</sup> cases with solitary cysts in uncommon sites could be attributed to systemic dissemination through lymphatics.<sup>7</sup> Another possible mechanism of infection is direct spread from adjacent sites provided a microrupture has occurred.<sup>8</sup>

The diagnosis of echinococcosis should be excluded before surgical excision of the cyst to avoid leakage of cyst contents and the possible risks of anaphylaxis and local recurrence.

The clinical course is non-specific and depends on many factors such as the site of involvement, the size of the cyst, and the pressure caused by the enlarged cyst.<sup>5</sup> Hydatid cyst usually presents as painless, non-inflammatory mass without any deterioration of the patient's general condition. However, the cyst can simulate an abscess or a cancer if it is super-infected or cracked.<sup>4,6</sup> History of animal contact (especially dogs) and living in a sheep-raising or cattle-raising rural area is generally present.

Ultrasonography (US) and computed tomography (CT) are the main diagnostic tools, with 85% and 100% sensitivity, respectively. Although US is a reliable method for detecting echinococcal cysts, CT can define unique characteristics of hydatid cysts and also reveals the site, relationship to adjacent organs and additional small unsuspected lesions.<sup>9,10</sup> The specific radiological findings of hydatid cyst are thick cyst wall, calcifications, daughter cysts, and a germinative membrane separated from the cyst wall.<sup>4,5,7</sup>

Preoperative diagnosis of musculoskeletal *E. granulosus* infection is difficult clinically and radiologically as it may resemble any soft tissue tumor. Magnetic resonance imaging (MRI) is sufficiently demonstrating most features of hydatid disease, with the exception of calcifications. Signs of hydatid cyst in MRI are multivesicular lesions with or without hypodense peripheral ring (rim sign), cysts show low signal intensity on T1-weighted images and high-signal intensity on T2-weighted images.<sup>11</sup>

Serology is a useful tool for the diagnosis. The most frequently used serological tests for diagnosis of hydatid disease are Casoni intradermal skin test, Weinberg complement fixation (CF) test, indirect hemagglutination (IHA) test, ELISA, and western blot (WB). Patients with a liver cyst have a higher rate of serologic test sensitivity than those having extra hepatic and extra-pulmonary involvement.<sup>5,6,12</sup>

A positive serological test for hydatid cysts is significant, however, negative test does not indicate the absence of the disease, as in our patient. The serological tests are complementary to the clinical and radiologic findings and they can also be used in the follow-up of patients after surgical resection.<sup>12</sup>

Blood eosinophilia occurs in 20% to 34% of patients.<sup>13</sup> It is a nonspecific sign as it may be seen in other pathologies. Patients with ruptured cysts were found to have a higher rate of eosinophilia.<sup>14</sup>

Complete surgical excision of the intact cyst is the best treatment option, as it prevents leakage of cyst content that may cause anaphylaxis and local recurrence.<sup>3,4,6</sup> Various scolical agents have been used peroperatively, such as 0.04% chlorhexidine gluconate, 20% hypertonic saline, 0.5% silver nitrate, 10% povidone-iodine, and 2% formalin. The scolical activity of povidone-iodine was found to be better than that of hypertonic saline in experimental studies, but iodine has toxic effects on peritoneal mesothelial cells.<sup>2</sup> If the excision of a large cyst en block is impossible, the cyst has to be drained intraoperatively, irrigated with a scolical agent and then excised.<sup>3,5</sup>

Medical treatment with an antihelminthic agent benzimidazole compound, either mebendazole or albendazole, is usually administered for the established hydatid disease. Albendazole is proved to be more effective than mebendazole. The standard dose of albendazole is 10 to 15mg/kg/d given in two divided doses. One to two weeks interval should be given between three weeks and four weeks cycles, due to the hepatotoxicity of albendazole. The treatment may last for 3 to 6 months. Antihelminthic agents can reduce the size of cysts in some cases, however the results are not satisfactory and this treatment option should be limited for disseminated and recurrent cysts or in cases where surgery is contraindicated.<sup>15</sup>

## CONCLUSION

Hydatid cyst should be included in the differential diagnosis of any subcutaneous cystic mass, especially in endemic regions. Total excision of the cyst with an intact wall is the best treatment option.

## ACKNOWLEDGEMENTS

The author would like to thank Prof. Taha Motamad, for his fruitful contribution as regard pathological examination of the specimens.

*Funding: No funding sources*

*Conflict of interest: None declared*

*Ethical approval: Written informed consent was obtained from the patient for publication of this Case Report and any accompanying images. All procedures followed were in accordance with the ethical standards of the responsible committee on human experimentation (institutional and national) and with the Helsinki Declaration of 1975, as revised in 2008.*

## REFERENCES

1. Kern P, Bardonnat K, Renner E, Auer H, Pawlowski Z, Ammann RW. European echinococcosis registry: human alveolar echinococcosis, Europe, 1982–2000. *Emerg Infect Dis.* 2003;9(3):343-9.
2. Kayaalp C. Hydatid cyst of the liver. In: Blumgart LH, Belghiti RJ, DeMatteo RP, et al, eds. *Surgery of*

- the Liver, Biliary Tract, and Pancreas. 4th ed. Philadelphia, PA: Saunders Elsevier. 2007:952-70.
3. Dirican A, Unal B, Kayaalp C, Kirimlioglu V. Subcutaneous hydatid cysts occurring in the palm and the thigh: two case reports. *J Med Case Reports.* 2008;2:273.
  4. Ousadden A, Elbouhaddouti H, Ibnmajdoub KH, Mazaz K, AitTaleb K. A solitary primary subcutaneous hydatid cyst in the abdominal wall of a 70-year-old woman: a case report. *Journal of Medical Case Reports.* 2011;5:270.
  5. Orhan Z, Kara H, Tuzuner T, Sencan I, Alper M. Primary subcutaneous cyst hydatid disease in proximal thigh: an unusual localisation: a case report. *BMC Musculoskelet Disord.* 2003;4:25.
  6. Rezakhaniha B, Sirosbakht S. Coincidental hydatid cyst of skin and kidney: a very rare case report. *Iran J Pathol.* 2010;5:47-50.
  7. Ok E, Sözüer EM. Solitary subcutaneous hydatid cyst: a case report. *Am J Trop Med Hyg.* 2000;62:583-4.
  8. Safioleas M, Nikiteas N, Stamatakos M, Safioleas C, Manti CH, Revenas C. Echinococcal cyst of the subcutaneous tissue: A rare case report. *Parasitol Int.* 2008;57:236-8.
  9. Gunay K, Taviloglu K, Berber E, Ertekin C. Traumatic rupture of hydatid cysts. A 12-year experience from an endemic region. *J Trauma.* 1999;46:164-7.
  10. Guraya SY, Alzobydi AH, Guraya SS. Primary extra hepatic hydatid cyst of the soft tissue: a case report. *Journal of Medical Case Reports.* 2012;6:404.
  11. Diez G, Mendoza LHR, Villacampa VM, Cózar M, Fuertes MI. MRI evaluation of soft tissue hydatid disease. *EurRadiol.* 2000;10:462-6.
  12. Gonzalez AN, Muro A, Barrera I. Usefulness of four different echinococcus granulosus recombinant antigens for serodiagnosis of unilocular hydatid disease (UHD) and postsurgical follow-up of patients treated for UHD. *Clin Vaccine Immunol.* 2008;15:147-53.
  13. Eckert J, Deplazes P. Biological, epidemiological, and clinical aspects of echinococcosis, a zoonosis of increasing concern. *Clin Microbiol Rev.* 2004;17:107-35.
  14. Bekçi TT. Diagnosis and Treatment of Human Hydatid Disease. *Eur J Gen Med.* 2012;9,(1):15-20.
  15. Saimot AG. Medical treatment of liver hydatidosis. *World J Surg.* 2001;25:15-20.

**Cite this article as:** Taki-Eldin AA. A solitary primary subcutaneous hydatid cyst in the thigh: a case report. *Int Surg J* 2016;3:411-4.