

## Original Research Article

# Comparative study of unilateral subcutaneous internal anal sphincterotomy and 02% diltiazem local application in acute fissure in ano: a study of 40 patients over 01 year

Priyanshu M. Varshney\*, Mriganko S. Ray, Tushar Nagyan, Sarvpreet S. Malhi, Digpal H. Thakore, Naresh A. Modi, Sandhya Gupta

Department of General Surgery, SGT University, Budhera, Gurugram, Haryana, India

**Received:** 02 January 2021

**Revised:** 15 January 2021

**Accepted:** 16 January 2021

### \*Correspondence:

Dr. Priyanshu M. Varshney,  
E-mail: [varshney.priyanshu.pv@gmail.com](mailto:varshney.priyanshu.pv@gmail.com)

**Copyright:** © the author(s), publisher and licensee Medip Academy. This is an open-access article distributed under the terms of the Creative Commons Attribution Non-Commercial License, which permits unrestricted non-commercial use, distribution, and reproduction in any medium, provided the original work is properly cited.

### ABSTRACT

**Background:** Two most demoralizing things in life are physical pain and bad body odour. A counted few body pains are as terrible, as oppressive and as tormenting, almost on daily basis as the pain of fresh acute fissure in ano. It pins your whole being, your awareness of life and focus of living on to your painful anus. Anal fissures are commonly encountered in routine colorectal practice. Fissure has traditionally been treated surgically. Developments in the pharmacological understanding of the internal anal sphincter have resulted in more conservative approaches towards treatment.

**Methods:** 40 patients with acute fissure in ano were divided into 02% diltiazem gel and unilateral subcutaneous internal anal sphincterotomy (USIAS) groups. Patients in the two groups were followed up subsequently.

**Results:** Anal fissures were found completely healed in 14 (70%) out of 20 patients treated with 02% diltiazem gel between 4-8 weeks. Healing was 100% with "USIAS" group. The mean healing duration of fissure was 04.45 weeks in diltiazem gel group and 03.45 weeks in "USIAS" group. 65% patients were free from pain after treatment with diltiazem gel whereas 95% patients were free from pain after treatment with "USIAS".

**Conclusions:** This prospective study, demonstrates that "USIAS" is superior to pharmacological treatment of anal fissure with good symptomatic relief, high rate of healing with very low rate of complication. Patients who are not willing to undergo surgery may be managed by 02% diltiazem as pharmacological line of management for fissure in ano.

**Keywords:** Anal fissure, Acute Fissure in ano, Lateral subcutaneous internal anal sphincterotomy, Internal anal sphincterotomy, Unilateral subcutaneous internal anal sphincterotomy

### INTRODUCTION

Wisdom is nothing more than healed pain-Robert e. Lee.<sup>1</sup>

Anal fissure is a small split or tear in the anal mucosa that may cause painful bowel movements, bleeding with streaks of blood on the stool.<sup>2</sup>

Anal fissure is a very common acute and chronic condition that is presented in majority the world population. It is the most common cause of severe anal pain. The pain may be so severe that the patient may avoid defecation for days together, there by getting severely constipated. This delay in passing stool leads to hardening of the stool, which further tears the anoderm during defecation, setting a vicious cycle.<sup>3,4</sup>

Studies on the methods of treatment of anal fissures range from conservative medical management initially to surgical intervention later on. Alas there is no general agreement on the ideal therapy for anal fissures.<sup>5</sup>

The aim and objectives of this study is to compare USIAS and pharmacological management of acute fissure in ano in respect to-healing rate: Anal pain-relieved or not and anal spasm-relieved or not. Complications: Headache, Bleeding, patient's satisfaction: Subjective.

## METHODS

A prospective study was conducted in the Department of General Surgery at SGT Medical College, Hospital and Research Institute Budhera, Gurugram. After obtaining approval from the institutional ethical committee and written informed consent from the patients, a minimum of 40 patients with acute fissure in ano aged 18 years and above were included in the study period of December 2018 to December 2019.

### Exclusion criteria

Exclusion criteria excluded patients with fissure of more than 6 weeks, anorectal malignancies and patients medically unfit for surgery.

### Study population

Patients were randomly allotted into two groups based on envelop method; group I included 20 patients with acute fissure in ano and were managed pharmacologically by diltiazem 02% gel and group II also included 20 patients and were treated by USIAS.

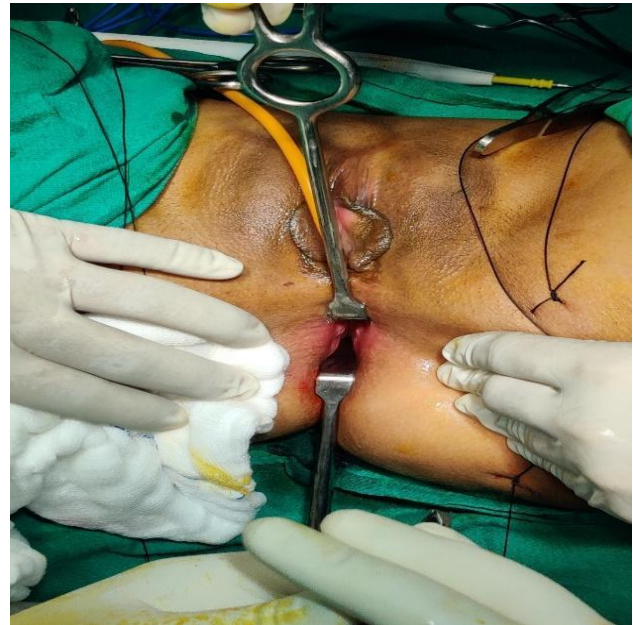
### In group I

All patients were advised local application of diltiazem 02% gel, at least 1.5 cm into the anus after sitz bath (three times a day) for 15 days, review after 15 days and observations will be made. Those patients who showed symptomatic improvement (relief from pain or bleeding) continued the treatment and were put on 01 monthly review for 06 months, and in those patients in which the symptoms persisted after 15 days of pharmacological management the patients were advised surgical intervention.

### In group II

All the patients were subjected to complete physical as well as systemic examination before surgery. Routine investigations were done and adequate medical management of associated co-morbid conditions like diabetes mellitus, hypertension and heart diseases were initialized to optimize patient's fitness for anaesthesia. Patient underwent PAC (pre-anaesthesia check-up). All cases were done preferably under SA (spinal anaesthesia) or EA (epidural anaesthesia), GA (general anaesthesia)

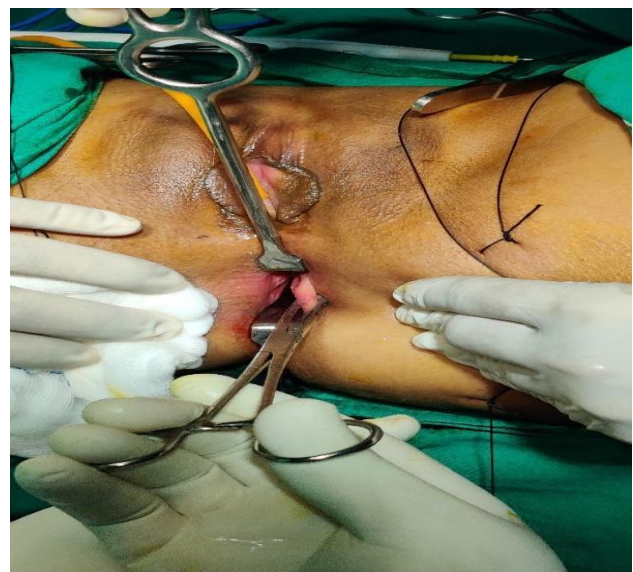was given only if spinal anaesthesia fails or if patient desired GA only.



**Figure 1: Internal anal sphincter made prominent with twin thin bladed Lagenbeck retractor with gentle stretching at 12 and 6 o'clock.**

Patients were placed in lithotomy position on the operating table and all patients were catheterized with Foley's catheter 16 F under aseptic precautions on O.T. table and catheters were secured by strapping it with dynaplast on to the thigh or lower abdomen before commencing operation.

The operation began with per rectal examination and proctoscopy and observations were noted.



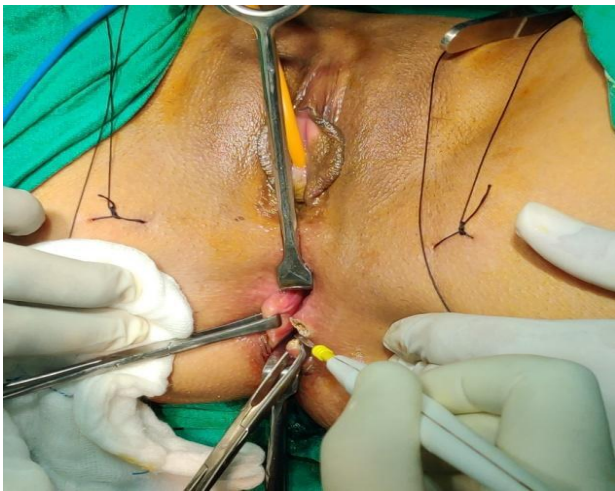**Figure 2: Allis forceps picking of internal anal sphincter at 3 o'clock.**

We have designed a fine-tuned unique and neat method of picking up Internal anal sphincter and bloodlessly dividing them precisely at 03 and or 09 o'clock, using coagulation current of monopolar cautery at 40/40 setting.


Our method is as follows: The anal orifice was put on gentle stretch by two thin Langenbeck retractors at 12 and 6 o'clock to make internal sphincter prominent.

Prominent internal sphincter was picked up by Allis tissue holding forceps either at 3 or 9 o'clock.

The internal sphincter held by Allis' forceps was gently divided either at 3 or 9 o'clock position using coagulation current of monopolar cautery.



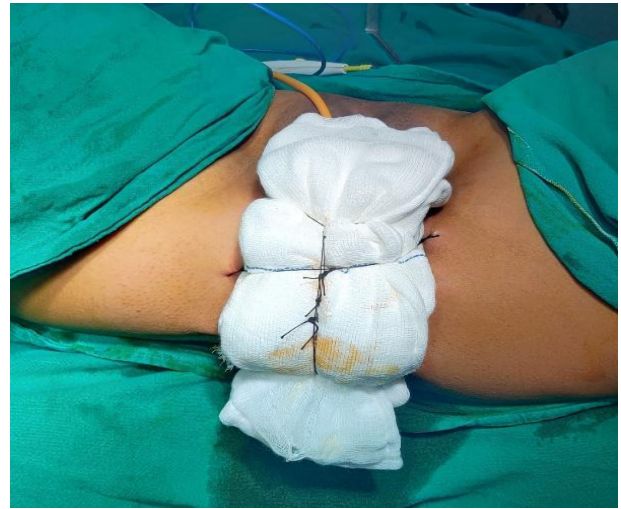**Figure 3: Internal anal sphincter at 3 o'clock, picked up by Allis forceps is divided with coagulation current of monopolar cautery.**



**Figure 4: Anal pack as designed by us with retriever thread.**

Final check for haemostasis done and the surgery was concluded with anal pack with our technique of tie over

dressings which helps in keeping a sustained and firm pressure over night for haemostasis.



**Figure 5: Our technique of tie-over dressing at the end of surgery.**

In post-op period patient is kept overnight as pillow less flat bed rest, IV fluids, single dose of broad-spectrum antibiotic and narcotic analgesic and sedation (IM tramadol 50 mg and IV Phenergan 25 mg- 08 hourly). Anal pack and urinary catheter were removed the next morning. Elderly patients were put on Tamsulosin and Dutasteride combination to ease the bladder neck. All patients were put on vegetarian diet, stool softener (Isabgol), local application of an equal volume mixture of 04 ointments we call "the magic" (Hadensa, xylocaine 02%, Proctosedyl, soframycin) was applied deep into anus, before and after sitz baths. Sitz bath was provided by hot mops in young male to avoid exposure of testes to high temperature (to safe guard spermatogenesis), for female patients and elderly males, sitz bath was given by sitting in a 'hip-sized' plastic tub of plain warm water for half an hour. Patients were discharged to home (DTH) on 5<sup>th</sup> post-operative day after digital anal dilatation or calibration (called DAD-digital anal dilatation). They were recalled after 15 days for review and to begin CAD (candle anal dilatation). CAD-I/II has a diameter 20-30% more than the diameter of the surgeon's index finger. CAD-I/II is done post defecation once a day followed by sitz bath for 1 month. This is followed by CAD-II/II which has a diameter of 20 to 30% more than CAD-I/II. CAD-II/II is used as "daily anal drill" on similar lines as of CAD-I/II. Post-defecation, ablation, followed by CAD-II/II and finishing sitz bath for 1 year. A well-formed stool (a natural anal dilator) on regular basis, we believe helps in re-training the raw internal anal sphincter wound to complete and conclude healing with non-elastic tissue like collagen (fibrosis) at a higher calibre. This is the anal calibre of a firm well-formed stool produced and delivered to anus by the rectum. We firmly believe that this kind of healing of the internal anal sphincter at a slightly higher calibre aided daily by a well-formed stool helps to avoid a vicious cycle of genesis of acute fissure

in ano. A well-formed stool is a natural dilator which most of us produce infrequently. In patients with ano-rectal conditions such as acute fissure in ano, on stool softener, a well-formed stool is never produced. Hence, we have substituted a well-formed stool with our innovative technique of CAD-I and CAD-II. Our results with CAD-I and CAD-II in all our cases have been very favourable and patient satisfying efforts.




Figure 6: CAD candle anal dilator size 1 and size 2.

**Statistical analysis**

Data were entered into Microsoft excel data sheet and was analysed using SPSS 22 version software. Independent t-test was used as the test of significance to identify the mean difference between two quantitative variables.

Categorical data was represented in the form of frequencies and proportions. Chi-square test was used as the test of significance for qualitative data.

Continuous data were represented as the mean and standard deviation. Graphical representation of data: MS Excel and MS Word were used to obtain various types of graphs such as bar diagram.

P value (probability that the result is true) of <0.05 was considered as statistically after assuming all the rules of statistical tests.

Statistical software: MS excel, SPSS version 22 (IBM SPSS Statistics, Somers NY, USA) was used to analyse data.

**RESULTS**

**Age incidence**

In our study 12 patients out of 40 belonged to age group 18-28 years (30%), 15 (37.5%) between the age group

28-38 years, 09 (22.5%) in the age group 38-48 years, and 04 (10%) in age group above 48.

**Sex incidence**

In our study of 40 patients, 23 (57.5%) patients were males and 17 (42.5%) patients were females. Male female ratio being 1.4:1.

**Follow up**

**Pain relief**

*Diltiazem gel group:* Out of 20 patients treated pharmacologically, 2 (10%) were almost free from pain and 14 (70%) had slight pain, 4 (20%) were not relieved of pain and underwent USIAS.

*USIAS group:* Out of 20 patients treated surgically, all patients were free from pain at the end of 4 weeks. As represented in Table 1.

Table 1: Pain relief.

Pain free	No. of patients	Percentage (%)	P
Diltiazem	02	10	0.001
Surgery	19	95	(S)

**Bleeding**

*Diltiazem gel group:* Out of 20 patients treated pharmacologically, bleeding was present in 06 (30%) of the patients and in 14 (70%) bleeding was absent.

*USIAS group:* No bleeding was present in 20 (100%) of the patients after surgery. As represented in Table 2.

Table 2: Bleeding.

Bleeding	Surgery	%	Diltiazem	%	P
Yes	0	0	06	30	0.01
No	20	100	14	70	(S)

**Healing**

*Diltiazem gel group:* Out of 20 patients treated pharmacologically, healing was present in 14 (70%) of the patients and 06 (30%) were not healed.

Table 3: Healing.

Healing	No. of patients	Percentage (%)	P
Diltiazem	14	70	0.007
Surgery	20	100	(S)

*USIAS group:* Out of 20 patients treated surgically, healing was present in 20 (100%) of the patients. As represented in Table 3.

## Headache

*Diltiazem gel group:* Out of 20 patients treated pharmacologically, headache was present in 01 (10%) of the patients and 19 (90%) were headache free.

*USIAS group:* Out of 20 patients treated surgically, headache was absent in 20 (100%) of the patients. As represented in Table 4.

**Table 4: Headache.**

Headache	No. of patients	Percentage (%)	P
Diltiazem	01	10	0.31
Surgery	0	0	(NS)

## DISCUSSION

In this study the commonest age group affected was 28-38 years age group (37.5%) and least affected were above 48 years age group (10%). According to Goligher the disease is usually encountered in young or middle-aged adults. In Udawadia series maximum incidence was seen in 31-40 years age group.<sup>6,7</sup>

The incidence of fissure in males was slightly greater than females. Male female ratio being 1.4: 1. It is confirmed with study from Goligher which says anal fissure is equally common in the two sexes.<sup>6</sup>

Patients receiving diltiazem gel therapy underwent domiciliary treatment and were reviewed once a week on outpatient basis. Out of 20 patients undergoing treatment with diltiazem gel 14 (70%) healed completely, in 06 (30%) patients healing did not occur. The mean duration of healing was 04.45 weeks. Duration for healing was comparatively longer than USIAS group. Study conducted by Knight et al reported a healing rate of 75% after 08-12 weeks treatment with diltiazem gel. Shrivastava et al reported a healing rate of 80% with diltiazem gel in 12 weeks.<sup>8,9</sup>

Four (20%) patients in diltiazem gel group whose fissures did not heal after 04-06 weeks of therapy underwent USIAS and fissure healed in 03-04 weeks.

Our study shows a healing rate of 100% after USIAS. Tocchhi et al reported a healing rate of 100% with internal sphincterotomy at the end of 06 weeks post-sphincterotomy review.<sup>10</sup> In our study no complications were reported in patients undergoing USIAS after follow up of patients for 01 month. Tocchhi et al report no long-term complication after internal sphincterotomy. Patient satisfaction was 96%.<sup>10</sup>

### Limitations

Comparison between diltiazem gel therapy and USIAS did not show any difference in complication as headache (p=0.31) may be due to small sample size.

## CONCLUSION

This prospective study, demonstrates that though USIAS group is the current standard treatment; many acute fissures heal with topical 02% diltiazem therapy. USIAS is superior to pharmacological treatment of anal fissure with good symptomatic relief, high rate of healing with very low rate of complication. Patients who are not willing to undergo surgery for various reasons which may be fear of surgery and pain or may be very sick to undergo a “controlled trauma under anaesthesia”-the surgical procedure itself (USIAS). Such patients may be managed by 02% diltiazem as pharmacological line of management for fissure in ano.

Here we would like to impress upon the reader our unique technique of “picking up internal anal sphincter” before dividing them bloodlessly and neatly with electrocautery. And not to forget our overnight tie over dressing and CAD-I and CAD II as mandatory “daily anal drill” in postoperative period.

## ACKNOWLEDGEMENTS

Author would like to thank Dr(Col) M.S. Ray, all surgical unit heads, our surgical colleagues and our patients.

*Funding: No funding sources*

*Conflict of interest: None declared*

*Ethical approval: The study was approved by the Institutional Ethics Committee*

## REFERENCES

1. Corman M, Nicholls RJ, Fazio VW, Bergamaschi R. Corman's colon and rectal surgery 6<sup>th</sup> ed. 2013;346.
2. Ram E, Vishne T, Lerner I, Dreznik Z. Anal dilatation versus left lateral sphincterotomy for chronic anal fissure: a prospective randomized study. Tech Coloproctol. 2007.
3. Ahmad N, Aziz M, Faizullah. Closed lateral internal sphincterotomy under local anesthesia in OPD in the treatment of chronic anal fissure. Ann King Edward Med Uni. 2004;10:11-2.
4. Farooq A, Niaz Z. Comparative study of lateral internal sphincterotomy verses topical glyceryl trinitrate for treatment of Fissure-in-ano. Ann King Edward Med Uni. 2003;9:278-81.
5. Russell RCG, Williams NS, Bulstrode CJK. Bailey and Love's Short Practice of Surgery 23<sup>rd</sup> Edition. 2000;1125-7.
6. Goligher J. Anal Fissure, Surgery of the Anus, Rectum and Colon. AITBS, 5<sup>th</sup> Edition. 1992;50.
7. Udawadia TE. The prophylaxis of fissure in ano. NIJS. 1978;40(11):560.
8. Knight JS, Birks M, Farouk R. Topical Diltiazem ointment in the treatment of chronic anal fissure. Br J Surg. 2001;88(4):553-6.
9. Shrivastava UK, Jain BK, Kumar P, Saifee Y. A comparison of the effects of Diltiazem and Glyceryl

trinitrate ointment in the treatment of chronic anal fissure: a randomized clinical trial. *Surg Today.* 2007;37(6):482-5.

10. Tocchi A, Mazzoni G, Miccini M, Cassini D, Bettelli E, Brozzetti S. Total lateral sphincterotomy for anal fissure. *Int J Colorectal Dis.* 2004;19(3):245-9.

**Cite this article as:** Varshney PM, Ray MS, Nagyan T, Malhi SS, Thakore D, Modi N, et al. Comparative study of unilateral subcutaneous internal anal sphincterotomy and 02% diltiazem local application in acute fissure in ano: a study of 40 patients over 1 year. *Int Surg J* 2021;8:530-5.