

Original Research Article

A new self-made electric hook for laparoscopic inguinal hernia repair

Hongfu Lin^{1*}, Yu Zhao², KunSong Wang¹, Caixing Huang¹, Zihua Li¹, Lishuo Yang¹

¹Department of General Surgery, Shenzhen Shekou People's Hospital, Shenzhen, Guangdong, China

²Shenzhen Surg Science Medical Tech. Co., Ltd. Shenzhen, Guangdong, China

Received: 14 December 2020

Revised: 18 February 2021

Accepted: 01 March 2021

*Correspondence:

Dr. Hongfu Lin,

E-mail: linhongfu@21cn.com

Copyright: © the author(s), publisher and licensee Medip Academy. This is an open-access article distributed under the terms of the Creative Commons Attribution Non-Commercial License, which permits unrestricted non-commercial use, distribution, and reproduction in any medium, provided the original work is properly cited.

ABSTRACT

Background: Current investigation was conducted to explore the clinical application of self-made electric hook in laparoscopic indirect inguinal hernia repair.

Methods: Randomized controlled trial was conducted that compared two groups of patients who underwent laparoscopic inguinal hernia repair from 2013 to 2017 at our institution. A laparoscopic indirect inguinal hernia repair with beak-like electrocoagulation instrument as modified trans-abdominal preperitoneal prosthesis was performed on 42 patients. As a comparison, 40 patients with traditional TAPP were collected and analyzed. In the end, we compared the operation time, blood loss, complications, and recurrence of two groups.

Results: 82 patients have successfully completed surgery without conversion to open inguinal hernia repair. Patients were follow-up visited for 18 to 78 months, and no recurrence was found. 1 case of scrotal edema occurred using a self-made electric hook in modified TAPP, and cured by conservative treatment. In traditional TAPP group, there was 1 case of postoperative seroma, which cured by conservative treatment. There was no significant difference between these 2 groups in terms of complications and recurrence ($p > 0.05$). However, the differences in operation time and blood loss were significant ($p < 0.05$).

Conclusions: Self-made electrical hook showed in laparoscopic inguinal hernia repair of indirect inguinal hernia has the advantages of shortening operation time, reducing bleeding, easing the difficulty of operation, and improving the safety of surgery, it is worthy of further clinical application.

Keywords: Hernia, Inguinal, Herniorrhaphy, Laparoscopes

INTRODUCTION

The inguinal hernia was first reported 3000 years ago. Early treatment through abdominal approach, which led to the low survival rate from a century ago.¹ Doctors declared that the radical cure of hernias should be undertaken by abdominal section.² However, Marcy considered³ that those methods just sewing up a hole, rather than reconstructing the abdominal defect. Thus, these methods never became popular. Recently surgery has dramatically changed with various techniques introduced to reduce the incidence and other complaints.

One of the most important technique is the laparoscopic approach in minimally invasive surgery since the 1980s.⁴ This technique pioneered minimally invasive surgery, dramatically reduced the pain of the patient. Laparoscopy now represents a valid alternative to traditional open techniques, and many reports have demonstrated that this approach is benefited to a lower incidence of postoperative pain and permits more rapid recovery of the physical activity than conventional procedures.⁵⁻¹¹ The first laparoscopic ventral hernia repair was reported by Leblanc and Booth based on the principles of open preperitoneal repair described by Rives and Stoppa.¹¹⁻¹⁴ With increasing experience in laparoscopy and

development of new tools, laparoscopic ventral hernia repair has become an accepted technique and has the potential to become the procedure of choice with all the advantages of minimally invasive surgery.

At present, the trans-abdominal preperitoneal prosthesis (TAPP) is a widely used minimally invasive surgical method. This method has achieved good results in the treatment of inguinal eggplant, but literature reports tend to focus on multicenter, retrospective studies, and to assess different techniques simultaneously.¹⁵⁻²⁰ Few people paid attention to the technical difficulties: Separate and suture the peritoneum. The learning curve is too long for the thousands of beginners, who are difficult to facing complex conditions. For example, big hernial sac, hernial sac in the scrotum, recurrent incarcerated hernia patients, the peritoneum is thickened at the circumflexion and anatomical scores are difficult to separate using an electric hook or an ultrasonic knife, which is easy to damage the structure of the inferior epigastric artery and the vas deferens.

Here we introduced a self-made electric hook to solve the technical problem of cystic sac separation, shorten TAPP surgery time, and reduce the difficulty of surgery. This article has analyzed Shenzhen Shekou people's hospital of Guangdong province from January 2013 to December 2017, 42 patients with application of self-made electric hook laparoscopic inguinal hernia repair and 40 patients with traditional TAPP in the same period.

METHODS

A total of 54 patients with indirect inguinal hernia were selected, including 75 males, 7 females, age 19 to 81, mean age 53 years old between January 2013 and December 2017 in Shenzhen Shekou people's hospital of Guangdong province. Patients were randomized to these groups with a blind envelope system, in which the use of self-made electric hook laparoscopic repair of inguinal hernia (modified TAPP) were 42 patients, and 40 patients used traditional laparoscopic inguinal hernia repair (TAPP). Follow-up visits were conducted by an additional surgeon blinded, as well as the patient to what sort of fixation was used.

Operative procedure

All patients were performed under general anesthesia with tracheal intubation in the supine position at low head 10-15°. The surgeon stood on the opposite side of the affected side of the patient, and the assistant stood in front of the lens. Pneumoperitoneum was established with a needle placed in the umbilicus. CO₂ filled to keep the pressure at 12-14 mmHg (1 mmHg=0.133 kPa). Generally, a 10 mm trocar placed in the umbilicus as the optical port, where a 30° telescope was used for visualization of the peritoneal cavity. Subsequent ports, two 5 mm trocars were placed at the lateral rectus abdominis approximately contralateral level and the

contralateral rectus abdominis under vision following the principle of triangulation as manipulation holes, respectively.

The modified TAPP procedure

The modified TAPP procedure used a special self-made electric hook as shown in (Figure 1). The position, size and content of hernia were investigated and observed after the telescope entered the abdominal cavity (Figure 2). The indirect hernia sac was dissected in a low position at the internal ring opening. The hernia sac of indirect hernia is lateral to the inferior epigastric artery and enters the inguinal canal through the opening of the internal ring, and the hernia sac was transected in the lower position of the internal ring opening used the self-made electric hook. The posterior part of the hernia sacs should be paid attention to protecting the vas deferens and spermatic vessels (Figure 3). The hernia sac was medially separated into the Retzius gap to reveal the pubic symphysis and the pubic ligament (Cooper's ligament) as shown in (Figure 4). Then it was separated outwardly into the Bogros gap and skeletal socket gap (Figure 5). The indirect hernia sac was separated from vas deferens that behind hernia sac and spermatic vessels 5-6 cm along the horizontal direction of the internal circular opening, "abdominal wall of the spermatic cord" was performed (Figure 6). The separation range of preperitoneal space: dissection was continued internally to the pubic symphysis and crossed the midline, lateral to the iliopsoas muscle and the anterior superior iliac spine. Meanwhile, the upper part was separated 2 to 3 cm above the conjoint tendon and inferiorly beyond the pectineal ligament 2 cm, the inferolateral of separation reached to the "abdominal wall of the spermatic cord". The polypropylene mesh 10cmx15cm was used to completely cover the preperitoneal space. The mesh was fixed on the conjoint tendon, rectus abdominis and pectineus ligaments with a screw (Figure 7). A 3-0 absorbable suture was used to close the peritoneum (Figure 8).

Statistical analysis

The operative time, blood loss, complications, and recurrence of these two groups were compared. Findings regarding the patients treated and their subsequent follow-up evaluations were collected and stored in a Microsoft access database. Data processing method adopted SPSS13.0 software, comparison of measurement data adopted t-test, comparison of count data adopted χ^2 test, $p < 0.05$ was considered statistically significant.

RESULTS

All 82 patients completed the operation without conversion to laparotomy, of which 42 patients underwent improve TAPP procedure and 40 patients underwent traditional TAPP procedure. At the end of both procedures, antibiotics were routinely used to prevent infection after the operation. The fluid infusion treatment

was started 6 hours after the operation, and general diet resumed 24 hours later. The patients had been observed in hospital for 3 to 8 days with a mean day of 4.5 days, followed-up for 18 to 78 months. All patients had no recurrence. One complication case of postoperative seroma was cured by conservative treatment in traditional TAPP group, and one case of scrotal edema after modified TAPP was cured by conservative therapy. The operative time, intraoperative blood loss, complications, and recurrence of these two groups were compared (Table 1).

Table 1: Comparison of surgical indexes between two groups of patients.

	Modified TAPP	Traditional TAPP	P value
Cases number	42	40	
Operation time (min)	45±10	62±14	<0.05
Bleeding amount (ml)	3.5±2.0	8±2.5	<0.05
Complication (%)	1(2.4)	1(32.5)	>0.05
Relapses (%)	0	0	>0.05




Figure 1: Photo of the self-made electric hook.

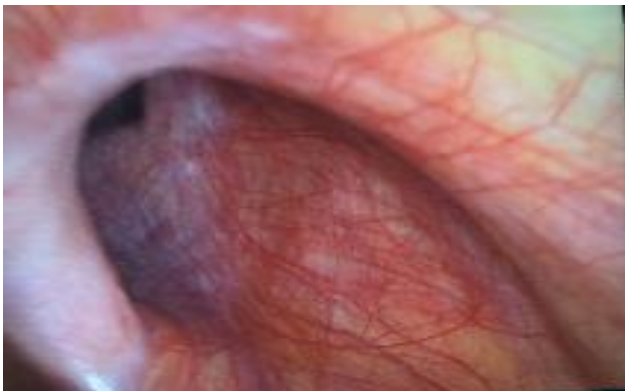


Figure 2: The morphology of hernia.

DISCUSSION

In 1982, Ger first reported the application of laparoscopic herniorrhaphy.²¹ The essence of laparoscopic inguinal

hernia repair was to perform "preperitoneal repair" under the condition of "image magnification" by using "laparoscopic instruments" and through the true "posterior approach".²² In 1990, Schultz et al proposed the "transabdominal preperitoneal repair" in the series of laparoscopic repair, who were the earliest people attempt to retrieve TAPP.²³

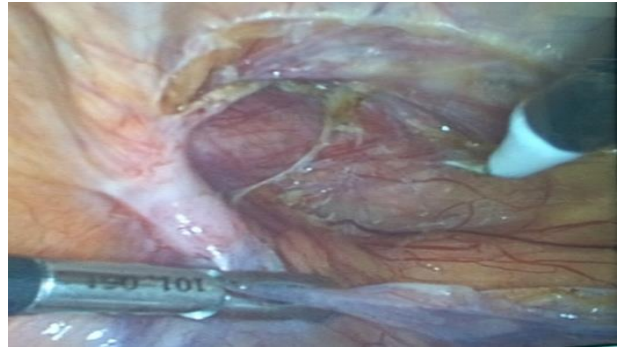


Figure 3: The indirect hernia sac was dissected in a low position at the internal ring opening.

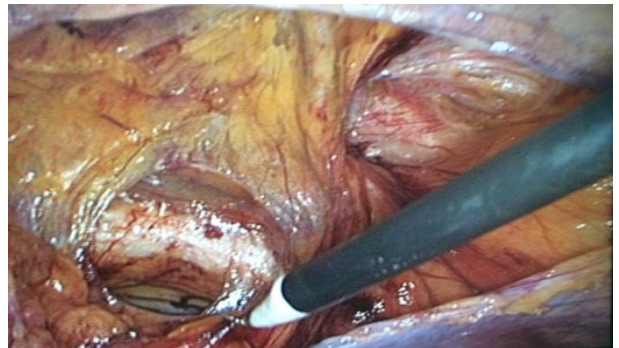


Figure 4: The hernia sac was medially separated into the Retzius gap to reveal the pubic symphysis and the pubic ligament.

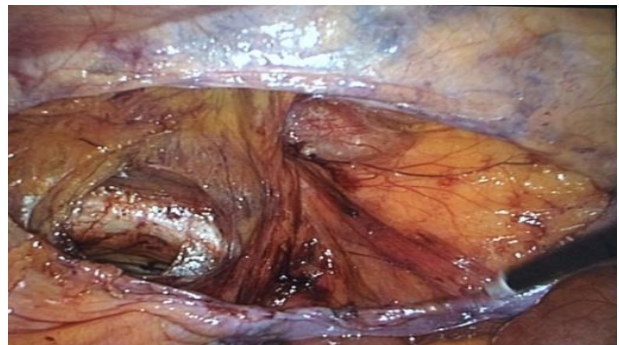


Figure 5: Sac was separated outwardly into the Bogros gap and skeletal socket gap.

They incised the peritoneum, filled the ring with a polypropylene patch and covered the defect, then closed the peritoneal rift with a clip. At present, TAPP is a widely used surgical method to deal with inguinal hernia. This method has achieved good results in the treatment of

inguinal hernia. But there are two technical difficulties: the separation of the sac and the closure of the peritoneum. The separation of the hernia sac is easier for the direct inguinal hernia. However, the separation of indirect inguinal hernia is more difficult, which need to separate hernia sac near the spermatic cord and vas deferens. And it is difficult to separate the separation spermatic cord from the hernia sac completely for some diseases with a long course, repeated incarceration, large hernia sac and dense adhesion to the scrotum, hernia sac, and spermatic cord. In this procedure, there is a lot of bleeding, which is easy to produce side injury.

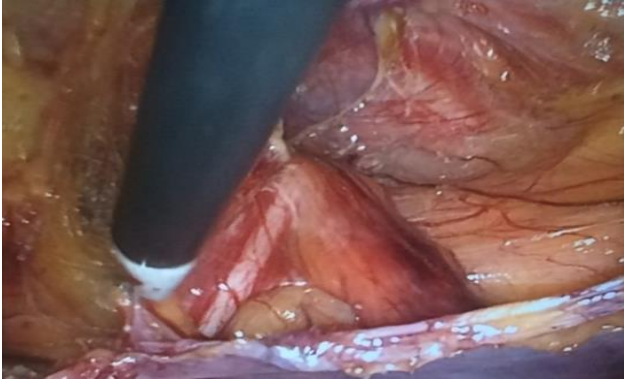


Figure 6: The indirect hernia sac was separated from vas deferens and spermatic vessels.



Figure 7: Mesh has covered the preperitoneal space.

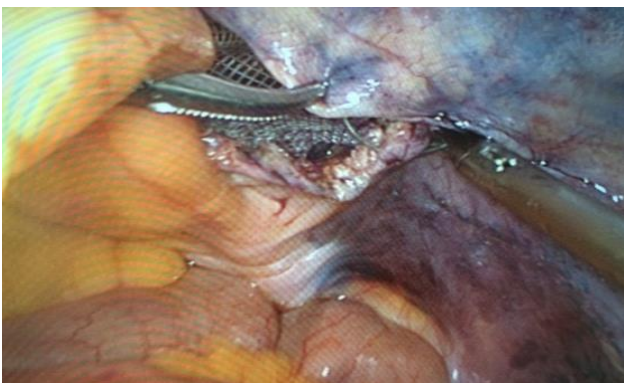

Figure 8: The peritoneum was closed with 3-0 suture.

Forced dissection may also cause postoperative hematoma, which increases the difficulty and operation time. Thus, we chose a self-made laparoscopic electric hook to deal with this case. Ultra-fine cutting and good coagulation can be achieved through the high current density at the tip of an electric hook. At the same time, the new procedure changed traditional TAPP operation and effectively decreased the difficulty of laparoscopic indirect inguinal hernia sac separation. This new procedure significantly decreased operation time, bleeding, and improved the safety of the operation. As shown in (Table 1), the differences in operation time and blood loss between these two groups were performed using SPSS, and the result statistically significant ($p < 0.05$).

The Hewlett-Packard triangle, inguinal canal ring orifice, and femoral ring were showed by separating and dissecting the weak area of the "muscle pubic hole". This area can be covered by a 15cmx10cm patch completely. The recurrence rate of two groups was analyzed and $p > 0.05$ was not considered statistically significant. In addition, we cut the hernia sac in the lower position of the inner circular opening and left much more peritoneum, which avoided the effect on the closure of the peritoneum. Thus, no peritoneum tear was found when the peritoneum was closed. In current study, an innovative surgical instrument improvement method was proposed and proved to be safe and effective. However, further multi-center experiments with large sample size are needed.

CONCLUSION

A self-made electric hook was applied to transversely cut the hernia sac at the lower position of the internal circular opening in laparoscopic inguinal indirect hernia repair (modified TAPP). Because the hernia sac did not need to be separated completely, there was no excessive separation, injury and bleeding, which makes the operation safe and reliable. Compared with the traditional method of laparoscopic inguinal oblique repair (TAPP), the modified TAPP reduced operation time, bleeding volume and difficulty. Therefore, modified TAPP is a method worthy of promotion and application in the clinic.

ACKNOWLEDGEMENTS

Authors are thankful to the department of general surgery, Shenzhen Shekou People's Hospital for extending support in current research.

Funding: No funding sources

Conflict of interest: None declared

Ethical approval: The study was approved by the Institutional Ethics Committee

REFERENCES

1. Khoury N. A comparative study of laparoscopic extraperitoneal and transabdominal preperitoneal herniorrhaphy. *J laparoendosc Surg.* 1995;5:349-55.
2. Tait L. A discussion of treatment of hernia by median abdominal section. *Br Med J.* 1891;2:685-91.
3. Marcy HO. The radical cure of hernia by the antiseptic use of carbolized catgut ligatures. USA: Riverside Press; 1879.
4. Semm K. Endoscopic appendectomy. *Endoscopy.* 1983;15:59-64.
5. Berndsen F, Arvidsson D, Enander LK. Postoperative convalescence after inguinal hernia surgery: prospective, randomized multicenter study of laparoscopic versus Should inguinal hernia repair in 1042 patients. *Hernia.* 2002;6:56-61.
6. Bueno J, Serralta A, Planells M, Rodero D. Inguinodynia after two inguinal herniorrhaphy methods. *Surg Laparosc Endosc Percutan Tech.* 2004; 14:210-4.
7. Mahon D, Decadt B, Rhodes M. Prospective randomized trial of laparoscopic (transabdominal preperitoneal) vs open (mesh) repair for bilateral and recurrent inguinal hernia. *Surg Endosc.* 2003;6:1386-90.
8. Onofrio L, Cafaro D, Manzo F, Cristiano SF. Tension-free laparoscopic versus open inguinal hernia repair. *Minerva Chir.* 2004;59:369-77.
9. Poobalan AS, Bruce J, King PM, Chambers WA, Krukowski ZH, Smith WC. Chronic pain and quality of life following open inguinal hernia repair. *Br J Surg.* 2001;88:1122-6.
10. Quilici PJ, Greaney EM, Quilici J, Anderson S. Laparoscopic inguinal hernia repair: optimal technical variations and results in 1,700 cases. *Am Surg.* 2000;66:848-52.
11. Smith JR, Demers ML, Pollack R, Gregory S. Prospective comparison between laparoscopic preperitoneal herniorrhaphy and open mesh herniorrhaphy. *Am Surg.* 2001;67: 115-7.
12. LeBlanc KA, Booth WV. Laparoscopic repair of incisional abdominal hernia using expanded polytetrafluoroethylene: preliminary findings. *Surg Endosc.* 1993;3:39-41.
13. Rives J, Pire J, Flament JB, Palot JP, Boby C. Treatment of large eventration. New therapeutic indications apropos of 322 cases. *Chirurgie.* 1985; 111:215-25.
14. Stoppa RE. The treatment of complicated groin and incisional hernia. *World J Surg.* 1989;13:545-54.
15. Catarci M, Carlini M, Gentileschi P, Santoro E. Major and minor injuries during the creation of pneumoperitoneum: a multicenter study on 12,919 cases. *Surg Endosc.* 2001;15:566-9.
16. Duron JJ, Hay JM, Msika S, Gashard D, Domergue J, Gainant A, Fingerhut A. Prevalence and mechanisms of small intestinal obstruction following laparoscopic abdominal surgery: a retrospective multicenter study. *Arch Surg.* 2000;135:208-12.
17. Felix E, Scott S, Crafton B, Geis P, Duncan T, Sewell R, McKernan B. Causes of recurrence after laparoscopic hernioplasty: a multicenter study. *Surg Endosc.* 1998;12:226-31.
18. Leibl BJ, Schmedt CG, Kraft K, Ulrich M, Bittner R. Scrotal hernias: a contraindication for an endoscopic procedure? Results of a single-institution experience in transabdominal preperitoneal repair. *Surg Endosc.* 2000;14:289-92.
19. Mahon D, Decadt B, Rhodes M. Prospective randomized trial of laparoscopic (transabdominal preperitoneal) vs open (mesh) repair for bilateral and recurrent inguinal hernia. *Surg Endosc.* 2003;17: 1386-90.
20. McCormack K, Wake B, Perez J, Fraser C, Cook J, McIntosh E, et al. Laparoscopic surgery for inguinal hernia repair: systematic review of effectiveness and economic evaluation. *Health Technol Assess.* 2005;9: 1-203.
21. Ger R. The management of certain abdominal hernia by intraabdominal closure of the neck of the sac. *Ann R Coll Surg Engl.* 1982;64:342-4.
22. Feng B, He ZR, Li JW. Feasibility of incremental laparoscopic inguinal hernia repair development in China, all 11-year experience. *J Am Coll Surg.* 2013; 216:258-65.
23. Schultz L, Graber J, Pietrafina J. Laser laparoscopic herniorrhaphy: a clinical trial preliminary results. *J Laparoendosc Surg.* 1990;1: 41-5.
24. Arber A, Klein E, Bruce S, Sankoh S, Mohideen P. Metformin-glibenclamide versus metformin plus rosiglitazone in patients with type 2 diabetes inadequately controlled on metformin monotherapy. *Diabetes Obes Metab.* 2006;8(2):156-63.
25. O'Brien C. Drug addiction and drug abuse. In: Brunton LB, Lazo JS, Parker KL, eds. *Goodman & Gilman's the pharmacological basis of therapeutics.* 11th ed. NY: McGraw-Hill; 2005:607-29.
26. National Cancer Institute, fact sheet: targeted cancer therapies, 2012. Available at <http://www.cancer.gov/cancertopics/factsheet/Therapy/targeted#q1>. Accessed on 9 June 2014.

Cite this article as: Lin H, Zhao Y, Wang K, Huang C, Li Z, Yang L. A new self-made electric hook for laparoscopic inguinal hernia repair. *Int Surg J* 2021;8:1080-4.