

Case Report

Perforated sigmoid diverticulitis masquerading as multiple intra and extra abdominal disseminated abscesses

Gary S. L. Hung*, Margaret M. Mansbridge, Michelle L. Cooper, Cu Tai Lu

Department of Surgery, Gold Coast University Hospital, Southport, QLD, Australia

Received: 07 December 2020

Revised: 01 February 2021

Accepted: 05 February 2021

*Correspondence:

Dr. Gary S. L. Hung,

E-mail: garysama@hotmail.com

Copyright: © the author(s), publisher and licensee Medip Academy. This is an open-access article distributed under the terms of the Creative Commons Attribution Non-Commercial License, which permits unrestricted non-commercial use, distribution, and reproduction in any medium, provided the original work is properly cited.

ABSTRACT

Abscess formation in perforated diverticulitis is most commonly confined to the pelvis, with other intraperitoneal and extraperitoneal locations rarer in the literature. Presented here is the case of a 63-year-old male who was diagnosed with perforated diverticulitis which manifested in multiple intra- and extra-abdominal abscesses. These were identified on abdominopelvic computed tomography to include a presacral abscess, bilateral psoas abscesses, a large left flank abscess located between the internal and external oblique muscles, as well as osteomyelitis of the S1 vertebra. To the best of the authors' knowledge, this is the first reported case in the literature with this disseminated constellation of abscesses secondary to acute perforated diverticulitis.

Keywords: Perforation, Abscess, Diverticulitis

INTRODUCTION

Abscess formation is a known complication of perforated diverticulitis. The majority of these abscesses are confined to the pelvis, with the remainder usually occurring in the mesocolic region.¹ Other rarer sites of abscess formation secondary to acute perforated diverticulitis include the liver, adnexa, lung, brain, and spine.² There are also rare case reports of abdominal wall abscesses in the literature.³ The authors present a case of diffuse multifocal intra- and extra-abdominal abscess formation secondary to perforated diverticulitis, the constellation of which has not previously been reported in the literature to the best of the authors' knowledge.

CASE REPORT

This 63-year-old man with a background of severe chronic obstructive airway disease (COPD), peripheral vascular disease, and atrial fibrillation on rivaroxaban had recently been commenced on one week of high dose prednisolone for management of his COPD. His

presentation to the emergency department was prompted by right inguinal pain and swelling secondary to a fat containing indirect inguinal hernia. On obtaining further history he revealed six weeks of abdominal pain and new onset pneumaturia, and four days of diarrhea. The patient had recently been commenced on oral trimethoprim/sulfamethoxazole by his local medical officer for urinary frequency and urgency.

He was tachycardic, maintaining a normal blood pressure, and afebrile. A well circumscribed area of erythema was noted on the patient's left flank. Abdominal examination revealed tenderness in the right lower quadrant. Serum white blood cell count was $30.1 \times 10^9/l$ and C-reactive protein (CRP) was 276 mg/l. The patient had a mild acute kidney injury with a serum creatinine of 126 $\mu\text{mol/l}$, eGFR 52 ml/min, and serum potassium of 5.5 mmol/l. Urine microscopy showed bacteria, and later cultured *Escherichia coli*.

Contrast enhanced abdominopelvic computed tomography (CT) noted diverticular disease with

segmental thickening of the sigmoid colon (Figure 1), and revealed multiple disseminated abscesses.

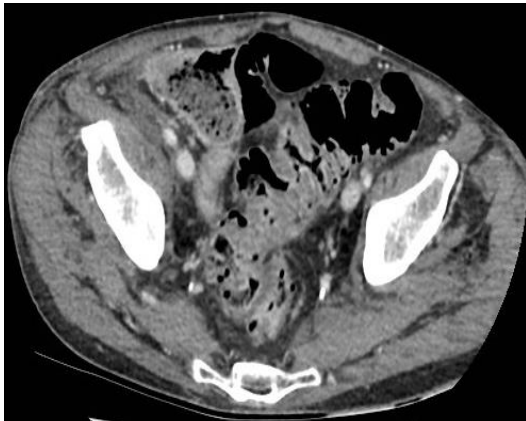


Figure 1: Portal venous phase CT showing segmental sigmoid colon thickening.

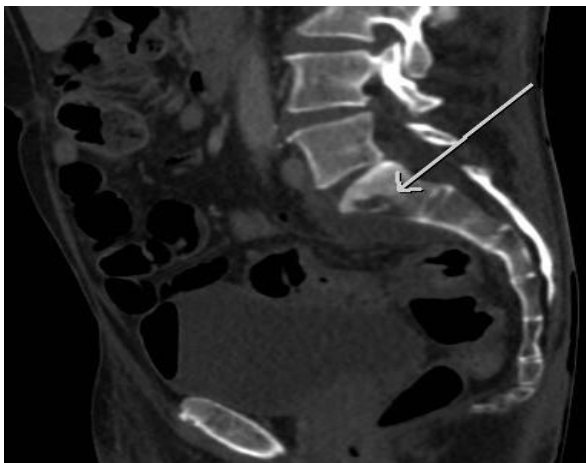


Figure 2: CT showing erosive changes of the S1 vertebra concerning for osteomyelitis.

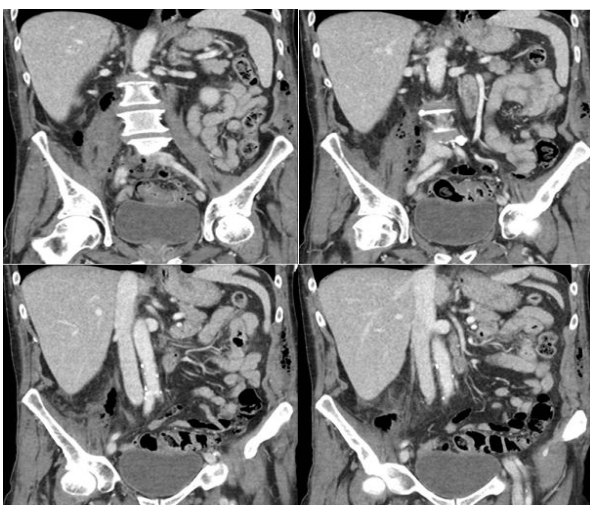


Figure 3: CT illustrating the extensive gas locules and inflammatory changes involving the right psoas muscle.

A presacral gas containing collection was noted with associated erosive changes of the S1 vertebra, raising the concern for osteomyelitis (Figure 2). Extensive gas locules and inflammatory changes were seen involving the right psoas muscle (Figure 3), with a small volume of inflammatory fluid noted within the right paracolic gutter. Small locules of gas were also noted at the origin of the left psoas muscle. A rim enhancing collection was identified at the left flank between the internal and external oblique muscles (Figure 4), and tracking down to the left gluteal region. Gas was also present within the urinary bladder prior to instrumentation. CT also confirmed the patient's right inguinal hernia to be fat containing.

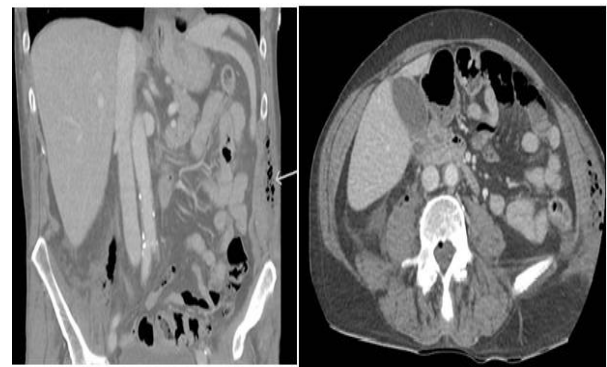


Figure 4: CT illustrating the rim enhancing collection identified at the left flank between the internal and external oblique muscles.

Blood cultures were sent and the patient was commenced on broad spectrum intravenous antibiotics, with colorectal surgery, urology, and infectious disease inpatient reviews. A transthoracic echocardiogram was performed which ruled out valvular vegetations. Ongoing tachycardia, increased abdominal wall cellulitis, and ongoing right sided abdominal pain on the second day of admission prompted the decision for a diagnostic laparoscopy and operative management.

Laparoscopic assessment of the ascending colon and appendix was grossly unremarkable. The descending colon was adherent to the lateral abdominal wall and bladder, and this was mobilised. The left retroperitoneal collection was entered and pus drained. No defined collection was appreciated on the right. The presacral abscess cavity was opened and washed out laparoscopically. Perforation was identified at the rectosigmoid junction, and a Hartmann procedure was performed. Peritoneal lavage was performed and two drains placed under vision in the left paracolic gutter and at the rectal stump.

The patient was monitored in the intensive care unit postoperatively, and intravenous antibiotics continued under the guidance of infectious disease physicians. Abdominal drains were removed on day six postoperatively. The patient continued to recover on the

surgical ward, and intravenous antibiotics were continued for two weeks, followed by 12 weeks of oral antibiotics for treatment of the patient's likely S1 osteomyelitis.

A persistently high CRP of 156 mg/l and ongoing right sided abdominal pain on day 11 postoperatively prompted a repeat abdominopelvic CT which revealed significant progression in the size and number of collections within the left lateral abdominal subcutaneous tissue extending between the left internal and external oblique muscles. CT also noted significant internal increase in size of the right iliopsoas gas containing collection, now extending into the previously identified right inguinal hernia. The presacral collection and erosive S1 changes were stable. Ultrasound guided aspiration of the right inguinal collection was performed, and cultured *Escherichia coli*.

CT guided drainage and pigtail drain insertion into the right iliopsoas collection was performed four days later, which again cultured *Escherichia coli*, and repeat ultrasound guided aspiration of the right inguinal and left flank abscesses were performed the following day, culturing *Escherichia coli* with increased antibiotic resistance. The left flank drainage also cultured *Prevotella bivia* in addition to a similarly resistant *Escherichia coli* cultured on the contralateral side. Ongoing clinically fluctuant and erythematous collections prompted operative intervention the following day. Operative findings included a 20×40cm right sided cavity extending from the ASIS down into the scrotum, and a 25×4 cm left flank cavity. These were drained, washed out, and Penrose drains inserted.

Erythema and Penrose drain output improved over the following days on broad spectrum intravenous antibiotics and serum CRP continued to fall. The patient was discharged home on day 24 of admission with his Penrose drains in situ and ongoing outpatient intravenous antibiotics under the management of the infectious disease team.

He was reviewed in the Colorectal outpatient clinic two weeks post discharge and his Penrose drains were removed and antibiotics ceased.

Three months later, he represented to the emergency department with a three-day history of left lower quadrant pain and 24 hours of purulent peristomal discharge. An elevated serum white blood cell count of $21.3 \times 10^9/L$ and CRP of 135 mg/L prompted a contrast enhanced portal venous abdominopelvic CT. This showed bowel wall thickening and mural hyperaemia in relation to the colostomy site with extensive associated inflammatory change in keeping with a phlegmon, and features concerning for osteomyelitis at the L5 endplate and S1 vertebral body.

The patient was commenced on broad spectrum intravenous antibiotics and an MRI and bone scan

confirmed osteomyelitis and discitis at L5/S1. The patient's bone scan also revealed incidental osteomyelitis of the left heel, associated with a long standing left heel ulcer for which he had recently undergone an angioplasty and SFA stent. Vascular opinion was sought and the patient was managed conservatively for this.

The patient's peristomal wound swab grew non-specific mixed enteric bacteria and scant candida. Stool microscopy was negative and *Clostridium difficile* testing was also negative. Serial blood cultures and a urine culture were also negative.

The patient was managed as colitis by the Colorectal team and osteomyelitis under the guidance of the infectious diseases team, and discharged on day eight of admission with a further 22 days of intravenous antibiotics in the community under the care of the infectious disease team. He was then transitioned onto a further two months of oral ciprofloxacin and clindamycin. On outpatient infectious disease clinic review two months later, and after completion of his antibiotic regimen, the patient's CRP had fallen to 14 mg/l. He is continuing to be reviewed in the outpatient vascular clinic for his left heel ulcer which is improving without further intervention.

DISCUSSION

This case highlights the successful management of a patient with perforated diverticulitis and multifocal abscess formation, with initial operative management with a Hartmann procedure followed by ongoing intervention to gain source control of the multiple extraperitoneal abscesses. Involvement of an infectious disease physician is crucial in aiding management with targeted antibiotic regimens to control the progressively resistant *E. coli* cultured, and progressive osteomyelitis. Infectious disease involvement also facilitated patient discharge with ongoing outpatient intravenous antibiotics. Oral steroids may have played a role in the patient's disease progression, and accounted for the patient appearing clinically well despite his CT findings.

CONCLUSION

Complicated diverticulitis can present without classical symptoms and can masquerade as disseminated abscesses distal to the pathological site either intra- and/or extra-abdominally. CT is the imaging modality of choice in evaluating the extent of secondary complications of acute perforated diverticulitis. Multifocal abscess formation can occur even in the absence of gross intra-abdominal free air on CT multifocal abscess formation secondary to acute perforated diverticulitis should be managed with source control and infectious disease physician input.

Funding: No funding sources

Conflict of interest: None declared

Ethical approval: Not required

REFERENCES

1. Singh B, May K, Coltart I, Moore NR, Cunningham C. The long-term results of percutaneous drainage of diverticular abscess. *Ann Roy Col Surge Eng.* 2008;90(4):297-301.
2. Onur MR, Akpınar E, Karaosmanoglu AD, Isayev C, Karcaaltincaba M. Diverticulitis: a comprehensive review with usual and unusual complications. *Insights Into Imaging.* 2017;8(1):19-27.
3. Vasileios R, Anna G, Christos L, Asimina T, Sofia P, Vasiliki K. Abdominal wall abscess due to acute perforated sigmoid diverticulitis: a case report with MDCT and US findings. *Case Rep Radiol.* 2013;2013.

Cite this article as: Hung GSL, Mansbridge MM, Cooper ML, Lu CT. Perforated sigmoid diverticulitis masquerading as multiple intra and extra abdominal disseminated abscesses. *Int Surg J* 2021;8:1000-3.