

Original Research Article

Reconstruction of pressure ulcers with flaps in a tertiary care centre

Ravikumar Gopalakrishnan*, Manoharan Rajalingam,
Balamuralee Rajagunasekaran, Ramya Esakimuthu

Department of Plastic and Reconstructive Surgery, Thanjavur Medical College, TN. Dr. MGR Medical University, Tamilnadu, India

Received: 28 November 2020

Revised: 17 January 2021

Accepted: 19 January 2021

*Correspondence:

Dr. Ravikumar Gopalakrishnan,
E-mail: gravikumar1962@gmail.com

Copyright: © the author(s), publisher and licensee Medip Academy. This is an open-access article distributed under the terms of the Creative Commons Attribution Non-Commercial License, which permits unrestricted non-commercial use, distribution, and reproduction in any medium, provided the original work is properly cited.

ABSTRACT

Background: Patients with pressure ulcers have multiple risk factors and develop various post-operative complications. The purpose of the study is to analyse the outcome of management of pressure ulcers with different flaps.

Methods: This is a retrospective study done in a series of patients who underwent flap reconstruction of pressure ulcers between 2016 and 2019 in the Department of Plastic and Reconstructive Surgery, Thanjavur medical college, Tamilnadu, India. Totally twenty-eight patients were operated for stage III and stage IV pressure ulcers with various types of flaps depending upon the site of pressure ulcers. Post operatively flaps were monitored for viability and post-operative complications.

Results: Total 22 males, 5 females and 1 male child had undergone surgery for pressure ulcers. The age group ranged from 3 years to 62 years with an average of 37 years. The sites of the pressure ulcers were as follows: 14 (50%) sacral; 10 (35.7%) ischial; 3 (10.7%) trochanteric and 1 (3.6%) multiple pressure ulcers. Most of the patients (60.7%) had traumatic paraplegia and developed pressure ulcers. 18 patients with stage III and 10 patients with stage IV pressure sores were operated with different flaps. Duration of treatment ranged from 29 to 118 days. The mean hospitalization was 78 days.

Conclusions: Effort is needed to prevent the development of pressure ulcers through the early identification of risk and early implementation of preventive measures. Flap cover is ideal to prevent recurrence. Post-operative follow-up with physiotherapy and rehabilitation are very important.

Keywords: Pressure ulcers, Surgery, Flap cover

INTRODUCTION

A pressure ulcer (PU) is defined as 'localised injury to the skin and/or underlying tissue usually over a bony prominence, as a result of pressure, or pressure in combination with shear.¹ Among those conditions associated with pressure ulcers are neurovascular disease, orthopaedic or neurologic injury, chronic deconditioning, malnutrition and cardiovascular disease. Pressure ulcers are especially morbid after spinal cord injury, leading to high rates of hospitalization and longer hospital stays.² Pressure ulcers pose significant physical and

psychological challenges for individuals.³ Economic challenges also arise when pressure ulcers develop, particularly in the area of resource allocation.⁴

Surgical closure of a pressure ulcer includes complete excision of the ulcer, pseudo bursa, ostectomy, and flap coverage. Generally speaking, skin grafts are not a good choice for coverage of a pressure ulcer. Pressure ulcers should be covered with flaps to provide well-vascularized tissue and adequate padding over the bony prominences. The choice of the flap will be determined largely by the location of the pressure ulcer.

There have been numerous reports of surgical procedures for PUs, but little is known about the indications and the optimal timing of surgery with different flaps. It is difficult to make a valid comparison of the different procedures, given the heterogeneity of indications and perioperative care between studies reporting these techniques

In the present study, we aim to evaluate the management of stage III and stage IV pressure ulcers with different flaps and to identify the complications and recurrence rate of pressure ulcers following surgical management.

METHODS

A retrospective study was conducted in the Department of Plastic and Reconstructive Surgery, Thanjavur Medical College, Tamilnadu, India on 28 patients with pressure ulcers who had undergone flap reconstruction during the period between 2016 and 2019. The pressure ulcer stages were defined according to the staging system of the National pressure ulcer advisory panel. Stage I pressure ulcer: non-blanchable erythema of intact skin; stage II pressure ulcer: Partial-thickness skin loss with exposed dermis; stage III pressure ulcer: Full-thickness skin loss and stage IV pressure ulcer: Full-thickness skin and tissue loss with exposed or directly palpable fascia, muscle, tendon, ligament, cartilage or bone in the ulcer.

All patients with stage III and stage IV pressure ulcers in the sacral, ischial and trochanteric regions were included in the study. Exclusion criteria included patients with cardiopulmonary dysfunction, chemotherapy treatment and previous operation scars that interfered with flap design or harvest.

Institutional ethics committee approval was obtained. All procedures were carried out in accordance with the ethical standards of the institutional committee and with the 1964 Declaration of Helsinki. Written informed consent was obtained from all the patients and the parent of the male child to utilise their data and photographs. The sample size was calculated based on the total number of stage III and stage IV pressure ulcers managed with different flaps during the study period.

Biochemical, radiological and bacteriological investigations were done. The patients were treated for

anaemia, malnutrition, sepsis and other comorbid illness. Pre-operative anaesthetic assessment was done. Psychological support was given as these patients were mostly depressed.

Initial treatment of pressure ulcers began with debridement of the affected area, thorough removal of the bursa and osteomyelitic bone. The pressure ulcers were covered with local flaps depending upon the site. The blood supply of the flaps was evaluated with doppler. The flap size was slightly larger than the wound size. After flap elevation with perforators, the flaps were transposed, rotation advanced, or placed with propeller-like movement to cover the wound according to the pedicle axis. All donor-site defects were closed with primary closure or skin grafting and suction drainage was placed under the flaps for 5–7 days to prevent hematoma or seroma formation.

The primary outcome of the study about the different flap covers of different sites of pressure ulcers and the secondary outcome of postoperative complications like suture dehiscence, hematoma, wound infection, partial or total flap loss, graft loss and recurrence rate of pressure ulcers were being monitored.

Statistical methods

SPSS version 25.0 was used in data management. Mean and standard deviation or median and range were used for numerical data description.

RESULTS

Twenty-two male patients, five female patients and one male child had been operated for pressure ulcers. The age group was 3–62 years with an average of 37 years (Table 1). Eighteen patients with spinal cord injury, three patients with head injury, three patients with orthopaedic fractures and one patient each with tethered cord syndrome, meningomyelocele, post-surgical and lumbar spondylosis with L5, S1 listhesis had developed pressure ulcers. The locations of the pressure ulcers were 14 (50%) in sacral, 10 (35.7%) in ischial, 3 (10.7%) in trochanteric and 1 (3.6%) in multiple sites. 18 patients with stage III and 10 patients with stage IV pressure ulcers were covered with different flaps.

S. no.	Age/ Sex	Cause	Location of pressure sore	Flap	Associated factors
1	23/M	Traumatic paraplegia	Sacral pressure ulcer	Transverse Lumbosacral flap	Bladder and bowel incontinence
2	26/F	Traumatic paraplegia	Sacral pressure ulcer	B/L V-Y Advancement flap	Bladder and bowel incontinence
3	29/F	Traumatic paraplegia	Ischial pressure ulcer	Rotation flap	Bladder and bowel incontinence

Continued.

S. no.	Age/ Sex	Cause	Location of pressure sore	Flap	Associated factors
4	33/F	Tethered cord syndrome	Sacral pressure ulcer	Gluteal Rotation flap	Bladder and bowel incontinence
5	45/M	Traumatic paraplegia	Ischial pressure ulcer	Posteromedial thigh transposition flap	Bladder and bowel incontinence
6	60/M	Post- surgical	Sacral pressure ulcer	Transverse lumbosacral flap	No co morbidities
7	31/M	Head injury	Sacral pressure ulcer	B/L V-Y advancement flap	Bladder/bowel
8	31/M	Traumatic paraplegia	Ischial pressure ulcer	Rotation flap	Bladder/bowel and psychiatric illness
9	39/M	Traumatic paraplegia	Ischial pressure ulcer	Rotation flap	Bladder/bowel
10	32/M	Traumatic paraplegia	Sacral pressure ulcer	Transverse Lumbosacral flap	Bladder and bowel incontinence
11	35/M	Traumatic paraplegia	Ischial pressure ulcer	Posteromedial thigh transposition flap	Bladder and bowel incontinence
12	32/M	Traumatic paraplegia	Trochanteric Pressure ulcer	TFL flap	Bladder and bowel incontinence
13	60/F	Lumbar spondylosis With L5,S1 listhesis	Ischial pressure ulcer	Rotation flap	No co morbidities
14	36/M	Traumatic paraplegia	Sacral pressure ulcer	Transverse Lumbosacral flap	Bladder/bowel
15	35/M	Traumatic paraplegia	Ischial pressure ulcer	Posteromedial thigh transposition flap	Ischial osteomyelitis, Bladder/bowel
16	3/ M child	meningomyelocele	Ischial pressure ulcer	Posteromedial thigh transposition flap	Bladder/bowel
17	42/M	Traumatic paraplegia	Sacral pressure ulcer	Transverse Lumbosacral flap	Bladder/bowel
18	53/M	Quadriplegia	Ischial pressure ulcer	Posteromedial thigh transposition flap	Bladder/bowel
19	35/M	Head injury	Trochanteric Pressure ulcer	V-Y advancement flap	No co morbidities
20	46/M	Traumatic paraplegia	Sacral pressure ulcer	Transverse Lumbosacral flap	Bladder/bowel
21	39/F	Fracture femur	Ischial & Sacral pressure ulcer	Posteromedial thigh transposition flap	No co morbidities
22	34/M	Pelvis fracture	Trochanteric Pressure ulcer	Posteromedial thigh transposition flap	No co morbidities
23	38/M	Traumatic paraplegia	Sacral pressure ulcer	B/L V-Y advancement flap	Bladder/bowel
24	62/M	Fracture femur	Sacral pressure ulcer	Transverse Lumbosacral flap	Bladder/bowel
25	53/M	Traumatic paraplegia	Sacral pressure ulcer	Gluteal Rotation flap	Bladder/bowel
26	31/M	Traumatic paraplegia	Ischial pressure ulcer	Posteromedial thigh transposition flap	Bladder/bowel
27	39/M	Traumatic paraplegia	Sacral pressure ulcer	Transverse Lumbosacral flap	Bladder/bowel
28	24/M	Head injury	Sacral pressure ulcer	Transverse Lumbosacral flap	Bladder/ bowel

Sacral pressure ulcers were covered with Transverse Lumbosacral flap (9 patients) (Figure 1), bilateral V-Y Advancement flap (3 patients) (Figure 2, 3) and gluteal

rotation flap (2 patients) (Figure 4, 5). Ischial pressure ulcers were covered with Rotation flap (4 patients) and

posteromedial thigh transposition flap (6 patients) (Figure 6, 7).

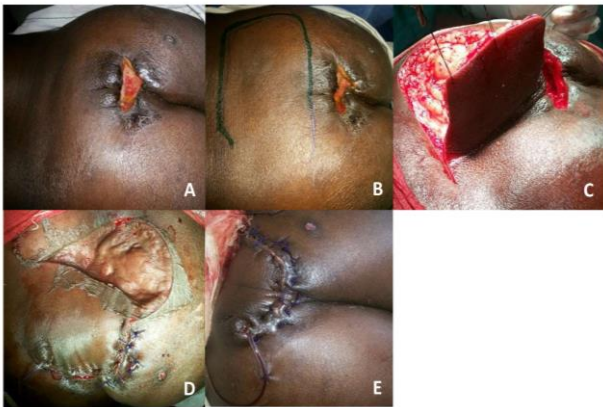

Figure 1: Transverse Lumbosacral flap: (A) sacral Pressure ulcer of 46 years old male with traumatic paraplegia (B) Flap marking (C) flap elevation (D) Flap in setting and skin grafting of secondary raw area (E) immediate post-operative period.

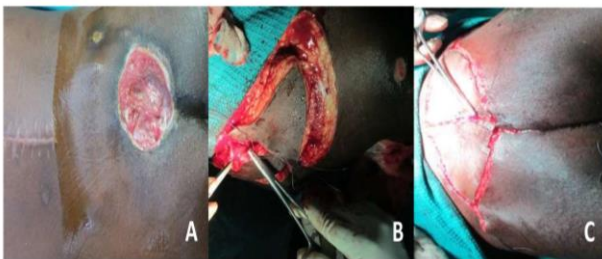


Figure 2: Bilateral V-Y Advancement flap (A) 31 years old male with sacral pressure ulcer (B) Bilateral V-Y Advancement flap elevated (C) Flap in setted.

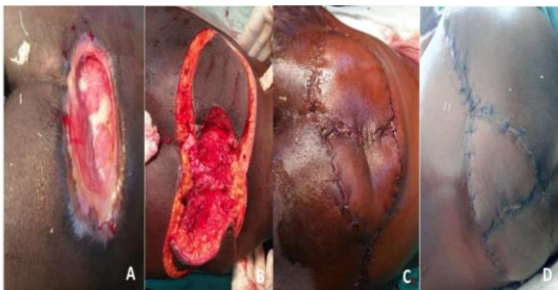

Figure 3: Bilateral V-Y Advancement flap (A) 26 years old female with sacral pressure ulcer (B) Bilateral V-Y advancement flap elevated (C) flap insetted (D) immediate post-operative period.

Trochanteric pressure ulcers were covered with tensor fascia lata flap (1 patient), Posteromedial thigh transposition flap (1 patient) and V-Y advancement flap (1 patient) (Figure 8, 9). One patient with both ischial and sacral pressure ulcers was covered with Posteromedial thigh transposition flap.

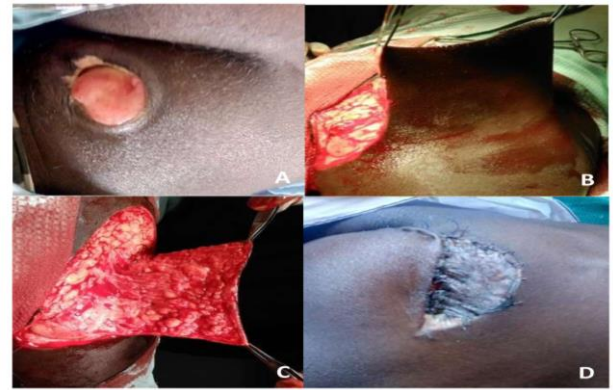


Figure 4: Gluteal rotation flap (A) Sacral pressure ulcer of 33 years female (B, C) gluteal rotation flap elevated (D) Skin grafting of secondary raw area.

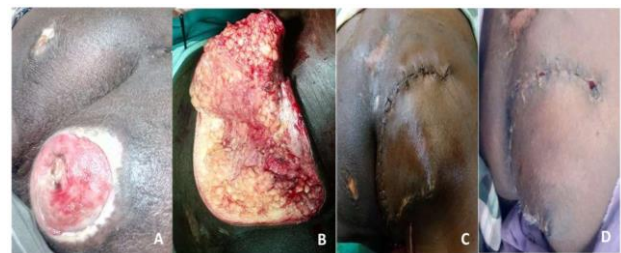

Figure 5: Gluteal rotation flap (A) Sacral pressure ulcer of 53 years male patient (B) gluteal rotation flap elevated (C) Flap in setting done (D) One month after flap cover.

Four patients had hematoma (14.28 %), three patients had marginal flap necrosis (10.71%), three patients had partial loss of skin graft (10.71%) and two patients had infection (7.14%). Duration of treatment ranged from 29 to 118 days. The mean hospitalization was 78 days. Patients were on regular follow up from 6 months to 3 years and no pressure ulcer recurrence was noted.

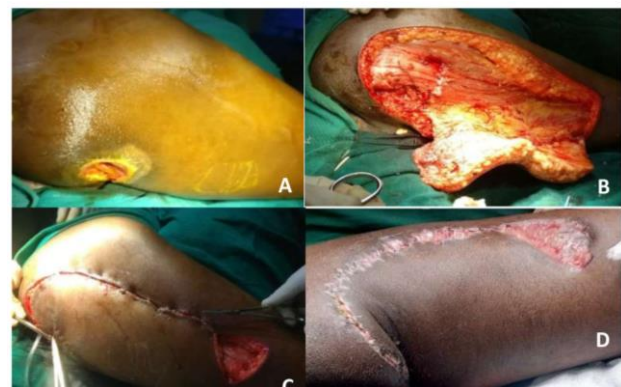

Figure 6: Posteromedial thigh transposition flap (A) 35 years old male with ischial pressure ulcer following traumatic paraplegia (B) posteromedial thigh transposition flap elevated with perforators (C) flap insetted with skin grafting of secondary raw area (D) 2 months post-operative follow up.

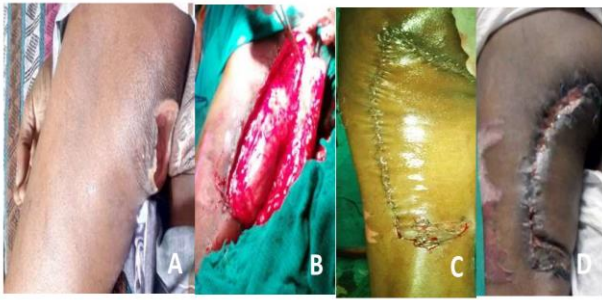

Figure 7: Posteromedial thigh transposition flap (A) 3 years old male child with ischial pressure ulcer (B) Posteromedial thigh transposition flap elevated with perforators (C) Flap insetted with skin grafting of secondary raw area (D) 4 months post-operative follow up.

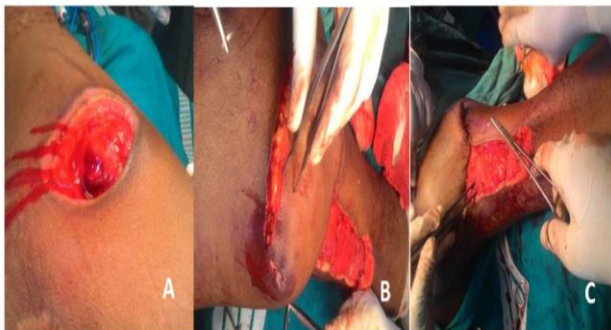


Figure 8: Tensor fascia lata (TFL) flap: (A) 32 years old male with trochanteric pressure ulcer (B) Tensor Fascia lata flap elevated (C) Flap insetting in progress.

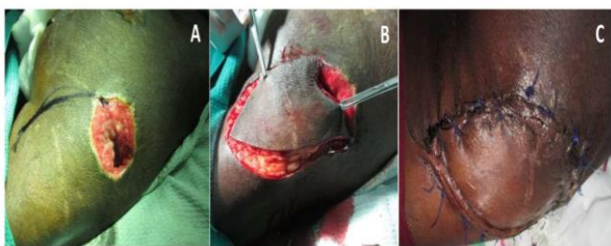

Figure 9: V-Y advancement flap (A) trochanteric pressure ulcer of 35 years old male (B) V-Y advancement flap elevated (C) immediate post-operative period with good flap viability.

DISCUSSION

Pressure ulcers have been described as one of the most costly and physically debilitating complications in the 20th century. Pressure ulcers are the third most expensive disorder after cancer and cardiovascular diseases.⁵ The incidence of pressure ulcers is different in each clinical setting. Incidence rates of as low as 0.4% to as high as 38% have been reported in the inpatient department while prevalence has been reported as 3.5% to 69%.^{6,7} Two

thirds of pressure ulcers occur in the elderly above 70 years of age. They are also common in young patients with neurological impairment. In Indian setting, the prevalence of pressure ulcers in hospitalized patients has been reported to be 4.94%.⁸ In this study 22 males (78.6%) and 5 females had pressure ulcers. A similar study of 48 patients by Duci et al. reported that pressure ulcers were predominant in male patients with 42 cases or 76.3%.⁹ In our study the pressure ulcers were predominant in the younger age group of 23-40 years and the average age of patients in our study was 37 years. A similar study of 60 patients with pressure ulcers by Schiffman et al. reported that average age of patients in their study was 73.1.¹⁰

Factors causing pressure ulcers are prolonged pressure, shear, friction, moisture, abnormal posture and impaired mobility. Pressure between the bony prominence and external surface occludes the capillaries. The normal capillary pressure ranges from 16 to 33 mm Hg in different segments. External pressure of more than 33 mm Hg occludes the blood vessel so that the underlying and surrounding tissues become anoxic and if the pressure continues for a critical duration, cell death will occur, resulting in soft tissue necrosis and eventual ulceration.¹¹ The tissue damage is more in the muscle after mechanical loading than in the skin.¹² The average pressure over the ischial tuberosity and the surrounding area exceeds 100 mm Hg during sitting, at the sacral region it is 40-60 mm Hg in the supine position, while it is 70-80 mm Hg over the trochanteric region in the lateral lying down position. Sacrum and trochanters are devoid of much soft tissue covering. Effectively the skin directly covers these pressure points with very little interposition of soft tissue cushion, thus increasing the risk of ulceration as compared to the rest of the body. In our study 50% of patients had sacral pressure ulcer in contrast to the study by Laing et al. where 29% of patients had sacral pressure ulcer.¹³

Wound debridement with removal of the bursa and necrotic tissue are essential. Wound closure techniques depend on the location, size, and depth of the pressure sore. Skin grafting lacks sufficient bulk or strength to cover the wound, with failure rates of approximately 70 percent.¹⁴ Fasciocutaneous flaps are durable, well-vascularized flaps that spare significant functional deformity.¹⁵ Musculocutaneous flaps provide more depth of coverage. Muscle flaps are also a good choice in an infected wound.^{16,17} The better local blood supply provides improved tissue oxygenation, improved antibiotic delivery, and enhanced lymphocytic function that improves bacterial killing. Free tissue transfer may be useful in recurrent wounds.¹⁸⁻²⁰

Nutritional support, patient positioning and spasm control are essential. Bowel and bladder control should be established to prevent wound contamination. Drains are often left in place for a significant period to allow better flap apposition. Early rehabilitation may be used to

minimize deconditioning while protecting the flap. After approximately 2 to 3 weeks of complete flap offloading, sitting protocols are begun after the patient has healed enough to tolerate pressure on the flap, usually in 15- to 30-minute intervals to a goal of 2 hours at 6 weeks.

Duci et al reported that the mean hospitalization was 63.6 days. Alderden et al in their study in 87 patients with pressure ulcers found that the mean of hospitalization was 37 days.²¹ The mean hospitalization was 78 days in our study.

Recurrence rate of pressure ulcers have been reported between 3 and 82 percent, depending on endpoint definition and length of follow-up. No pressure ulcer recurrence was noted in our regular follow up from 6 months to 3 years.

Pressure ulcers are preventable with adequate patient care. Patients with pressure ulcers should be psychologically supported. Nutritional support is very important for better outcome. Appropriate flap cover is mandatory based on the stage and site of pressure ulcer. A large flap design is preferred so that if re rotation is required in case of recurrence, the same flap can be reused. Post-operative rehabilitation is very important. A multi-disciplinary team approach is the secret of success in pressure ulcer management.

CONCLUSION

Our study revealed good clinical outcomes from thorough debridement of pressure ulcer and management of stage III and stage IV pressure ulcers with different flaps. Fasciocutaneous flaps are durable, well-vascularized flaps that prevent the recurrence of pressure ulcer.

ACKNOWLEDGEMENTS

We acknowledge the Department of Plastic Surgery, Thanjavur Medical College and the patients operated under the department.

Funding: No funding sources

Conflict of interest: None declared

Ethical approval: The study was approved by the Institutional Ethics Committee

REFERENCES

1. European Pressure Ulcer Advisory Panel, National Pressure Injury Advisory Panel and Pan Pacific Pressure Injury Alliance. Prevention and Treatment of Pressure Ulcers/Injuries: Clinical Practice Guideline. The International Guideline. Emily Haesler (Ed.). EPUAP/NPIAP/PPPIA; 2019.
2. Cushing CA, Phillips LG. Evidence-based medicine: pressure sores. *Plast Reconstr Surg*. 2013; 132:1720-32.
3. Moore Z, Avsar P, Conaty L, Moore DH, Patton D, O'Connor T. The prevalence of pressure ulcers in Europe, what does the European data tell us: a systematic review. *J Wound Care*. 2019;28:710-19.
4. Hauck KD, Wang S, Vincent C, Smith PC. Healthy life-years lost and excess bed-days due to 6 patient safety incidents. *Med Care*. 2017;55:125-30.
5. Agrawal K, Chauhan N. Pressure ulcers: Back to the basics. *Ind J Plast Surg*. 2012;45:244-54.
6. Shahin ES, Dassen T, Halfens RJ. Incidence, prevention and treatment of pressure ulcers in intensive care patients: A longitudinal study. *Int J Nurs Stud*. 2009;46:413-21.
7. Leblebici B, Turhan N, Adam M, Akman MN. Clinical and epidemiologic evaluation of pressure ulcers in patients at a university hospital in Turkey. *J Wound Ostomy Continence Nurs*. 2007;34:407-11.
8. Chauhan VS, Goel S, Kumar P, Srivastava S, Shukla VK. The prevalence of pressure ulcers in hospitalized patients in a university hospital in India. *J Wound Care*. 2005;14:36-7.
9. Duci SB, Arifi HM, Selmani ME, et al. Surgical Treatment of 55 Patients with Pressure Ulcers at the Department of Plastic and Reconstructive Surgery Kosovo during the Period 2000-2010: A Retrospective Study. *Plast Surg Int*. 2013;2013:129692.
10. Schiffman J, Golinko MS, et al. Operative debridement of pressure ulcers. *World J Surg*. 2009;33:1396-402
11. Husain T. An experimental study of some pressure effects on tissues, with reference to the bed sore problem. *J Pathol Bacteriol*. 1953;66:347-58.
12. Kuwahara M, Tada H, Mashiba K, Yurugi S, Iioka H, Niitsuma K, et al. Mortality and recurrence rate after pressure ulcer operation for elderly long-term bedridden patients. *Ann Plast Surg*. 2005;54:629-32.
13. Laing TA, Ekpote N, Oon S, Carroll SM. Surgical reconstruction of pressure ulcer defects: a single- or two-stage procedure? *J Wound Ostomy Continence Nurs*. 2010;37:615-8.
14. Levine SM, Sinno S, Levine JP, Saadeh PB. An evidence-based approach to the surgical management of pressure ulcers. *Ann Plast Surg*. 2012;69:482-4.
15. Reddy M, Gill SS, Kalkar SR, Wu W, Anderson PJ, Rochon PA. Treatment of pressure ulcers: A systematic review. *J Am Med Assoc*. 2008;300:2647-62.
16. Chang SH. Anterolateral thigh island pedicled flap in trochanteric pressure sore reconstruction. *J Plast Reconstr Aesthet Surg*. 2007;60:1074-5.
17. Ichioka S, Okabe K, Ohura N, et al. Versatility of the Limberg flap and the V-Y flap (based on a distal perforator) for covering sacral ulcers. *Scandinavian J Plast Reconstruct Surg Hand Surg*. 2007;41:65-9.
18. Wong CH, Tan BK, Song C. The perforator-sparing buttock rotation flap for coverage of pressure sores. *Plast Reconstr Surg*. 2007;119:1259-66.

19. J6svay J, Sashegyi M, Kelemen P, Don6ath A. Modified tensor fascia lata musculofasciocutaneous flap for the coverage of trochanteric pressure sores. *J Plast Reconstr Aesthet Surg.* 2006;59:137-41.
20. Aslan G, Tuncali D, Bingul F, Ates L, Yavuz N. The “duck” modification of the tensor fascia lata flap. *Ann Plast Surg.* 2005;54:637-9.
21. Alderden J, Whitney JD, Taylor SM, Zaratkiewicz S. Risk profile characteristics associated with

outcomes of hospital-acquired pressure ulcers: a retrospective review. *Critic Care Nurse.* 2011;31(4):30-43.

Cite this article as: Gopalakrishnan R, Rajalingam M, Rajagunasekaran B, Esakimuthu R. Reconstruction of pressure ulcers with flaps in a tertiary care centre. *Int Surg J* 2021;8:647-53.