

Original Research Article

Effect of vitamin C on liver regeneration after partial hepatectomy and acetaminophen-induced liver injury in Wistar rats

Reno Rudiman*, Handy Wing, Nurhayat Usman

Department of Surgery, Division of Digestive Surgery, Hasan Sadikin Hospital/Faculty of Medicine, Padjadjaran University, Bandung, Indonesia

Received: 13 November 2020

Revised: 21 December 2020

Accepted: 30 December 2020

***Correspondence:**

Dr. Reno Rudiman,

E-mail: renorudiman@yahoo.com

Copyright: © the author(s), publisher and licensee Medip Academy. This is an open-access article distributed under the terms of the Creative Commons Attribution Non-Commercial License, which permits unrestricted non-commercial use, distribution, and reproduction in any medium, provided the original work is properly cited.

ABSTRACT

Background: The aim of this study is to evaluate the potential effect of vitamin C as an antioxidant on liver regeneration after partial hepatectomy and acetaminophen-induced liver injury in Wistar rats.

Methods: A total of 24 male Wistar rats were divided into four groups, each group consisted of 6 rats: group A (control, partial hepatectomy/PHx alone), group B (PHx and vitamin C 250 mg/kg BW), group C (acetaminophen 500 mg/kg BW and PHx), and group D (acetaminophen 500 mg/kg BW with PHx and vitamin C 250 mg/kg BW). Subtoxic dose of acetaminophen was given 24 hours before partial hepatectomy. Vitamin C was given orally via oral gavage for 6 consecutive days after partial hepatectomy. POD 7, all animals were terminated and performed laparotomy to obtain liver tissue for measurement of liver weight and regeneration rate, blood samples for malondialdehyde (MDA) as a lipid peroxidation measurement and histopathological investigation.

Results: The means of regeneration rate in vitamin C groups were significantly higher compared to non-vitamin C group ($p < 0.05$). Similar result, the means of MDA values in vitamin C groups were significantly lower compared to non-vitamin C group ($p < 0.05$). This result suggests a protective effect of vitamin C against lipid peroxidation. Histopathological changes in liver cells were statistically difference between vitamin C groups and non-vitamin C groups ($p < 0.05$).

Conclusions: Our results indicate that vitamin C administration promotes liver regeneration and inhibits lipid peroxidation after partial hepatectomy and acetaminophen-induced liver injury in Wistar rats.

Keywords: Vitamin C, Acetaminophen-induced liver injury, Partial hepatectomy, Liver regeneration, Oxidative stress, Lipid peroxidation

INTRODUCTION

Acute liver failure (ALF) is defined by the American association for the study of liver diseases as rapid development of acute liver injury without any prior signs of damage and is characterized by severe impairment of the synthetic, metabolic, and detoxifying functions of the liver.^{1,2} ALF differs from chronic liver failure where the failure occurs as a result of liver injury caused over a long period of time and from acute chronic liver failure,

where abrupt liver damage takes place as a result of chronic liver diseases.^{3,4}

Hepatotoxicity is the most remarkable feature of acetaminophen overdose. Acute overdoses of acetaminophen can cause potentially fatal liver damage and, in rare individuals, a normal dose can do the same; the risk is heightened by alcohol consumption. Acetaminophen toxicity is the foremost cause of acute liver failure.⁵

Toxicity from acetaminophen is not from the drug itself but from one of its metabolites, N-acetyl-p-benzoquinoneimine (NAPQ1). Acetaminophen biotransformation involves conjugation with glucuronide and sulphate. A small amount of acetaminophen is metabolized by mixed function oxidase enzymes to form highly reactive compound NAPQ1, which is immediately conjugated with glutathione and subsequently excreted as cysteine and mercapturic conjugates. In overdoses, large amounts of acetaminophen are metabolized by oxidation because of saturation of sulphate conjugation pathway, but once the protective intracellular glutathione stores are depleted hepatic and renal damage may ensue.⁶⁻⁸

Recent findings indicated that toxic manifestations induced by acetaminophen may be associated with the enhanced production of reactive oxygen species (ROS). The production of ROS may produce oxidative stress and induce various tissue damage i.e., liver, kidney and brain.⁹⁻¹¹ Oxidative stress occurs when the production of ROS overrides the antioxidant capacity in the target cell, resulting in the damage of macromolecules such as nucleic acids, lipids and proteins causing alterations in the target cell function and leading to cell death.¹² Malondialdehyde (MDA) is the end product of lipid peroxidation resulting from the interaction between ROS and cellular or sub cellular membranes. Vitamin C is thought to be an important water-soluble antioxidant which is reported to neutralize ROS and reduce the oxidative stress.¹³

To study the potential of alternative therapeutic approaches of vitamin C and to better understand the pathophysiology of ALF, animal models that can reflect the ALF occurring in human beings are needed. Therefore, the present study was planned to investigate the effect of vitamin C after partial hepatectomy on the oxidative stress in the liver of male Wistar rats and to study the role of vitamin C in overcoming the oxidative damage and lipid peroxidation induced by acetaminophen, if administered following the exposure.

METHODS

Study design

This study was an experimental study with parallel design.

Study place and period

The study was conducted at the animal laboratory, university of Padjadjaran, Bandung, West Java, Indonesia from September 2020 to October 2020.

Animal

The Inclusion criteria used in this study: (a) Wistar rats aged 3 to 6 months; (b) male sex; (c) weight 300 grams; (d) in healthy condition. The exclusion criteria: rats that

were ill or unable to adapt before the study begin. Food and tap water were available ad libitum. Room temperature range were 21-24°C, lighting control were 12 h/light and 12 h/dark cycle, and humidity ranged from 55 to 60%. All animals received human care according to the criteria outlined as 3 R and 5 F principles. The study protocol was approved by the ethical committee of Padjadjaran university.

Sampling technique

The sampling technique used in this study based on calculations according to Federer, and with anticipation of dropped out animals during the study, the total number of experimental animals was 24 rats.

Experimental groups

A total of 24 male Wistar rats are divided into four groups with 6 animals in each: group A (control, partial hepatectomy/PHx alone), group B (PHx and vitamin C 250 mg/kg BW), group C (acetaminophen 500 mg/kg BW and PHx), and group D (acetaminophen 500 mg/kg BW with PHx and vitamin C 250 mg/kg BW).

Experimental procedures

To study the therapeutic potential of a treatment for ALF, its prior testing in an animal model of ALF is essential. In the current study, an ALF model in rats was developed by combining administration of acetaminophen and 70% partial hepatectomy (PHx). Acetaminophen-induced liver injury was given 24 hours before the surgery. The median and left lateral lobes of the liver were removed to excise 70% of the liver mass. The progression of liver injury, degeneration of hepatocytes and infiltration of inflammation cells was observed by histological evaluation. The reversibility of ALF was confirmed by the restoration of survival and regeneration of liver hepatocytes. This model presents a reliable method to evaluate the potential of alternative therapeutic approaches of vitamin C for ALF. The use of two different approaches also makes it possible to study the combined effect of physical and drug-induced liver injury.

Subtoxic dose of acetaminophen (500 mg/kg BW) was given 24 hours before partial hepatectomy. When performing 70% PHx, we use a standard cocktail mix of ketamine hydrochloride (100 mg/kg body weight) and xylazine (10 mg/kg body weight), which is injected intraperitoneally. Removal of 70% of the liver mass, named 70% partial hepatectomy, was performed as described by Higgins and Anderson, 1931.^{14,15}

Vitamin C (250 mg/kg BW) administration were given orally via oral gavage for 6 consecutive days after the animals successfully recovered from 70% PHx. Daily dose was administered at approximately the same time each day. After one week of treatment, relaparotomy

were performed to obtain whole liver tissue samples for histopathological investigation of liver regeneration and blood collection to measurement of malondialdehyde (MDA) as lipid peroxidation indicator.

Liver weight and regeneration rate

The preoperative total liver weight was calculated from the resected liver weight.^{14,16} Postoperative total liver weight was measured at sacrifice. The change in liver weight was evaluated as the hepatic regeneration rate (RR). RR is defined as (liver weight per 100 g of the body weight at sacrifice/preoperative projected liver weight per 100 g of the body weight) × 100:

$$RR = \frac{(\frac{LW_m}{100} g BW)_{sac}}{(\frac{LW_p}{100} g BW)_{pre}} \times 100$$

LW_m is the measured liver weight at sacrifice; LW_p is the preoperative projected liver weight.

Malondialdehyde (MDA) measurement

Lipid peroxidation was evaluated by measurement of plasma MDA which was obtained from blood. The MDA measurement was based on 2-thiobarbituric acid reactive substances (TBARS) with spectrophotometer to read the wavelength. TBARS are low-molecular-weight end products (mainly MDA) that are formed during the decomposition of lipid peroxidation products. Increased levels of TBARS usually demonstrated in liver disorders disease. The procedure involved the following steps- blood from rats was collected in an EDTA contained blood container then sent to biochemistry laboratory. Blood was centrifuged at a speed of 3000 rpm for 10 minutes and plasma located on the surface is separated and taken to be analyzed. MDA concentration was measured with Quantichrom™ TBARS assay kit (DTBA-100).

Histopathological evaluation

At the end of the surgical procedure, the liver tissues were immersed in a buffer formalin solution and sent to anatomical pathology laboratory to investigate the liver regeneration.

Statistical analysis

All statistical analysis carried out using SPSS statistical software (SPSS for Windows version 26). Data from histopathologic investigation were presented in crosstabulation. Differences in measured parameter among the four groups were analyzed with a non-parametric test (Kruskal-Wallis) and dual comparisons between groups exhibiting significant values were evaluated with a Mann-Whitney U-test. These differences were considered significant when the probability value was less than 0,05. Data from MDA values and

regeneration rate were presented in mean ± standard deviation and tested with 1-way ANOVA test. Significant value between groups were tested with Tukey test.

RESULTS

Evaluation of regeneration rate

The mean of regeneration rate (RR) in group A (control/PHx alone) was 80.55±0.60. In group B (PHx and vitamin C), the mean of RR was 4.91±2.27. The mean of RR was 34.37±2.32 in group C (acetaminophen and PHx) and 23,68±7.11 in group D (acetaminophen, PHx and vitamin C) (Table 1) (Figure 1).

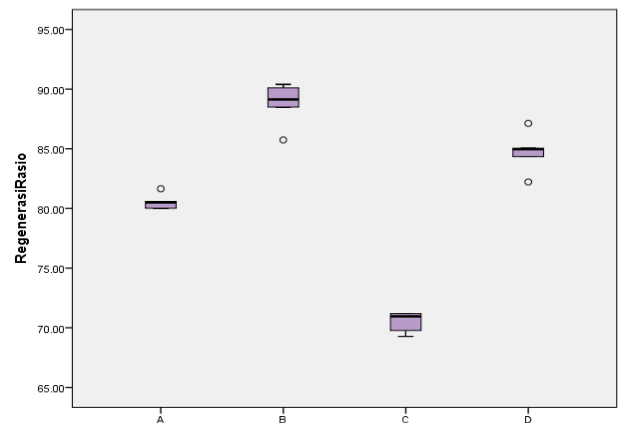


Figure 1: Regeneration rate boxplot.

Evaluation of MDA

The mean of MDA value in group A (control/PHx alone) was 26.10±2.81. In group B (PHx and vitamin C), the mean of MDA value was 4.91±2.27. The mean of MDA value was 34.37±2.32 in group C (acetaminophen and PHx) and 23,68±7.11 in group D (acetaminophen with PHx and vitamin C) (Table 2 and 3) (Figure 2).

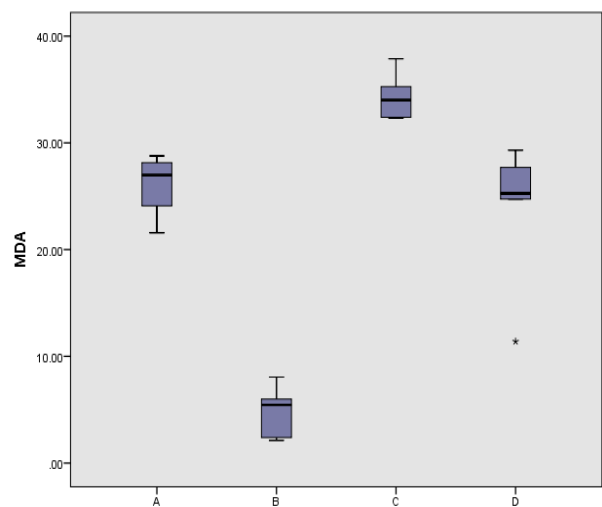


Figure 2: MDA values boxplot.

Histopathological findings

For histopathological assessment, the liver sections were stained with Harris' hematoxylin and eosin (H and E) staining method. HE-stained sections were observed for any abnormalities of histopathological features under a light microscope at 20x, 100x, and 200x. The degree of hepatocellular changes was scored based on the grading system done by the previous study, as shown in the Table 4.¹⁷

The incidence of hepatocytes necrosis was examined in all groups. We found 67% moderate and 33% mild hepatocytes necrosis in group A (control, PHx alone); 50% minimal, 33% mild and 17% moderate hepatocytes necrosis in group B (PHx and vitamin C); 80% severe and 20% moderate hepatocytes necrosis in group C (acetaminophen and PHx); 80% mild and 20% moderate hepatocytes necrosis in group D (acetaminophen with PHx and vitamin C) as shown in the Figure 3, Table 5 and 6.

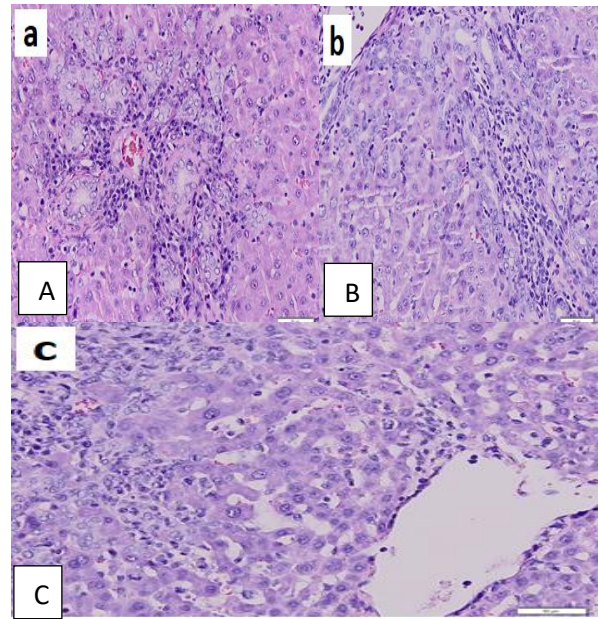


Figure 3: Hepatocytes necrosis, H and E stained (200x magnification) (A) mild, (B) moderate and (C) severe.

Table 1: Regeneration rate (%), Kruskal Wallis test.

Regeneration rate (%)	Group				P value
	A (n=6)	B (n=6)	C (n=5)	D (n=5)	
$\bar{X} \pm SD$	80.55±0.60	88.83±1.70	70.48±0.89	84.74±1.76	<0.001a
Median	80.51	89.14	70.96	84.96	
Minimum	80.01	85.74	69.28	82.22	
Maximum	81.65	90.39	71.19	87.13	

Table 2: Malondialdehyde (MDA) values, one-way ANOVA test.

MDA value	Group				P value
	A (n=6)	B (n=6)	C (n=5)	D (n=5)	
$\bar{X} \pm SD$	26.10±2.81	4.91±2.27	34.37±2.32	23.68±7.11	<0.001a
Median	26.99	5.45	34.01	25.27	
Minimum	21.58	2.12	32.30	11.40	
Maximum	28.78	8.06	37.88	29.32	

Table 3: Tukey test for MDA values.

Group		P value*	Significant difference
A	B	<0.001	Present
	C	0.015	Present
	D	0.754	Not Present
B	A	<0.001	Present
	C	<0.001	Present
	D	<0.001	Present
C	A	0.015	Present
	B	<0.001	Present
	D	0.03	Present
D	A	0.754	Not Present
	B	<0.001	Present
	C	0.03	Present

Table 4: Semiquantitative score for histopathological changes in liver cells.¹⁷

Score	Description
0 (-)	Normal-no hepatocytes necrosis
1 (+)	Minimal-mild, focal, limited to centrilobular region, less than ¼ of affected lobules are necrotic
2 (++)	Mild-moderate, focal, and multifocal central to midzonal lobular region ½ affected lobules are necrotic
3 (+++)	Moderate to severe, multifocal (centrilobular-portal region) X> ½ affected lobules are necrotic
4 (++++)	Severe, multifocal X> ¾ affected lobules are necrotic
5 (+++++)	Severe (whole lobules) Hepatocytes loss from central vein to portal area extend to adjacent lobules.

Table 5: Histopathological score, Kruskal Wallis test.

Score	Group				P value
	A (n=6) (%)	B (n=6) (%)	C (n=5) (%)	D (n=5) (%)	
Normal	0 (0.0)	0 (0.0)	0 (0.0)	0 (0.0)	0.003a
Minimal-mild	0 (0.0)	3 (50.0)	0 (0.0)	0 (0.0)	
Mild-moderate	2 (33.3)	2 (33.3)	0 (0.0)	4 (80.0)	
Moderate to severe	4 (66.7)	1 (16.7)	1 (20.0)	1 (20.0)	
Severe	0 (0.0)	0 (0.0)	4 (80.0)	0 (0.0)	
Severe (whole lobules)	0 (0.0)	0 (0.0)	0 (0.0)	0 (0.0)	

Table 6. Mann Whitney test for histopathological results.

Group		P value*	Significant difference
A	B	0.041	Present
	C	0.010	Present
	D	0.140	Not Present
B	C	0.006	Present
	D	0.190	Not Present
C	D	0.007	Present

DISCUSSION

The liver is characterized by complex physiology and the ability to undergo rapid regeneration.¹⁸⁻²⁰ Liver regeneration occurs by a compensatory hyperplasia and hypertrophy of the residual liver lobes.²¹ Animal models, particularly the rat model, are commonly used to investigate new aspects of liver regeneration. Ever since Higgins and Anderson presented a method for standardized partial hepatectomy in 1931, liver resection has been refined and used many times over.¹⁴ Today, the most widely used models are those involving 70% resection. In our study, 70% PHx in healthy rats induces a rapid regenerative response.

Acetaminophen overdose is the leading cause of drug-induced acute liver failure. Mitochondrial oxidative stress is considered to be the predominant cellular event in acetaminophen-induced liver injury. Malondialdehyde (MDA) is one of the final products of polyunsaturated fatty acids peroxidation in the cells. An increase in free radicals causes overproduction of MDA, which is commonly known as a marker of oxidative stress and lipid peroxidation.^{22,23}

Vitamin C is an organic compound found in many plants and animals and is known to have antioxidant properties. The antioxidant effect of vitamin C is the ability of vitamin C to donate hydrogen atoms and form ascorbic free radicals that are relatively stable and can reduce damage caused by oxidation processes.²⁴ Inhibition the process of formation of liver necrosis and reduction of lipid peroxidation by the administration of vitamin C occurs due to neutralization of ROS by vitamin C and conversion of lipid peroxidation products to non-reactive lipid vitamin C-peroxidation products.^{25,26}

Our data from representative images of liver morphology in the four different groups show that in the state of acetaminophen liver injury and partial hepatectomy without oral vitamin C there were moderate to severe hepatocytes necrosis and these necrosis process decreased significantly along with oral vitamin C administration. We also found the average value of regeneration rate in vitamin C groups was higher compare with non-vitamin C groups. This was further supported statistically with Mann Whitney test for the assessment of histopathological changes and Tukey test for the assessment of regeneration rate.

The average value of plasma MDA levels after partial hepatectomy in the Wistar rat groups treated with oral vitamin C was lower. Vitamin C also helps lower the MDA plasma after acetaminophen administration before partial hepatectomy in this study. This result suggests a protective effect of vitamin C against lipid peroxidation and oxidative stress.

Hepatoprotective effect of vitamin C in our results were consistent with the results of several previous studies.²⁷ Role of vitamin C as a powerful plasma antioxidant capable of reducing the oxidative stress effects in human liver need to be further investigated in future research.

The limitation of our study is that daily administration of vitamin C by oral gavage can induce stress to the rats and alteration in food and water consumption especially when the procedure is carried out by unexperienced technician. Another limitation is the wide variations of MDA concentrations as a biomarker of oxidative stress. This is due to its high reactivity and possibility of various cross-reactions with co-existing biochemicals. This value depends on the range of measurement values by the reagent (kit). MDA examination also will provide better information if examined serially during the study.

CONCLUSION

Based on the results above, it can be concluded that the administration of vitamin C on liver regeneration after partial hepatectomy and acetaminophen-induced liver injury in Wistar rats yielded significant results in terms of promote liver regeneration and inhibits lipid peroxidation compared to those without vitamin C administration. The application of vitamin C is beneficial for the liver regeneration in this study.

ACKNOWLEDGEMENTS

The authors would like to thank their deep gratitude to the division of digestive surgery, department of surgery, Hasan Sadikin general hospital, Bandung, for their substantial support and guidance in the preparation of this research article. They also would like to express their deep gratitude to animal laboratory and pathology anatomy laboratory of Padjadjaran university for their great support.

Funding: No funding sources

Conflict of interest: None declared

Ethical approval: The study was approved by the Institutional Ethics Committee of Padjadjaran University, Bandung, Indonesia

REFERENCES

1. Polson J, Lee WM. AASLD position paper: the management of acute liver failure. *Hepatology*. 2005;41:1179-97.

2. Rahbari NN, Garden OJ, Padbury R, Brooke-Smith M, Crawford M, Adam R et al. Post hepatectomy liver failure: a definition and grading by the International Study Group of Liver Surgery (ISGLS). *Surgery*. 2011;145:713-24.
3. Helling TS. Liver failure following partial hepatectomy. *HPB: the official journal of the International Hepato Pancreato Biliary Asso*. 2006;8:165-74.
4. Larson AM, Polson J, Fontana RJ, Davern TJ, Lalani E, Hynan LS et al. Acute Liver Failure Study Group. Acetaminophen-induced acute liver failure: results of a United States multicenter, prospective study. *Hepatology*. 2005;42(6):1364-72.
5. Rumack BH, Matthew H. Acetaminophen Poisoning and Toxicity. *Pediatrics*. 1975;55:871-6.
6. Walker RM, Massey TE, McElligott TF, Racz WJ. Acetaminophen Induced Hypothermia, Hepatic Congestion, And Modification By N-acetylcysteine In Mice. *Toxicol App Pharmacol*. 1981;59:500-7.
7. Benjamin N, Rawlins M, Vale JA. *Drug Therapy and Poisoning*. 5th ed. United Kingdom: WB Saunders. 2002:985-7.
8. Pajoumand A, Jalali N, Abdollahi M, Shadnia S. Successful Treatment of Acetaminophen Overdose Associated with Hepatic Failure. *Hum Exp Toxicol* 2003;22:453-8.
9. Dwivedi PD, Das M, Khanna SK. Role of cytochrome p-450 in quinalphos toxicity: effect on hepatic and brain antioxidant enzymes in rats. *Food Chem Toxicol*. 1998;36:437-44.
10. Oncu M, Gultekin F, Karaoz E, Altuntas I. Nephrotoxicity in rats induced by chlorpyrifos-ethyl and ameliorating effects of antioxidants. *Human Exp Toxicol*. 2002;21:223-30.
11. Yu F, Wang Z, Ju B, Wang Y, Wang J. Apoptotic effect of organophosphorus insecticide chlorpyrifos on mouse retina in vivo via oxidative stress and protection of combination of vitamin C and E. *Exp Toxicol Pathol*. 2008;59:415-23.
12. Stephan B, Kyle L, Yong X. Role of oxidative stress in the mechanism of diethrin's hepatotoxicity. *Ann Clin Lab Sci*. 1997;27:196-208.
13. Aslan R, Sekeroglu MR, Gultekin F. Blood lipoperoxidation and antioxidant enzymes in healthy individuals. Relation to age, sex, habits, life style and environment. *J Environ Sci Health*. 1997;A32:2101-9.
14. Higgins GM, Anderson RM. Experimental pathology of the liver-Restoration of the liver of the white rat following partial surgical removal. *Arch Pathol*. 1931;12:186-202.
15. Sahay P, Jain K, Sinha P, Das B, Mishra A, Kesarwani A et al. Generation of a Rat Model of Acute Liver Failure by Combining 70% Partial Hepatectomy and Acetaminophen. *J Vis Exp*. 2019;153:601-46.
16. Andersen KJ, Knudsen AR, Kannerup AS, Sasanuma H, Nyengaard JR, Hamilton-Dutoit S et al. The Natural History of Liver Regeneration In Rats:

- Description Of An Animal Model For Liver Regeneration Studies. *Int j surg.* 2013;11(9):903-8.
17. Muhammad-Azam F, Nur-Fazila SH, Ain-Fatin R, Noordin MM, Yimer N. Histopathological changes of acetaminophen-induced liver injury and subsequent liver regeneration in BALB/C and ICR mice. *Veterinary world.* 2019;12(11):1682-8.
 18. Michalopoulos GK, DeFrances MC. Liver regeneration. *Science.* 1997;276:60-66.
 19. Taub R. Liver regeneration: from myth to mechanism. *Nat Rev Mol Cell Biol.* 2004;5:836-47.
 20. Michalopoulos GK, DeFrances MC. Liver regeneration, growth factors, and amphiregulin. *Gastroenterol.* 2005;128:503-6.
 21. Michalopoulos GK. Liver regeneration. *J Cell Physiol.* 2007;213:286-300.
 22. Kostopanagiotou GG, Grypioti AD, Matsota P, Mykoniatis MG, Demopoulos CA, Papadopoulou-Daifoti Z et al. Acetaminophen-induced liver injury and oxidative stress: protective effect of propofol. *Eur J Anaesthesiol.* 2009;26(7):548-53.
 23. Yan M, Huo Y, Yin S, Hu H. Mechanisms of acetaminophen-induced liver injury and its implications for therapeutic interventions. *Redox Biol.* 2018;17:274-83.
 24. Levine M, Rumsey SC, Daruwala R, Park JB, Wang Y. Criteria and recommendations for vitamin C intake. *J Am Med Assoc.* 1999;281(15):1415-23.
 25. Halliwell B, Gutteridge JM. Free radicals in biology and medicine. *J Free Radicals Biol Med.* 1985;1:331-4.
 26. Rose RC, Bode AM. Biology of free-radical scavengers-an evaluation of ascorbate. *Faseb J.* 1993;7:1135-42.
 27. Adikwu E, Deo O. Hepatoprotective effect of vitamin C. *J Pharmacolog Pharm.* 2013;4:84-92.

Cite this article as: Rudiman R, Wing H, Usman N. Effect of vitamin C on liver regeneration after partial hepatectomy and acetaminophen-induced liver injury in Wistar rats. *Int Surg J* 2021;8:489-95.