

Case Report

Innovative option for removal of encrusted, incarcerated longstanding indwelling Foleys catheter

Sanjay L. Paul^{1*}, Alankrita Deka², Archana Deka³

¹Department of Urology, ³Department of Anaesthesiology, Times Hospital, Tezpur, Assam, India

²Department of Pathology, AMC, Dibrugarh, Assam, India

Received: 12 November 2020

Revised: 22 December 2020

Accepted: 24 December 2020

*Correspondence:

Dr. Sanjay L. Paul,

E-mail: sanjaypaul619@gmail.com

Copyright: © the author(s), publisher and licensee Medip Academy. This is an open-access article distributed under the terms of the Creative Commons Attribution Non-Commercial License, which permits unrestricted non-commercial use, distribution, and reproduction in any medium, provided the original work is properly cited.

ABSTRACT

Encrustation of indwelling Foley's catheter is one of the common complication associated with long term indwelling catheter, encrusted catheter are often incarcerated and difficult to remove. Many methods have been evolved to remove stuck urethral catheter but each has its own complications. Here we have described a case of 90 year old male patient with chronic indwelling (7 months) Foley urethral catheter, who presented with chronic urinary retention. After initial bladder drainage with 8 Fr feeding tube by the side of catheter. Massive encrustation was fragmented by performing laser cyst lithotripsy with 6/7.5 Fr semi rigid ureter scope and 30 Watt Holmium laser. Catheter was removed intact and stone fragments evacuated. Post-operative recovery was uneventful. Surgical removal with minimally invasive technique should be treatment of choice for encrusted and stucked urethral catheter. Traditional technique of performing suprapubic cystostomy for removal of Foleys catheter are associated with various complications and should be reserved for hospital with limited facilities.

Keywords: Indwelling Foley catheter, Encrustations, Stucked Foley catheter

INTRODUCTION

Long-term indwelling catheters are generally used for patients suffering from spinal cord injury, prostatic problem, multiple sclerosis, spinal muscular atrophy etc. Long term indwelling urethral catheter can cause several complications such as urinary tract infections, pain, haemorrhage, iatrogenic hypospadias, pericatheter leakage and encrustation of catheter leading to blockage.¹

The catheter develops encrustation by mineral salts, stone formation and later gets obstructed when kept in situ for longer term. Massive encrustation is unusual complication with limited literature being reported. We hereby report a case of neglected long term indwelling Foley catheter, which was managed with minimally invasive technique at TIMEs hospital by consultant urologist and team.

CASE REPORT

Here we have described a case of 90 year old male patient, diagnosed case of grade III enlarged prostate with median lobe hypertrophy and was catheterised for urinary retention at local hospital 1 year back. Patient had now presented to us with chronic urinary retention with neglected indwelling Foley urethral catheter for last 7 months (Figure 1). On examination his prostate was enlarged, bladder was palpable. He was then planned for catheter change and urine routine examination. Initial attempt for deflation of balloon failed, a wire was passed through the balloon port but failed. An ultrasound was done but the balloon was not seen and the tip of the catheter was seen to be calcified, attempt of ultrasonography (USG) guided extra luminal balloon puncture around calcified area was tried supra-pubically with a spinal needle, which also failed. An 8 Fr feeding

tube was passed by the side of Foley's and bladder was drained. Patient was admitted and started on 3rd generation cephalosporins.

After initial bladder drainage with 8 Fr feeding tube by the side of catheter. Patient was shifted to operation theatre, 6/7.5 Fr semi rigid ureter scope was negotiated by side of Foley's catheter (Figure 2). Massive encrustation was encountered around tip of Foley's catheter which was fragmented by performing laser cystolithotripsy with 30 Watt Holmium laser (Figure 3). Catheter was removed intact (Figure 4) and stone fragments evacuated. A new 16 Fr Foley's was inserted and patient was discharged next days. Post-operative recovery was uneventful.




Figure 1: Long standing urobag with indwelling Foleys.

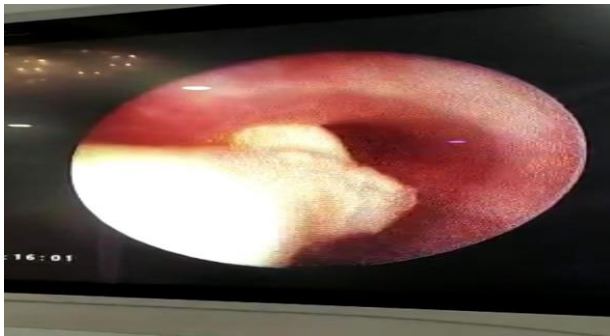


Figure 2: 6/7.5 semirigid ureterscope performed by the side of catheter.

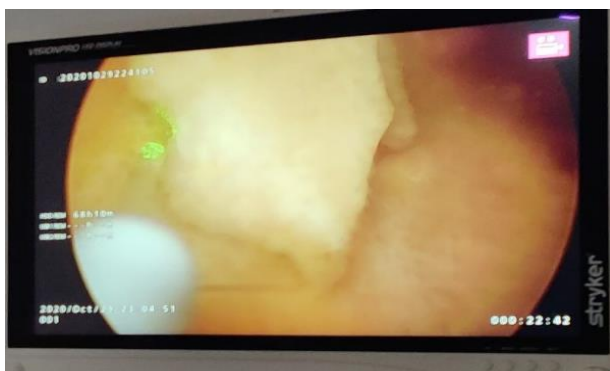

Figure 3: Massive encrustation, fragmented using Holmium laser.

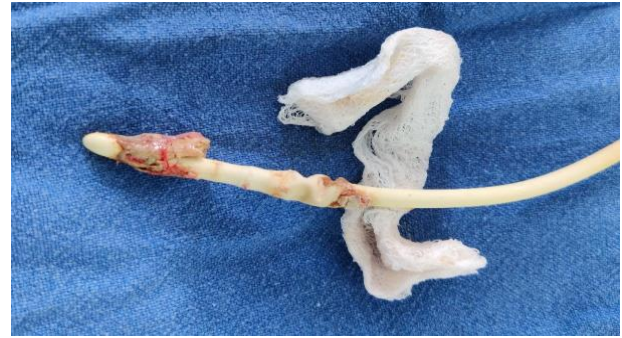

Figure 4: Foleys removed intact after fragmentation of encrusted calculi.

DISCUSSION

Large encrustation of Foley catheter is a pertinent problem which generally occurs in indwelling long period of urinary catheterization. Nearly 50% of the patients with long-term catheterization may develop this complication. Nearly all encrusted catheter are stuck and need some form of surgical method for removal.

In our case, a giant encrustations around the bulb of Foley had developed in a patient who was carrying the catheter in situ for 7 months. The patient had lost to follow up owing to his economic, geographical constraints and the lack of knowledge of the need to discard the catheter on time after follow up to the hospital. Adding to it, leakage by the side of catheter made him feel of passing urine normally, ignoring the fact of it being overflow incontinence.

Microorganism like bacteria in the urine make a biofilm on the surface of the catheter defending it from antibiotics and host defences.² Once, infection develops in urine with urease making bacteria, most commonly *Proteus mirabilis*, the pH of the urine increases. This results in encrustations often composed of struvite (magnesium-ammonium-sulfate) or apatite (calcium-phosphate).³ The most usual clinical features presented due to catheter encrustation include lower urinary tract symptoms, pain, bladder irritability and urine retention because of blockage of catheter. Urosepsis, a life-threatening complication may occur if catheter is not timely removed.⁴ There are no well-known methods to prevent bladder encrustations formation. However, it has been considered that increasing fluid and citrate intake could stop the encrustations. Few other important treatment approaches for preventing urinary catheter encrustation are, dietary modification, solution irrigation of the bladder and antibiotic usage for related urinary tract infection. Aseptic catheterization and sterile drainage systems help reduce entry of microorganisms into the bladder. This may decrease the encrustation of urethral catheter and stone formation. Regular changing of catheter, at least once in every three weeks is essential to reduce encrustations.⁵ Inflation of the balloon with triclosan in patients in whom long-term indwelling catheterization is required may be beneficial

given the fact that *Proteus mirabilis* is very sensitive to biocide triclosan. Acidifying the urine without removing the bacteria does not decrease encrustation. Proper antibiotic therapy for *Proteus mirabilis* should start immediately as soon as it appears in the urinary tract.⁶ Intermittent balloon deflation and re-inflation to interrupt the formation of encrustations and bladder irrigation with an acidic solution are also recommended for long-term indwelling catheters.⁷ Silicone catheters may be favourable for patients who need indwelling catheters since they are more resilient to encrustation than other types and are smaller in size.⁸ Last but not the least, proper patient education on catheter hygiene and treating the original cause of obstruction can be more effective in minimizing complications.

Surgical removal is only treatment of choice for unusual massive encrustations in long-term indwelling urethral catheter. Several methods such as extracorporeal shock wave lithotripsy, intraluminal pneumatic lithotripsy, and surgical or endoscopic removal of catheter via suprapubic tract have been mentioned in literature.

CONCLUSION

Traditional technique of performing suprapubic cystostomy for surgical removal of Foley's catheter are associated with complications such as wound site infection, urinary tract infection, haematuria, perivesical collection, surrounding organ injury, stone formation and should be reserved for hospital with limited facilities. Surgical removal with minimally invasive technique should be treatment of choice for encrusted and stucked urethral catheter.

Funding: No funding sources

Conflict of interest: None declared

Ethical approval: Not required

REFERENCES

1. Leuck AM, Wright D, Ellingson L, Kraemer L, Kuskowski MA, Johnson JR. Complications of Foley catheters—is infection the greatest risk? *J Urol.* 2012;187(5):1662-6.
2. Balasubramanian A, Singh AR, Alagumuthu G. Isolation and identification of microbes from biofilm of urinary catheters and antimicrobial susceptibility evaluation. *Asian Pac J Trop Biomed.* 2012;2(3):1780-3.
3. Getliffe KA, Mulhall AI. The encrustation of indwelling catheters. *BJU Int.* 1991;67(4):337-41.
4. Warren JW. Catheter-associated urinary tract infections. *Int J Antimicrob Agents.* 2001;17(4):299-303.
5. Singh D, Vasudeva P, Goel A. Egg shell” in bladder: a calculus around neglected Foley balloon catheter. *Indian J Urol.* 2010;26(2):299.
6. Wang R, Neoh KG, Kang ET, Tambyah PA, Chiong E. Antifouling coating with controllable and sustained silver release for long-term inhibition of infection and encrustation in urinary catheters. *J Biomed Mater Res Appl Biomater.* 2015;103(3):519-28.
7. Rath S, Mishra TS, Sasmal PK, Meher S. Pericatheter encrustations: an unusual cause of a retained Foley catheter. *BMJ Case Rep.* 2016;2015212379.
8. Rahul SK, Raj P, Tripathi B, Kumar P, Behera S, Mohapatra S. Management of retained Foley's catheter. *J Case Rep.* 2017;7(1):71-4.

Cite this article as: Paul SL, Deka A, Deka A. Innovative option for removal of encrusted, incarcerated longstanding indwelling Foleys catheter. *Int Surg J* 2021;8:749-51.