

## Case Report

# Traumatic posterior fossa extradural hematoma: case report and review of literature

Abhishek Songara, Harshad Govardhan Patil\*, Sharadendu Nayaran

Department of Neurosurgery, Sri Aurobindo Medical College and PG Institute, Indore, Madhya Pradesh, India

**Received:** 10 November 2015

**Revised:** 21 November 2015

**Accepted:** 16 December 2015

### \*Correspondence:

Dr. Harshad Govardhan Patil,  
E-mail: [dr.harshadpatil@gmail.com](mailto:dr.harshadpatil@gmail.com)

**Copyright:** © the author(s), publisher and licensee Medip Academy. This is an open-access article distributed under the terms of the Creative Commons Attribution Non-Commercial License, which permits unrestricted non-commercial

## ABSTRACT

Traumatic posterior fossa extradural hematoma (PFEDH) is rare lesion constituting less than 10% all extradural hematomas. Reliance on clinical findings alone is not recommended as these are nonspecific; it is advisable to conduct a computerized tomography (CT scan) of brain. The recommended treatment for traumatic posterior fossa extra dural hematoma is surgical evacuation soon after diagnosis because the posterior fossa contains vital structures. There have been an increasing number of cases of traumatic posterior fossa extra dural hematoma treated conservatively with good results both in children and in adults. The decision between surgery and observation is still controversial. In this article we present our experience in treating patients with traumatic PFEDH and discuss risk factors and outcome.

**Keywords:** Traumatic, Posterior fossa, Extradural haematoma

## INTRODUCTION

Posterior fossa extradural hematoma (PFEDH) is an uncommon complication of head injury. It accounts for approximately 0.3% of all craniocerebral injuries.<sup>1</sup> It constitutes 2.7-11% of all intracranial epidural hematomas (EDH).<sup>2</sup> In PFEDH clinical progress may be silent and slow, but sudden deterioration may occurred without significant warning signs. This may cause devastating consequences if not treated promptly.

Management of PFEDH can be either surgical or conservative. Most of the cases of PFEDH are managed by surgically; a small proportion can be managed nonoperatively. There are no specific criteria for deciding on the type of management. Many authors have taken into consideration different criteria for surgical evacuation including a volume >10 ml, >15 mm thickness of hematoma, a midline shift >5 mm or

obliteration of perimesencephalic cisterns, displacement of the fourth ventricle and the presence of hydrocephalus.<sup>2</sup>

There have been an increasing number of cases of traumatic posterior fossa extra dural hematoma treated conservatively with good results both in children and in adults. The decision between surgery and observation is still subject of debate.

Herein we present a case of traumatic PFEDH which was treated surgically and good postoperative clinical recovery was observed.

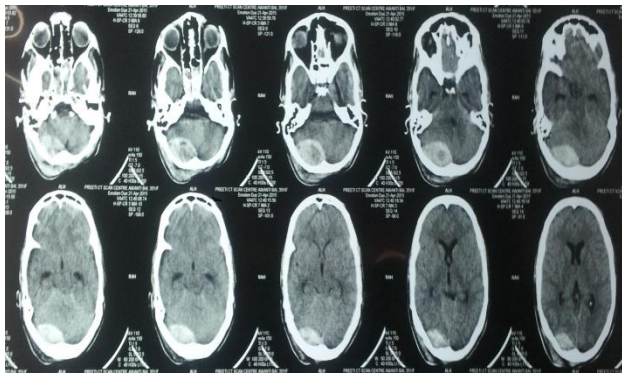
## CASE REPORT

A 35 years old female came to emergency department with alleged history of road traffic accident. On examination her Glasgow Coma Scale (GCS) score was

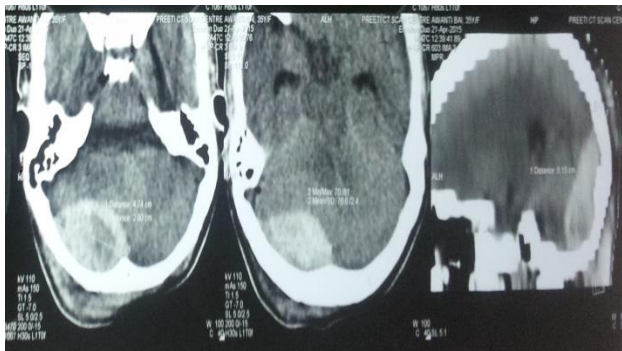9/15, pupils bilaterally normal size and sluggishly reacting. Patient had right occipital swelling. Computerised tomography (CT scan) of brain was done which revealed large right sided posterior fossa EDH with mass effect in the form of fourth-ventricle compression. It also revealed right sided undisplaced occipital bone fracture extending up to foramen magnum. Volume of the hematoma was calculated by using the ellipsoid volume equation.

$$\frac{A \times B \times C}{2}$$

Where A, B and C are the maximum diameter of hemorrhage in the 3 dimensions. It gives hematoma volume in cubic centimeters.<sup>3</sup>



**Figure 1: Noncontrast CT done at admission shows a large, right-sided, hyperdense biconvex PFEDH with mass effect.**



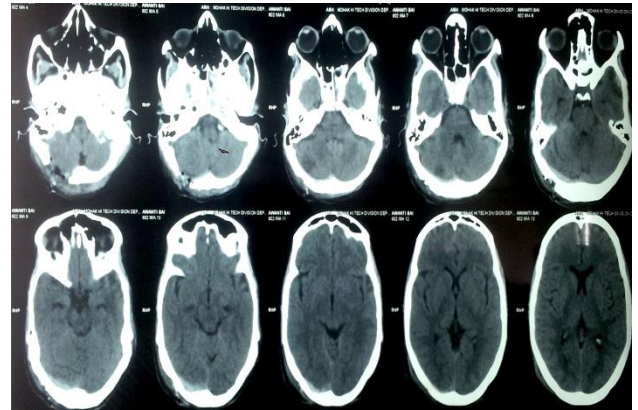
**Figure 2: Supratentorial extension of the EDH in the occipital region.**

As per ellipsoid formula volume was,

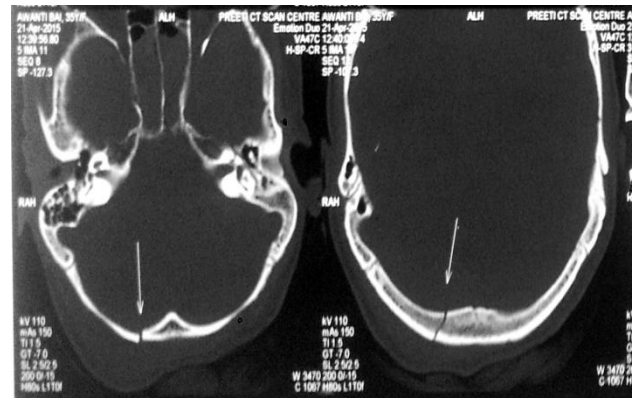
$$\frac{4.74 \times 2.60 \times 6.15}{2} = 37.89 \text{ cm}^3$$

In view of Poor GCS and CT finding patient was taken up for surgery. The patient was positioned prone on a horse-shoe head-rest. A unilateral paramedian suboccipital craniectomy was performed using a high-speed drill. There was large EDH present in right side of the posterior fossa with extension into supratentorial compartment. Evacuation of hematoma was done. After

the surgery patient's GCS was dramatically improved from 9 to 15. Postoperative CT imaging was done which revealed complete evacuation of hematoma.



**Figure 3: A postoperative image showing complete evacuation of the hematoma.**



**Figure 4: Bony windows showing a linear fracture of the occipital bone on the ipsilateral side.**

## DISCUSSION

Posttraumatic posterior fossa extradural hematoma is a rare condition. The Incidence is about 0.3% of all craniocerebral injuries, and it represents 4% to 12.9% of the entire group of extradural hematomas.<sup>4</sup>

Mortality is high in PFEDH is due to the small volume of the posterior fossa and contained important structures. A high index of suspicion is needed for timely intervention to prevent morbidity and mortality.<sup>5</sup>

Presence of occipital subgaleal haematoma and Battle's sign are clue to the diagnosis of PFEDH. Fracture of the occipital bone is an important sign and it mandates close observation and repeat CT scan later to diagnose these haematomas. Change in GCS or severe headache with vomiting and new onset cerebellar signs are associated features that help to clinch the diagnosis. Hydrocephalus may be observed in as high as 30 percent of cases on the CT scan.<sup>5</sup> In our patient fracture occipital bone and swelling was observed.

CT scan is the investigation of choice to detect PFEDH. The presence of haematoma more than 10 ml, hydrocephalus and displacement of the fourth ventricle are indications for surgery.<sup>6</sup> In our patient volume of hematoma was 37.89 cm<sup>3</sup> so we subjected the patient for emergency surgery.

Surgery remains the gold standard for the treatment of symptomatic PFEDH. This may be in the form of suboccipital craniectomy or craniotomy depending on the size of the haematoma.<sup>7</sup>

The PFEDH may be associated with coexisting supratentorial injuries such as hematoma or contusion. In the literature, supratentorial pathologies associated with PFEDH have been reported in as high as 50%-87.5%.<sup>7</sup> In our patient no supratentorial pathology was present.

Conservative management is an option if the patient is asymptomatic and has good GCS. The patient should be kept under close monitoring in the neurosurgical intensive care unit (ICU). There are some case reports in the literature about these haematomas which resolved spontaneously without any intervention.<sup>8</sup>

The rapidity of onset and initial GCS are the main factors that determine the overall prognosis. Acute haematomas often carry a high mortality with the range of 12%-70%.

Many studies indicate that aggressive surgical management is must in all cases of PFEDH to prevent morbidity and mortality.

## CONCLUSION

The posterior fossa is an uncommon site for epidural haematomas. Clinical progress is silent and slow, but the deterioration is sudden and quick. It can be fatal if not promptly treated. Early recognition is extremely important. The recommended treatment for posterior fossa epidural hematoma is surgical evacuation soon after

the diagnosis, since the posterior fossa is small and it contains vital structures.

*Funding: No funding sources*

*Conflict of interest: None declared*

*Ethical approval: Not required*

## REFERENCES

1. Campbell E, Whitfield Rd, Greenwood R. Extradural hematomas of the posterior fossa. Ann Surg. 1953;138(4):509-20.
2. Bozbuga M, Izgi N, Polat G, Gurel I. Posterior fossa epidural hematomas: observations on a series of 73 cases. Neurosurg Rev. 1999;22:34-40.
3. Kothari RU, Brott T, Broderick JP, Barsan WG, Sauerbeck LR, Zuccarello M, Khoury J. The ABCs of measuring intracerebral hemorrhage volumes. Stroke. 1996;27(8):1304-5.
4. Garza-Mercado R. Extradural hematoma of the posterior cranial fossa. Report of seven cases with survival. J Neurosurg. 1983;59(4):664-72.
5. Bozbuga M, Izgi N, Polat G, Gürel I. Posterior fossa epidural hematomas: observations on a series of 73 cases. Neurosurg Rev. 1999;22(1):34-40.
6. Malik NK, Makhdooni R, Indira B, Shankar S, Sastry K. Posterior fossa extradural hematoma: our experience and review of the literature. Surg Neurol. 2007;68(2):155-8.
7. Balik V, Lehto H, Hoza D, Sulla I, Hernesniemi J. Posterior fossa extradural haematomas. Cent Eur Neurosurg. 2010;71(4):167-72.
8. Kang SH, Chung YG, Lee HK. Rapid disappearance of acute posterior fossa epidural hematoma. Neurol Med Chir (Tokyo). 2005;45(9):462-3.

**Cite this article as:** Songara A, Patil HG, Nayaran S. Traumatic posterior fossa extradural hematoma: case report and review of literature. Int Surg J 2016;3:369-71.