

Original Research Article

Laparoscopic management of liver abscess: a viable alternative in USG guided percutaneous drainage failure cases

Nikhil Tak*, Rajendra Bagree, Gaurav Jalendra, Hetish M. Reddy

Department of Surgery, S. M. S. Medical College and Hospital, Jaipur, Rajasthan, India

Received: 30 October 2020

Revised: 20 December 2020

Accepted: 24 December 2020

*Correspondence:

Dr. Nikhil Tak,

E-mail: nikhiltak08@gmail.com

Copyright: © the author(s), publisher and licensee Medip Academy. This is an open-access article distributed under the terms of the Creative Commons Attribution Non-Commercial License, which permits unrestricted non-commercial use, distribution, and reproduction in any medium, provided the original work is properly cited.

ABSTRACT

Background: Liver abscesses are conventionally treated by ultrasonography (USG) guided percutaneous aspiration or drainage under antibiotic cover. We performed laparoscopic liver abscess drainage successfully in patients where medical management and percutaneous drainage had proven inadequate.

Methods: Cases were received either from outpatient department (OPD) or were transferred from medical wards. Patients were first treated conservatively and percutaneous aspiration was attempted. Patients not responding to these treatment modalities were considered for diagnostic laparoscopy with drainage of abscess cavity and placement of 28 Fr drain under vision.

Results: 20 patients with large liver abscess were treated successfully by laparoscopic drainage. Mean age in the study was 47 years (range 19-70 years) and average hospital stay was 5 days (range 4-12 days). Major postoperative morbidity or deaths were not registered. Patients with ruptured liver abscess, deep seated abscess cavity and medically unfit patients were excluded from the study.

Conclusions: Laparoscopic drainage of liver abscesses, in combination with systemic antibiotics is a safe and viable alternative in all patients who require surgical drainage. It helps in the early return of gastrointestinal function and resumption of normal activities also potentially achieving better abscess drainage.

Keywords: Liver abscess, Laparoscopic drainage, USG guided percutaneous drainage

INTRODUCTION

Liver abscess is defined as a pus-filled cavity in the liver that can develop from injury to the liver or an intra-abdominal infection disseminated from the portal circulation.¹ The majority of these abscesses are categorized into amoebic or pyogenic although a minority are caused by parasites and fungi. Most amoebic infections are caused by *Entamoeba histolytica*. The pyogenic abscesses are usually polymicrobial but some organisms are seen more commonly in them, such as *E. coli*, *Klebsiella*, *Streptococcus* and anaerobes. It is essential to understand the severity of these abscesses because of the high mortality in untreated patients.² The annual incidence rate is about 2.3 cases per 100,000 people

which is significantly higher in low socio economic groups and developing countries. Males are more frequently affected than females.³

Liver amoebiasis is the commonest extraintestinal manifestation of the infection by *E. histolytica*, complicating the course of the disease in 3-10% of the subjects infected by this microorganism.⁴ Abscesses result from the invasion and multiplication of microorganisms, entering mostly through the blood vessels or by the way of the biliary ductal system.⁵ At present, liver abscesses are mainly treated by USG guided percutaneous aspiration or drainage under antibiotic cover with a good success rate.⁶ If interventional radiology fails, surgical drainage becomes necessary. Laparoscopic surgery can be a viable

alternative before open abscess drainage is considered. The objective of this study was to prove the efficacy and safety of laparoscopic liver abscess drainage in ultrasonography (USG) guided percutaneous drainage failure cases.

METHODS

Patients

An observational study was done to assess results of laparoscopic drainage as treatment of liver abscess for patients admitted between June 2018 to July 2020 at SMS Medical College & Hospitals, Jaipur. Patients who were not fit for general anaesthesia, below the age of 16, pre-existing coagulopathy, ruptured liver abscess and patients who had prior history of surgery were excluded from the study. As the study was hospital based observational type, no ethical committee approval was required.

20 patients were selected after thorough clinical examination. Routine blood investigations along with liver function test and coagulation profile was done. Ultrasound and computed tomography (CT) scan of abdomen was taken for all patients. Patients were empirically started on injection metronidazole 750 mg intravenous (IV) ter die sumendum or 3 times a day (TDS) and injection ceftriaxone 1 gm IV twice a day (BD), treatment was revised based on culture and sensitivity reports. Patient demographics, initial volume of pus drained, duration of the operation, duration of hospital stay, comorbidities and complications of the procedure were observed and documented.

Procedure

Under general anesthesia, initial peritoneal access for pneumoperitoneum was achieved with standard technique. A 10 mm laparoscope was introduced at supra umbilical position. Subsequent port positions depended on the pathology seen after the initial peritoneal exploration. In cases of right lobe abscess, one 10 mm port was placed at right subcostal position between mid clavicular and anterior axillary line. Another 5 mm port is placed in the epigastric region.

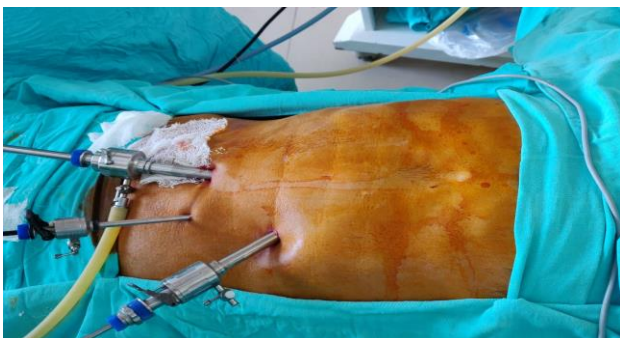

Figure 1: Port position for drainage of left lobe liver abscess.

The adhesions between the liver and the diaphragm as well as the anterior abdominal wall were freed to expose the area of the liver where the abscess was pointing. Abscess cavity was opened bluntly by suction nozzle instrument and pus drained. Abscess cavity was irrigated thoroughly with normal saline and cleared of debris. A 28 Fr abdominal drain was placed inside the cavity via the right 10 mm sub costal port and fixed exteriorly to skin, in the process samples for bacterial cultures were taken. Finding of anchovy-sauce-like fluid supported the diagnosis of amoebic liver abscess.

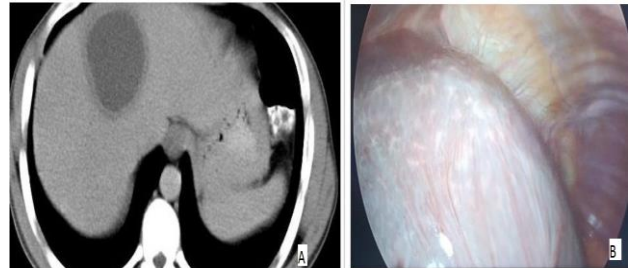


Figure 2: (a) CECT whole abdomen showing liver abscess of size 50x48 mm in right lobe of liver, and (b) laparoscopic view of left lobe abscess.

RESULTS

Management of amoebic liver abscess is focused on the elimination of the infectious agent and obliteration of the abscess cavity in order to prevent its complications, especially rupture. 20 patients were worked up with the intent of carrying out laparoscopic drainage of liver abscess. They were receiving treatment in the internal medicine/general surgery units for 1 to 4 weeks before decision for laparoscopic drainage was made. Age range of patients was 16-70 years and male to female ratio was 4:1.

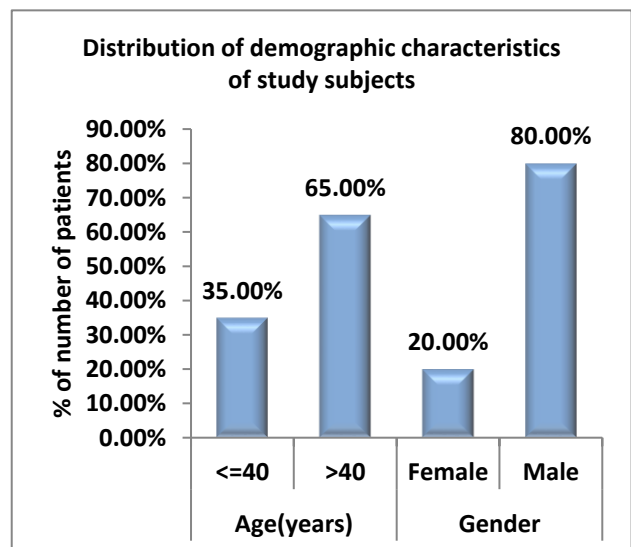


Figure 3: Distribution of demographic characteristics of study subjects.

The ultrasound scan suggested the abscess cavity to be in between 4-12 cm in diameter. The volume of the initial aspirate ranged from 50 to 400 ml. Mean operating time was approximately 40 minutes. In our study 75% of patients had abscess located in the right lobe of liver, which is very similar to previous randomized controlled comparative study conducted by Singh et al in 2013, who reported 78.4% of patients with right lobe liver abscesses.⁷

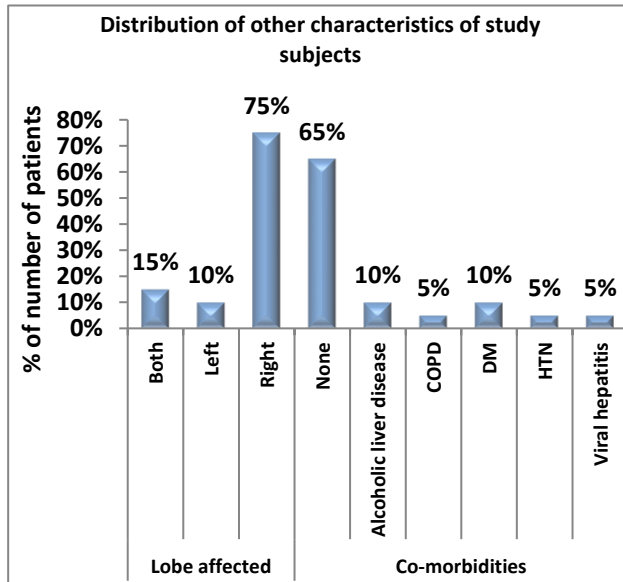


Figure 4: Distribution of other characteristics of study subjects.

There was no conversion to open surgery and no postoperative mortality was recorded. The postoperative hospital stay was between 4-12 days.

Statistical method

Analysis was done using statistical package for social sciences (SPSS) version 21.0.

DISCUSSION

A major breakthrough occurred in the management of hepatic abscesses about four decades ago, and with it the exceptionally high mortality associated with this disease condition has been drastically reduced.⁸ The first line of management has largely become ultrasound or CT-guided percutaneous drainage in combination with antimicrobial agents. This approach has shown significant advantage in being safe and efficacious with low-cost. The indications for surgical drainage have thus reduced. Failure of conservative therapy, rupture of the abscess, presence of multiloculated abscesses and complications from percutaneous drainage may necessitate surgical intervention. The surgical option also has the added advantage of accurate positioning of drainage catheter and simultaneous treatment of the abscess and other underlying abdominal pathology.^{9,10}

Although percutaneous placement of an indwelling catheter is the method most widely preferred to drain liver abscesses, it has its own disadvantages like prolonged hospital stay and catheter related complications. Placement of percutaneous catheter itself may cause bacteremia in spite of antibiotic administration and large multiloculated abscesses are difficult to drain via percutaneous interventions. The overall failure rate of percutaneous catheter drainage is 15-36% and often procedures have to be either repeated due to failure or supplemented with surgical approach.¹¹ Failure often occurs due to difficulty in accessing and inability to approach certain segments of liver such as caudate lobe abscess through percutaneous interventional techniques.¹² Laparoscopic drainage offers excellent results in such cases and avoids the delay in treatment.

Various reports have explored the laparoscopic approach in the management of liver abscesses. Whereas it could be argued that this may be an unnecessarily expensive modality of treatment, the known benefits of minimally invasive surgery present a compelling response. It offers a middle ground between open surgical and percutaneous drainage. On one hand it helps in the early return of gastrointestinal function and resumption of normal activities; on the other hand it potentially achieves a better abscess drainage.^{13,14} More importantly laparoscopic drainage has been shown to be safe. There was neither mortality nor conversion to open surgery in our series, which is in line with other reports in the literature.¹⁵

The value of a trained radiologist cannot be discounted for the successful conduct of percutaneous drainage. The procedure can have uncommon but serious complications.¹⁶⁻¹⁸ Trained personnel may be a challenge in some developing countries, a reason for continued persistence with open surgical drainage.

A study on therapeutic effectiveness of laparoscopic drainage and image guided pigtail catheter drainage in the treatment of liver abscess showed mean average pain score were significantly higher in image guided pigtail drainage group than in laparoscopic drainage group. The time taken for more than 50% resolution and for total resolution of abscess cavity size in the laparoscopic drainage group is significantly less than the time taken by the pigtail drainage group. The average duration of hospital stay with pigtail catheter drainage is significantly higher than the average duration of hospital stays with laparoscopic drainage. They conclude that laparoscopic drainage of liver abscess is superior to image guided pigtail catheter drainage in terms of post-operative pain, hospital stay post procedure and resolution of abscess cavity.¹⁹

Limitations

Multi-centric and large sample size are required to establish the efficacy of laparoscopic liver abscess drainage in failed cases of USG guided percutaneous drainage procedure.

CONCLUSION

Laparoscopic drainage of liver abscesses, in combination with systemic antibiotics, is a safe and viable alternative in all patients who require surgical drainage following failed medical management or USG guided percutaneous drainage.

It is the method of choice in cases of difficulty in approach to pigtail drainage, failed pigtail drainage and in case of residual or recurrent abscess. Other advantages being quicker recovery and decreased hospital stay.

Funding: No funding sources

Conflict of interest: None declared

Ethical approval: The study was approved by the Institutional Ethics Committee

REFERENCES

1. Mischnik A, Kern WV, Thimme R. Pyogenic liver abscess: Changes of Organisms and Consequences for Diagnosis and Therapy. *Dtsch Med Wochenschr.* 2017;142(14):1067-74.
2. Czerwonko ME, Huespe P, Bertone S, Pellegrini P, Mazza O, Pekolj J. Pyogenic liver abscess: current status and predictive factors for recurrence and mortality of first episodes. *HPB (Oxford).* 2016;18(12):1023-30.
3. Kaplan GG, Gregson DB, Laupland KB. Population-based study of the epidemiology of and the risk factors for pyogenic liver abscess. *Clin Gastroenterol Hepatol.* 2004;2(11):1032-8.
4. Hughes MA, Petri Jr WA. The Genuine Works of Hippocrates. Amoebic liver abscess. *Infect Dis Clin North Am.* 2000;14:565-82.
5. Hippocrates, Adams F. The Genuine Works of Hippocrates. New York: William Wood and co. 1886.
6. Zerem E, Hadzic A. Sonographically guided percutaneous catheter drainage versus needle aspiration in the management of pyogenic liver abscess. *Am J Roentgenol.* 2007;189(3):138-42.
7. Branum G, Tyson G, Branum M. Hepatic abscess changes in etiology, diagnosis and management. *Ann Surg.* 1990;212(6):655-6.
8. Dhamodharan SR, Christeena Indrani J. *Int J Dent Med Sci Res.* 2018;2(9):1-11.
9. Singh S, Chaudhary P, Saxena N, Khandelwal S, Poddar DD, Biswal UC. Treatment of liver abscess: Prospective randomized comparison of catheter drainage and needle aspiration. *Ann Gastroenterol.* 2013;26:332-9.
10. Ng SS, Lee JF, Lai PB. Role and outcome of conventional surgery in the treatment of pyogenic liver abscess in the modern era of minimally invasive therapy. *World J Gastroenterol.* 2008;14:747-51.
11. Dhir U, Ghuman SS, Singhri S. Caudate lobe liver abscess: early surgical drainage. *J Liver Res Disord Ther.* 2018;4(11):49-51.
12. Naseer AA, Walid M, Abd EM. Abscess of the caudate lobe of liver, a rare disease with a challenging management: a case report. *J Biomedical Res.* 2013;27(5):430-4.
13. Ferraioli G, Garlaschelli A, Zanaboni D, Gulizia R, Brunetti E, Tinozzi FP, et al. Percutaneous and surgical treatment of pyogenic liver abscesses: Observation over a 21-year period in 148 patients. *Dig Liver Dis.* 2008;40:690-6.
14. Tan L, Zhou HJ, Hartman M, Ganpathi IS, Madhavan K, Chang S. Laparoscopic drainage of cryptogenic liver abscess. *Surg Endosc.* 2013;27:3308-14.
15. Aydin C, Piskin T, Sumer F, Barut B, Kayaalp C. Laparoscopic drainage of pyogenic liver abscess. *JLS.* 2010;14:418-20.
16. Cappuccino H, Campanile F, Knecht J. Laparoscopy-guided drainage of hepatic abscess. *Surg Laparosc Endosc.* 1994;4:234-7.
17. Lorenz J, Thomas JL. Complications of percutaneous fluid drainage. *Semin Intervent Radiol.* 2006;23:194-204.
18. Chandrashekhara SH, Gamanagatti S, Arora R, Goyal P, Saraya A. Percutaneous management of inadvertently inserted catheter into inferior vena cava during liver abscess drainage. *Cardiovasc Intervent Radiol.* 2010;33:1066-8.
19. Tay KH, Ravintharan T, Hoe MN, See AC, Chng HC. Laparoscopic drainage of liver abscesses. *Br J Surg.* 1998;85:330.

Cite this article as: Tak N, Bagree R, Jalendra G, Reddy HM. Laparoscopic management of liver abscess: a viable alternative in USG guided percutaneous drainage failure cases. *Int Surg J* 2021;8:637-40.