

Original Research Article

Autologous breast fibrofatty flaps for immediate breast reconstruction after excision of small cancer mass (<50 mm) improves surgical and aesthetical outcomes and patients' quality of life

Waseem A. Shoda^{1*}, Shereen M. Abdel Wahab²

¹Department of General Surgery, Mansoura Military Hospital, Mansoura, Egypt

²Department of Community Environmental and Occupational Medicine, Faculty of Medicine, Benha, Egypt

Received: 21 October 2020

Revised: 08 November 2020

Accepted: 09 November 2020

*Correspondence:

Dr. Waseem A. Shoda,

E-mail: dr.waseem.pf.2009@gmail.com

Copyright: © the author(s), publisher and licensee Medip Academy. This is an open-access article distributed under the terms of the Creative Commons Attribution Non-Commercial License, which permits unrestricted non-commercial use, distribution, and reproduction in any medium, provided the original work is properly cited.

ABSTRACT

Background: Evaluation of surgical feasibility, aesthetic outcomes and 6-m postoperative (PO) effect of immediate breast reconstruction (IBR) using autologous fibrofatty flaps after localized small breast mass excision.

Methods: Total 29 women had duct carcinoma of <50 mm in diameter with N1-3 regional lymphadenopathy were studied. Through diamond-shape incision, breast gland was removed with 1 cm circumferential free safety margin, then the medial and lateral fibrofatty flaps were undermined and approximated for IBR. Breast measurements; the nipple-to-suprasternal notch distance and the nipple-to-nipple distance were determined preoperatively and 6-m PO. Quality of life (QoL) evaluation was performed preoperatively and 6-m PO using the short-form-36 (SF-36), the multidimensional body self-relations questionnaire appearance assessment and the European organization for research and treatment of cancer breast cancer-specific QoL questionnaire scores in breast cancer.

Results: Mean operative time was 94.5±15.4 min; mean intraoperative blood loss was 170.1±34.9 ml and 25 patients had returned home on the same operative day. Two patients had PO wound seroma and one patient had wound hematoma, but were resolved spontaneously. PO breast measurements showed non-significant differences in comparison to preoperative measurements of the same breast, and to measurements of the contralateral breast. PO evaluation of QoL showed significantly improved PO scoring in line with improved body image and future perspectives, and sexual scores in comparison to preoperative scorings.

Conclusions: The applied procedure of localized excision of BC mass of <50 mm with IBR using the breast remnant fibrofatty flaps provided acceptable surgical and esthetical outcomes and allowed improvement of patients' QoL.

Keywords: Immediate breast reconstruction, Small breast mass (<50 mm), Quality of life questionnaire, Functional breast function evaluation

INTRODUCTION

Early diagnosis and precise treatment with reduced adverse reactions are the main goal of management strategies for cancer, which became a global epidemic disease responsible for annual death rate of about 10 million worldwide.¹

Oncoplastic surgery is a well-established discipline that combines conserving treatment for breast cancer (BC) with immediate plastic reconstruction and is widely practiced for being safe and reliable treatment option for the managing of invasive breast cancer.^{2,3}

Breast conservation surgery (BCS) continues to be the most popular form of breast cancer surgery, but with its

continuous expansion, there has been increased interest in personalized techniques of breast reconstruction.⁴ Breast reconstruction remains an important field in plastic surgery and immediate breast reconstruction (IBR) following breast cancer surgery, which includes a wide range of autologous and alloplastic reconstructions is highly used in increasing rates.⁶

Autologous breast reconstructions are characterized by their durability, aesthetic outcomes and symmetry with potential aesthetic enhancement at the donor site.⁷ Therapeutic mammoplasty is a well-established advanced oncoplastic technique for larger tumors in large breasts.⁸ Few series report on experience with fat grafting as the primary form of breast reconstruction.⁶ The lipo-filled mini dorsi flap technique is an efficient, elegant, and less invasive procedure, which can be performed easily and quickly and allowed getting excellent long-term results for immediate breast reconstruction.⁹

Hypothesis

The current study assumes that dissection and approximation of autologous fibrofatty flaps after localized breast mass excision allows IBR with acceptable surgical and aesthetic outcomes.

Objectives

Objectives of this study were evaluation of surgical feasibility, aesthetic outcomes and 6-m PO effect, on patients' quality of life (QoL), of the hypothesized IBR technique for small BC mass of <50 mm in its greatest diameter.

METHODS

Design

Prospective selective study.

Setting

Department of General Surgery, Mansoura Military Hospital in conjunction with multiple private centers, Cairo and Community, Industrial and Public Health Department, Faculty of Medicine, Benha, Egypt.

Patients & methods

The current study was conducted according to the conditions of the Local Ethical Committee since June 2016 to June 2020. All women presenting with breast mass were evaluated for inclusion in the study. The US National comprehensive cancer network described locally advanced breast cancer as that fulfils any of the following criteria in the absence of distant metastasis: tumors size is <50 mm with N1-3 regional lymphadenopathy, Tumors of any size with direct extension to the chest wall and/or skin, regardless of regional lymphadenopathy or the

presence of clinically fixed or matted axillary lymph nodes, or any of infraclavicular, supraclavicular, or internal mammary lymphadenopathy) regardless of tumor stage.¹⁰ The current selective study was designed to include patients had mass of duct carcinoma and luminal A or B, <50 mm in its greatest diameter on mammography, with N1-3 regional lymphadenopathy, no direct extensions to chest wall, no fixed or matted LN.

Exclusion criteria included masses that were not fulfilling the NCCN criteria, multicentric mass, advanced cancer breast, diabetes mellitus, hypertension, local skin diseases, small-sized breast or previous contralateral mass excision or mastectomy. All patients underwent clinical general and local examinations, breast ultrasonography (USG), digital mammography (MMG), distant metastasis detection workup, cervico-thoracic radiological examinations and routine lab examinations. The MMG and USG evaluations were performed according to The American College of radiology breast imaging reporting and data system.¹¹

Surgical technique

All surgical procedures were performed under general inhalational anesthesia with tracheal intubation. The affected breast and its ipsilateral axilla were sterilized using povidine iodine solution and sterile towels were applied exposing the breast and ipsilateral upper limb. A diamond-shape incision, including the tumor cutaneous projection in the middle was made (Figure 1).

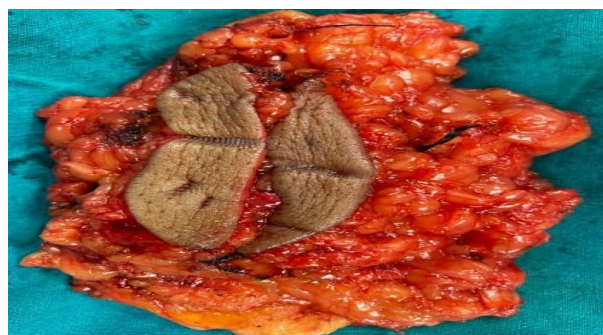

Figure 1: Complete mass excision with safety margin.

The breast gland was removed until the fascial plan of the underlying muscle (Figure 2). The lateral thickness of removed healthy gland was at least 1 cm from the neoplasm [a circumferential safety margin], frozen pathological examination was performed to assure free safety margin. Then, axilla was evacuated of lymph nodes and with the axillary pad of fat (Figure 3).

The medial and lateral fibrofatty flaps were undermined (Figure 4, 5) and both flaps were approximated for IBR (Figure 6, 7) and then the wound was drained and closed. Crib bandage was applied for one week and supporting bra suitable for the new breast size was wear for 2 months.

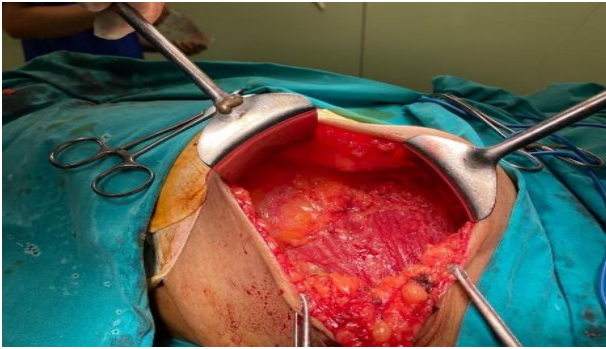


Figure 2: Complete mass removal till underlying muscles' facial planes.

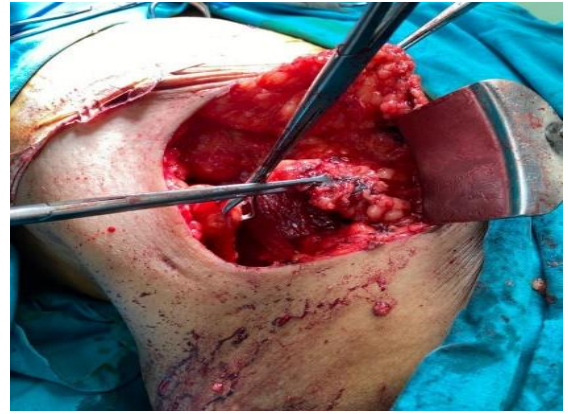


Figure 6: Approximation of both fibrofatty flaps.

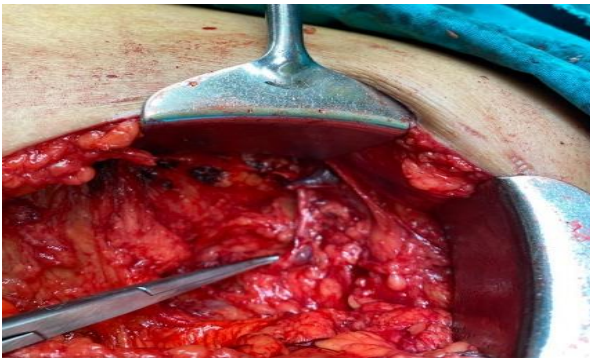

Figure 3: Axillary evacuation.

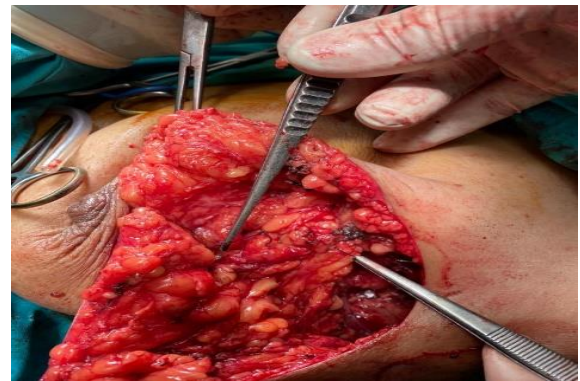


Figure 7: Breast reconstruction using the approximated flaps.

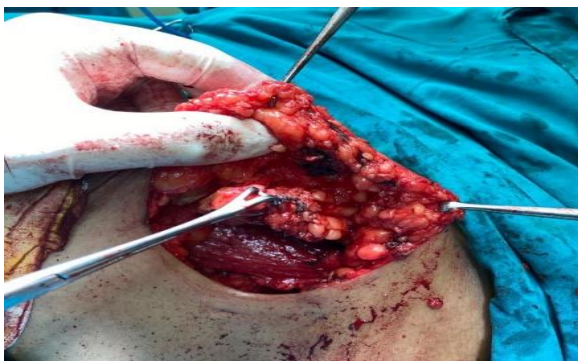

Figure 4: Dissection and undermining of medial fibrofatty flap.

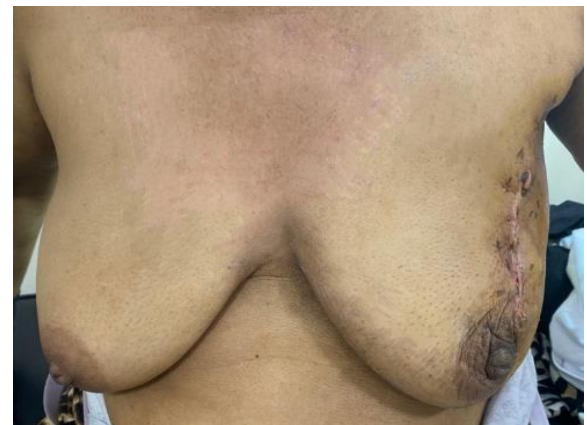

Figure 8: PO appearance showing breast symmetry with nipples on the same level.

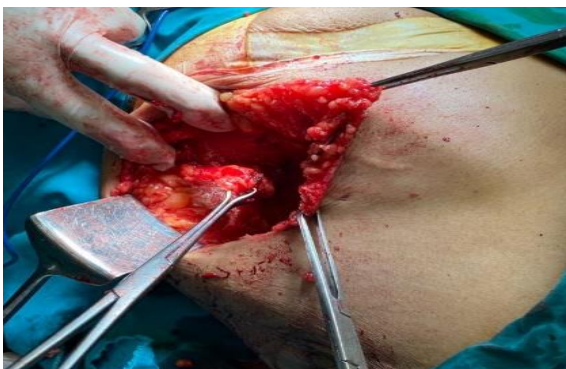

Figure 5: Dissection and undermining of medial fibrofatty flap.

Postoperative care

Immediate PO care

All patients were transferred to post-anesthetic care unit till being ready to ward-admission. Wound pain was managed by intravenous ketolac diluted in 10-cc normal saline and repeated if required. The vacuum drainage was followed-up and the amount, quality and color were

recorded and patient was allowed to go home if no bleeding was detected.

Short-term follow-up

Vacuum drains were removed when no new collection was noticed. Wound stitches were removed on the 5-7th PO day according to adequacy of wound healing

QoL evaluation

The short-form-36 (SF-36) is a multi-function scale including 8-domains evaluating the physical function (10 items); role physical (4 items); bodily pain (2 items); general health (5 items), vitality (4 items); social functioning (2 items); role emotional (4 items); and mental health (5 items). The SF-36 scoring varies from zero to 100 with 100 being the best possible score and zero being the lowest possible score.¹² The Multidimensional body Self relations questionnaire appearance assessment (MBSRQ-AS) is a self-report 69-item inventory for the assessment of self-attitudinal aspects of the body-image construct. Scores vary from one to five. High scorers feel mostly positive and satisfied with their appearance; low scorers have a general unhappiness with their physical appearance.¹³ Both SF-36 and MBSRQ-AS questionnaires were conducted preoperatively and four weeks PO. The European organization for research and treatment of cancer breast cancer-Specific Quality of Life Questionnaire scores in breast cancer (EORTC QLQ-BR23) includes four functional scales [body image, sexual function & satisfaction, and future perspective] and four symptom scales [side-effects of systemic treatment, breast symptoms, arm symptoms and bothered by hair loss]. Each item was score from zero to 100 with high scores of functional scales represent better functioning, and high scores of symptom scales show higher issues.¹⁴ Only the functional scales were evaluated both before and 6-m after surgery.

Evaluation measures

Breast measurements included nipple-to-suprasternal notch and nipple-to-nipple distances were performed preoperative and 6-m PO.

Statistical analysis

Sample size could not be predicted due to the slow flow of cases and the limitation of the inclusion criteria for only cases had mass of <50 mm and this was the trend for multiple studies tried a new procedure.¹⁵⁻¹⁸ Obtained data were presented as mean, standard deviation, numbers and percentages. Results were analyzed using paired t-test for analysis within each group. Statistical analysis was conducted using the SPSS (Version 15, 2006) for Windows statistical package. P<0.05 was considered statistically significant.

RESULTS

The study included 39 women had breast cancer; 10 women were excluded for not fulfilling the inclusion criteria and 29 women were included in the study. Enrollment data of these women are shown in (Table 1).

Table 1: Patients' enrollment data.

Data	Findings (%)	
Age (years)	≤30	2 (6.9)
	>30-40	8 (27.6)
	>40	5 (17.2)
	>50	14 (48.3)
	Total	45.4±10.7
Body weight (kg)	88±7.4	
Body height (cm)	169.6±2.2	
Body mass index (kg/m ²)	Overweight (<30)	10 (34.5)
	Obese (30-35)	19 (65.5)
	Total	30.6±2.4
Number of living offspring	0	2 (6.9)
	1	5 (17.2)
	2	9 (31.1)
	3	5 (17.2)
	4	6 (20.7)
	>4	2 (6.9)
Total	2.5±1.5	
Lesion laterality	Right	21 (44.8)
	Left	16 (55.2)
Blood pressure measures (mmHg)	Systolic	118.1±3.5
	Diastolic	78.2±4.9
Fasting blood glucose (mg/dl)	90.2±7.3	

Data are presented as mean, standard deviation, numbers and percentages

Table 2: Operative and postoperative surgical data.

Data	Findings (%)	
Operative time (min)	60-90	16 (55.2)
	>90-120	11 (37.9)
	>120	2 (6.9)
	Total	94.5±15.4
Intraoperative blood loss (ml)	≤100	1 (3.4)
	>100-200	21 (72.5)
	>200	7 (24.1)
	Total	170.1±34.9
PO hospital stay	Same operative day	25 (86.3)
	1-day PO	3 (10.3)
	2-days PO	1 (3.4)
PO complications (per breast)	No	53 (89.7)
	Seroma	2 (6.9)
	Hematoma	1 (3.4)
	Wound sloughing	0

Data are presented as mean, standard deviation, numbers and percentages; PO: postoperative

Mean operative time was 94.5±15.4 min; 13 cases required operative time longer than 90 min for completion of surgery. Mean intraoperative blood loss was 170.1±34.9 ml and blood losses were in range of 100-200 ml in 21 patients.

Twenty-five patients had returned home on the same operative day, 3 patients were discharged 24-hr PO and only one patient required hospital stay for 48-hr. Only three patients had PO complications; 2 had wound seroma and one patient had wound hematoma and all were managed conservatively (Table 2).

Fortunately, PO breast measurements (Figure 9, 10) showed non-significant differences in comparison to preoperative measurements of the same breast, and in comparison, to measurements of the contralateral breast (Table 3).

Table 3: PO breast measurements compared preoperative measurements.

Data		Findings	
Breast projection (mm)	Same breast	Preoperative	79.3±7.4
		PO	79±5
		P value	0.852
	Contralateral breast	Measurement	80.2±5.7
		P2 value	0.608
		P3 value	0.395
Sternal notch to nipple distance (cm)	Same breast	Preoperative	33±3.3
		PO	31.6±6.5
		P value	0.101
	Contralateral breast	Measurement	32.9±6.8
		P2 value	0.649
		P3 value	0.909
Nipple-to-Nipple distance (cm)	Preoperative	32±3.6	
	PO	31±3.9	
	P value	0.316	

Data are presented as mean, standard deviation, numbers & percentages; p value indicates the significance of difference between pre- and post-operative measurements; P<0.05 indicates significant difference; P>0.05 indicates non-significant difference

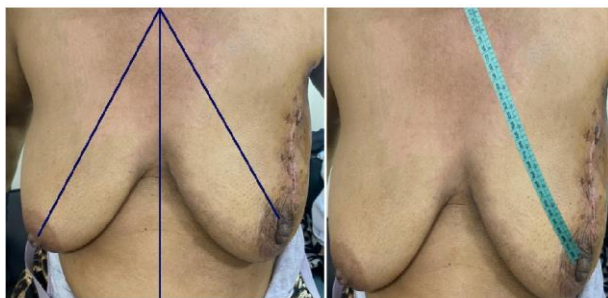

Figure 9: Nipple-to-suprasternal notch distance.

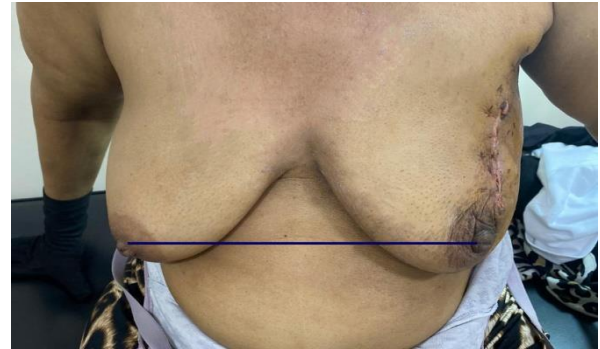


Figure 10: Nipple-to-nipple distance and level.

PO evaluation of QoL using SF-36 and MBSRQ-AS scores showed significantly improved PO scoring in line with improved PO EORTC QLQ-BR23 score in comparison to preoperative scorings (Table 4).

Table 4: PO QoL scoring compared preoperative scores.

Questionnaire	Findings		
SF-36	Preoperative		38.4±10.3
	PO		70±13.6
	P value		<0.0001
MBSRQ-AS	Preoperative		140.1±41.8
	PO		207.7±45.7
	P value		<0.0001
EORTC QLQ-BR23 [functional scales]	Pre-operative	PO	P value
	Body image	45.1±8.9	64.7±12.6
Sexual function	6.1±15.7	75.6±12.9	0.0144
Sexual satisfaction	57.3±18.2	71.1±14.7	0.0024
Future perspective	28.8±8.7	74.8±19.2	<0.0001

Data are presented as mean, standard deviation, numbers and percentages; PO: postoperative; p value indicates the significance of difference between pre- and post-operative measurements; P<0.05 indicates significant difference; P>0.05 indicates non-significant difference

DISCUSSION

The short-term outcomes of the applied oncoplastic surgical procedure that combines conserving treatment with IBR showed no procedure-related complications. In support of the application of oncoplastic surgery including IBR for localized BC masses, Lombardi et al found no statistically significant differences regarding overall survival, disease-related survival, local recurrence or positive margins between patients who underwent breast oncoplastic approach and patients who received conservative surgery alone and concluded that oncoplastic surgery for primary invasive BC is a feasible procedure and oncological safe surgical option.³ Also, Dorogi et al conducted a survey on the opinions of the Hungarian BC population about a modern breast reconstruction system and found the majority of women

would like to have nakedly also similar breasts after the reconstruction process.¹⁹

The results of the current study could be attributed to its selective base so as to include only breast mass of <50 mm in its greatest diameter on mammography; this allowed reduction of operative time and minimized intraoperative blood loss with favorable PO surgical outcome as only one case developed minor hematoma and two cases developed seroma, but both resolved spontaneously and no case had wound infection or dehiscence. These data point to the favorable surgical outcome of the applied breast conserving procedure for localized small-sized advanced BC masses. In support of the rationale for patients' selection for each procedure to improve outcome, Kosasih et al reported no significant difference between oncoplastic breast conserving surgery and traditional techniques regarding cancer recurrence and re-operation rate, and concluded that oncoplastic breast conserving surgery (BCS) is of comparable oncological safety to more established surgical procedures and a useful option in suitable patients.²⁰

In support of safety and efficacy of oncoplastic BCS, irrespective of the applied procedure, Borm et al documented that immediate oncoplastic surgery seems not to affect the effectiveness of adjuvant whole breast radiotherapy on local control rates in BC patients.²¹ Also, Pearce et al reported that long-term follow-up after extreme oncoplastic breast conserving surgery allowed concluding that the procedure is safe for patients with bulky tumors (≥ 50 mm) normally treated by mastectomy without risking local control.²²

Moreover, Niinikoski et al reviewed 1800 consecutive patients with primary invasive BC and reported no difference in reoperation rate or local recurrences between oncoplastic BCS and conventional mastectomy for larger, multifocal and more aggressive tumors and concluded that oncoplastic BCS is as safe as conventional BCS enabling breast conserving for patients who otherwise were candidates for mastectomy.²³

The applied procedure provided favorable surgical and aesthetical outcomes as evidence by the non-significant differences between pre- and postoperative breast measurements and between both breasts. These findings point to the feasibility of restoration of acceptable breast configuration with the use of autologous breast fibrofatty flaps for IBR and sparing additional procedures for breast reconstruction and prevented the additional surgical trauma to prepare musculofatty flaps or the implant use for breast reconstruction.

Moreover, the applied procedure significantly improved patients' QoL scorings in comparison to their preoperative scores with significant improvement of EORTC QLQ-BR 23 domain scorings.

In line with the necessity of evaluation of patients' QoL before and after BC management and the impact of the results of these evaluations on surgical decision making, Türk et al showed that the mastectomy has a negative impact on body image and QoL of women and there was a strong positive correlation between body image and QoL.²⁴ Also, Bhat et al found greater percentage of women underwent modified radical mastectomy (MRM) complained of difficulty in completing their house work, 25% reported feeling of being incomplete as women and had a lack of femininity with significant differences in QoL in comparison to women had BCS in terms of physical function and body image.²⁵

Furthermore, Wu et al reported that body image is predictive of the QoL of BC patients and dynamic changes of body image and QoL may be useful for decision-making regarding surgery in BC patients.²⁶

Also, Deepa et al found QOL scores in all women had MRM or BCS were improved after treatment and surpassed the baseline in physical, emotional and breast-specific domains, but with non-significant difference between the MRM and BCS groups in any of these domain scores (27); thus Deepa et al could not find an effect of the extensivity of surgical procedure on QoL and this could be attributed to their study sample that included women with mean age of 53 (SD \pm 9) years and this result is contradictory to that reported in literature.

In support of this attribution, Rosenberg et al. found young BC survivors who underwent more extensive surgery have worse body image, sexual health, and anxiety compared with women undergoing less extensive surgery, indicating that young women must be aware of both short and long-term effects of surgery and receive support when making surgical decisions.²⁸

Limitations

The study was limited to cases fulfilling the inclusion criteria that allowed only inclusion of patients had mass <50 mm in its greatest diameter and this prolonged the duration of the study and decreased number of cases.

CONCLUSION

The applied procedure of localized excision of BC mass of <50 mm with immediate breast reconstruction using the remnant breast fibrofatty flaps provided acceptable surgical and esthetical outcomes and allowed improvement of patients' QoL with special regard to body image and future perspectives. However, wider multicenter comparative studies are mandatory to establish these results.

Funding: No funding sources

Conflict of interest: None declared

Ethical approval: The study was approved by the Institutional Ethics Committee

REFERENCES

1. Xuan S, de Barros A, Nunes R, Ricci-Junior E, da Silva A, Sahid M, et al. Radioactive gold nanocluster (198-AuNCs) showed inhibitory effects on cancer cells lines. *Artif Cells Nanomed Biotechnol.* 2020;48(1):1214-21.
2. De Lorenzi F, Hubner G, Rotmensz N, Bagnardi V, Loschi P, Maisonneuve P, et al. Oncological results of oncoplastic breast-conserving surgery: Long term follow-up of a large series at a single institution: A matched-cohort analysis. *Eur J Surg Oncol.* 2016;42(1):71-7.
3. Lombardi A, Maggi S, Stanzani G, Vitale V, Bersigotti L, Romano C, et al. Oncological outcomes in oncoplastic breast surgery: a single institution analysis. *G Chir.* 2019;40(5):417-20.
4. Yan M, Bustos S, Kuruoglu D, Forte A, Manrique O: Oncological safety of lipofilling after breast conserving surgery. *Gland Surg.* 2020;9(3):620-1.
5. Rehnke R, Schusterman 2nd M, Clarke J, Price B, Waheed U, Debski R, et al. Breast Reconstruction Using a Three-Dimensional Absorbable Mesh Scaffold and Autologous Fat Grafting: A Composite Strategy Based on Tissue-Engineering Principles. *Plast Reconstr Surg.* 2020;146(4):409e-13e.
6. McCamley C, Mills C, Chow Y, Ross D, Fox J Determinants influencing immediate breast reconstruction in an Australian tertiary public hospital. *ANZ J Surg.* 2020.
7. Patel N, Ramakrishnan V. Microsurgical Tissue Transfer in Breast Reconstruction. *Clin Plast Surg.* 2020;47(4):595-609.
8. Agrawal A, Garreffa E "Medial Hemi-Mastopexy": An Innovation to Avoid Medial Pole Emptiness in Reduction Mammoplasty. *Ann Plast Surg.* 2020; 85(4):363-8.
9. Piat J, Tomazzoni G, Giovinazzo V, Dubost V, Maiato A, Ho Quoc C. Lipofilled Mini Dorsi Flap: An Efficient Less Invasive Concept for Immediate Breast Reconstruction. *Ann Plast Surg.* 2020; 85(4):369-75.
10. National Comprehensive Cancer Network. (NCCN) NCCN Clinical Practice Guidelines in Oncology: Breast Cancer. Fort Washington PA: NCCN; 2015
11. Dilhuydy MH. Breast imaging reporting and data system (BI-RADS) or French "classification ACR" What tool for what use? A point of view. *Eur J Radiol.* 2007;61(2):187-91.
12. Ware JE Jr. The SF-36 health survey. In *Quality of Life and Pharmacoeconomics in Clinical Trials* Second edition. Edited by: Spilker B. Philadelphia PA: Lippincott-Raven Press. 1996:337-45.
13. Cash TF, Pruzinsky T. *Body images: Development, deviance, and change.* New York: The Guilford Press; 1990.
14. Snyder C, Blackford A, Okuyama T, Akechi T, Yamashita H, Toyama T, et al. Using the EORTC-QLQ-C30 in clinical practice for patient management: identifying scores requiring a clinician's attention. *Qual Life Res.* 2013; 22(10):2685-91.
15. Yamamoto M, Yano T, Shimizu D, Yokoyama A, Ito O. L-positioned Perforator Propeller Flap for Partial Breast Reconstruction with Axillary Dead Space. *Plast Reconstr Surg Glob Open.* 2016;4(6):e762.
16. Słowik A, Jabłoński M, Michałowska-Kaczmarczyk A, Jach R. Evaluation of quality of life in women with breast cancer, with particular emphasis on sexual satisfaction, future perspectives and body image, depending on the method of surgery. *Psychiatr Pol.* 2017;51(5):871-88.
17. Biazus J, Stumpf C, Melo M, Zucatto A, Cericatto R, Cavalheiro J, et al. Breast-Conserving Surgery with Immediate Autologous Fat Grafting Reconstruction: Oncologic Outcomes. *Aesthetic Plast Surg.* 2018;42(5):1195-201.
18. Bachleitner K, Weitgasser L, Amr A, Schoeller T. Autologous Unilateral Breast Reconstruction with Venous Supercharged IMAP-Flaps: A Step by Step Guide of the Split Breast Technique. *J Clin Med.* 2020;9(9):3030.
19. Dorogi B, Mátrai T, Újhelyi M, Kenessey I, Kelemen P, Sávolt A, et al. Assessing the needs of Hungarian breast cancer patients for modern oncoplastic breast surgical treatment. [Questionnaire study of 500 patients]. *Orv Hetil.* 2020; 161(29):1221-8.
20. Kosasih S, Tayeh S, Mokbel F, Kasem A. Is oncoplastic breast conserving surgery oncologically safe? A meta-analysis of 18,103 patients. *Am J Surg.* 2020;220(2):385-92.
21. Borm K, Schönknecht C, Nestler A, Oechsner M, Waschulzik B, Combs S, et al. Outcomes of immediate oncoplastic surgery and adjuvant radiotherapy in breast cancer patients. *Brit Med Cent Canc.* 2019;19(1):907.
22. Pearce B, Fiddes R, Paramanathan N, Chand N, Laws S, Rainsbury R. Extreme oncoplastic conservation is a safe new alternative to mastectomy. *Eur J Surg Oncol.* 2020;46(1):71-6.
23. Niinikoski L, Leidenius M, Vaara P, Voynov A, Heikkilä P, Mattson J, et al. Resection margins and local recurrences in breast cancer: Comparison between conventional and oncoplastic breast conserving surgery. *Eur J Surg Oncol.* 2019; 45(6):976-82.
24. Türk K, Yılmaz M. The Effect on Quality of Life and Body Image of Mastectomy among Breast Cancer Survivors. *Eur J Breast Health.* 2018; 14(4):205-10.
25. Bhat V, Roshini A, Ramesh R. Does Quality of Life Among Modified Radical Mastectomy and Breast Conservation Surgery Patients Differ? A 5-Year Comparative Study. *Ind J Surg Oncol.* 2019; 10(4):643-8.
26. Wu T, Chang T, Chang S, Lin Y, Wang J, Kuo Y. Dynamic Changes Of Body Image And Quality Of

Life In Breast Cancer Patients. *Cancer Manag Res.* 2019;11:10563-71.

27. Deepa K, Gadgil A, Löfgren J, Mehare S, Bhandarkar P, Roy N. Is quality of life after mastectomy comparable to that after breast conservation surgery? A 5-year follow up study from Mumbai, India. *Qual Life Res.* 2020;29(3):683-92.
28. Rosenberg S, Dominici L, Gelber S, Poorvu P, Ruddy K, Wong J, et al. Association of Breast

Cancer Surgery with Quality of Life and Psychosocial Well-being in Young Breast Cancer Survivors. *J Am Medic Assoc Surg.* 2020;e203325.

Cite this article as: Shoda WA, Wahab SMA. Autologous breast fibrofatty flaps for immediate breast reconstruction after excision of small cancer mass (<50 mm) improves surgical and aesthetical outcomes and patients' quality of life. *Int Surg J* 2020;7:3894-901.