

Original Research Article

Laparoscopic subtotal cholecystectomy a boon to difficult gall bladder

Santosh Kumar Singh, Devendra Shukla, Pradeep Kumar Singh, Ila Katyayan*

Department of General Surgery, M.L.N. Medical College, Prayagraj, Uttar Pradesh, India

Received: 13 October 2020

Revised: 21 November 2020

Accepted: 01 December 2020

***Correspondence:**

Dr. Ila Katyayan,

E-mail: i.katyayan@gmail.com

Copyright: © the author(s), publisher and licensee Medip Academy. This is an open-access article distributed under the terms of the Creative Commons Attribution Non-Commercial License, which permits unrestricted non-commercial use, distribution, and reproduction in any medium, provided the original work is properly cited.

ABSTRACT

Background: Subtotal laparoscopic cholecystectomy has been in practice to treat difficult gall bladder for 100s of years. It keeps the benefit of being a minimally invasive and single-stage procedure. Thus, it remains a better option over conversion to open cholecystectomy as well as cholecystostomy which was a two-stage surgery practiced in earlier days.

Methods: It was a prospective study focusing on indications, type and complications of subtotal laparoscopic cholecystectomy. It also compared the per-operative and post-operative outcomes of all cases of subtotal laparoscopic cholecystectomy (48) with cases of laparoscopic cholecystectomy that were converted to open procedure (30) performed over a period of 1 year. Patients were followed for 12 months post-surgery.

Results: Acute cholecystitis is one of the most common indication of subtotal cholecystectomy. Also, it was associated with lesser mean operative time, postoperative hospital stays and postoperative complications when compared with conversion (to open) cholecystectomy.

Conclusions: Subtotal cholecystectomy is a better option than open cholecystectomy in cases of difficult gall bladder.

Keywords: Acute cholecystitis, Cholecystostomy, Conversion cholecystectomy, Difficult gall bladder, Subtotal laparoscopic cholecystectomy

INTRODUCTION

Laparoscopic cholecystectomy has been the gold standard for the treatment of benign gallbladder disease. It is an effective procedure with a very low mortality and morbidity.¹⁻⁴ It is even practiced at some centres as a day care procedure. However, the procedure turns out to be difficult in the presence of severe inflammation such as acute or chronic cholecystitis, empyema, gangrene, perforation, Mirizzi syndrome and also in cases of liver cirrhosis with portal hypertension. Inability to achieve the critical view of safety in these cases increases the risk of bile duct injury which is one of the most dreaded complication of laparoscopic cholecystectomy. Here comes the role of subtotal cholecystectomy which not only reduces the risk of complications encountered while dealing with a difficult gall bladder but also deters the surgeon from converting the laparoscopic procedure to

open. Subtotal cholecystectomy was first reported by Madding in 1955.⁵ Strasberg et al mentioned about different techniques of subtotal laparoscopic cholecystectomy procedures, two of those being fenestrating and reconstituting types.⁶

Our study focuses on the indications, type and complications associated with laparoscopic subtotal cholecystectomies performed in our institution over a period of 1 year. We also compared the outcomes of subtotal cholecystectomy with conversion cholecystectomy performed over same period of time.

METHODS

The study was conducted in a tertiary care hospital of North India over a period of 1 year from June 2018 to July 2019. After a careful history and clinical

examination, an ultrasonography of the abdomen was performed in all the patients to confirm the diagnosis of a calculus gall bladder disease.

Inclusion criteria

It included all the patients in the study period who were admitted for simple laparoscopic cholecystectomy for benign biliary disease in whom the total laparoscopic cholecystectomy could not be performed based on intraoperative findings, in the age group of 20-65 years with the Karnofsky performance status of more than 70.

They were randomized in to two groups. But the randomization was unequal based on surgeon's preference and consent of the patient's attendants. One group underwent subtotal cholecystectomy (fenestration or reconstituting type) and the other group underwent conversion to open cholecystectomy. All the patients included in the study were followed for a period of 12 months.

Exclusion criteria

The patients who did not give consent or were lost to follow up were excluded from the study.

The outcome of the two groups were compared in terms of mean operation time, length of hospital stay and early and late postoperative complications including Clavien Dindo classification system. Student's t-test was applied as statistical test of significance.

Surgical procedure

Laparoscopic cholecystectomies were performed using a standard 4-port technique. Patient was laid in supine position. Pneumoperitoneum was created using veress needle, a blunt trocar or Hassan's technique. 4 ports were placed, a 10 mm umbilical port for camera, 10 mm epigastric port as the main right working port, 5 mm port in right hypochondrium along mid-clavicular line for left working instrument and 5 mm port along anterior axillary line for fundal retraction to be used by the assistant. A 10 mm 30-degree telescope was used. Gall bladder was retracted cranially towards the right shoulder. Calot's triangle was identified. Peritoneum over the anterior and posterior aspect of gall bladder was dissected and infundibulum separated off the gall bladder bed. The critical view of safety was achieved following which the cystic duct and artery were ligated using ligation clips. The gall bladder was dissected off the liver bed and removed using epigastric port. However, in cases of extensive inflammation or fibrosis, the dissection of the Calot's triangle was not possible and critical view of safety could not be achieved. In such cases subtotal cholecystectomy was performed wherein the gall bladder was opened at the fundus and the contents were evacuated. The anterior wall of the gall bladder was excised downwards towards the cystic duct, the cystic

duct was closed from inside and the posterior wall was left behind over the liver bed or porta hepatis. In reconstituting cholecystectomy, we closed the lower end of gall bladder using ligation clip which was left open in fenestrating cholecystectomy. Haemostasis was achieved and mucosa of the remaining wall was obliterated using electro cautery. The sub hepatic drain placement was done at the end of the procedure in all the cases. Cases were followed for a period of one year following procedure.

RESULTS

1020 laparoscopic cholecystectomies were planned in the Department of Surgery, M.L.N. Medical College and associated S.R.N. Hospital, Prayagraj. Out of which 51 cases (5% of total cases) underwent subtotal laparoscopic cholecystectomy based upon intraoperative findings while conversion to open cholecystectomy was performed in 30 cases. There was loss of attrition of 3 cases of subtotal cholecystectomy giving a sample size of 48 out of which 36 were females and 12 were males with a mean age of 38 years. Out of 30 patients who underwent conversion cholecystectomy 22 were females and 8 were males, all in the age group ranging from 24 to 62 years with a mean age of 44 years.

Table 1: Sex distribution.

| Sex | Subtotal lap cholecystectomy | Conversion cholecystectomy |
|--------------|------------------------------|----------------------------|
| Male | 12 | 8 |
| Female | 36 | 22 |
| Total | 48 | 30 |

Table 2: Surgical details of subtotal laparoscopic cholecystectomy.

| | Subtotal cholecystectomy | Conversion cholecystectomy |
|--|--------------------------|----------------------------|
| Indications | | |
| Acute cholecystitis | 28 | 14 |
| Empyema gall bladder | 12 | 3 |
| Mirizzi syndrome | 4 | 2 |
| Liver cirrhosis | 4 | 1 |
| Type of procedure | | |
| Fenestrating | 38 | - |
| Reconstituting | 10 | - |
| Complications (based on Clavien Dindo classification) | | |
| Grade I | 8 | 6 |
| Grade II | 1 | 4 |
| Grade IIIA | 1 | 1 |
| Grade IIIB | 1 | 2 |
| Grade IVA | 1 | 0 |
| Grade IVB | 0 | 0 |
| Grade V | 0 | 0 |
| Total (n) | 48 | 30 |

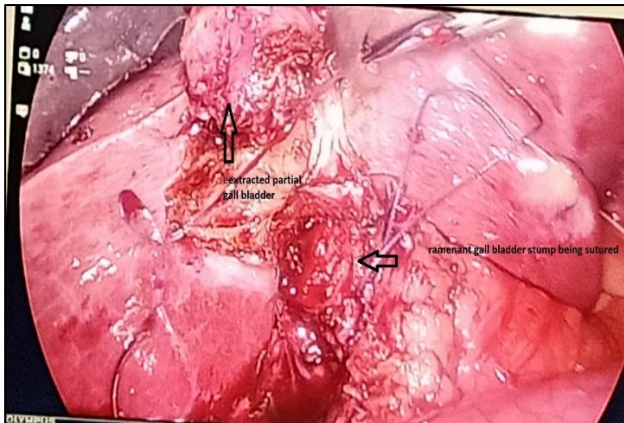


Figure 1: Laparoscopic cholecystectomy.

Amongst the cases undergoing subtotal laparoscopic cholecystectomy, fenestrating type of procedure was performed in 38 cases while reconstituting type in 10 cases.

Indications of subtotal cholecystectomies were acute cholecystitis in 28 cases, empyema gall bladder in 12

cases, liver cirrhosis with possibility of portal hypertension in 4 cases and Mirizzi syndrome in 4 cases.

Amongst the patients undergoing conversion cholecystectomy, there were 14 cases of acute cholecystitis, 3 cases of empyema gall bladder, 2 cases of Mirizzi syndrome and 1 case of liver cirrhosis. The reason for conversion to subtotal laparoscopic or open cholecystectomy included extensive adhesions and bleeding due to hypervascularity which obscured the delineation of anatomy of Calot's triangle. Additionally, choledochoplasty was performed in two cases of Mirizzi syndrome.

On comparing the subtotal lap and conversion cholecystectomy, mean operative time was more in conversion cholecystectomy (130.7 minutes). Subtotal cholecystectomy had mean operative time of only 80.10 minutes. This difference in mean operative time was statistically significant with a p value of <0.00001. On comparing the postoperative outcomes of the two groups, the length of hospital stay was significantly more in patients with conversion cholecystectomy with $p < 0.00001$.

Table 3: Postoperative complications of subtotal laparoscopic cholecystectomy.

| | Fenestrating subtotal | Reconstituting subtotal | Conversion cholecystectomy |
|---------------------------------|-----------------------|-------------------------|----------------------------|
| Postoperative hemorrhage | - | - | - |
| Subhepatic collection | 3 | 2 | 7 |
| Biliary fistula | 4 | - | - |
| Major bile duct injury | - | - | 2 |
| Surgical site infection | - | 1 | 4 |
| Recurrent biliary colic | - | 1 | 1 |

Table 4: Comparison of per-operative and post-operative outcomes of subtotal cholecystectomy and conversion cholecystectomy.

| | Subtotal Lap cholecystectomy | Conversion cholecystectomy | P value |
|--|------------------------------|----------------------------|----------|
| Mean operative time (minutes) | 80.10 | 130.7 | <0.00001 |
| Mean length of stay (days) | 3.9 | 7.1 | <0.00001 |
| Post-operative complications (%) | 22.92 | 43.33 | 0.078 |
| Post op complications requiring non-surgical intervention (%) | 20.83 | 36.66 | 0.55 |
| Post op complications requiring reoperation (%) | 2.08 | 6.67 | 0.63 |

Post-operative complications were more in patients with conversion cholecystectomy (43.33%) when compared to subtotal lap cholecystectomy (22.92%). However, the results were not statistically significant. The postoperative complications that occurred were sub hepatic collection, biliary fistula, port site infection and recurrent biliary colic. The complications were graded based on Clavien Dindo classification. The most common post-operative complication of subtotal cholecystectomy was sub hepatic collection seen in 5 patients which

resolved spontaneously over a period of 8-10 days (Grade I). 4 cases of biliary fistula were seen following a fenestrating type of procedure. It spontaneously resolved in 3 cases while an ERCP with sphincterotomy was required in 1 case (Grade IIIA). There was 1 case of port site infection which resolved on prolonged antibiotic coverage (Grade II). 1 patient had recurrent biliary colic 6 months following surgery. On investigation, GB sludge in the gall bladder remnant was found to be the cause of recurrent biliary colic and the patient had to undergo

completion cholecystectomy (Grade IIIB). 1 patient of subtotal cholecystectomy developed acute pulmonary edema in the immediate postoperative period and was kept in ICU on ventilatory support but the patient recovered well.

Sub hepatic collection was the most common complication of conversion cholecystectomy as well, seen in 7 cases. It resolved spontaneously in 6 patients but 1 patient developed sub hepatic abscess for which ultrasound guided percutaneous drainage was performed (Grade IIIA). It was followed by surgical site infections seen in 4 patients. They recovered with appropriate antibiotic coverage (Grade II). 2 patients of conversion cholecystectomy had major bile duct injury and were reoperated for the same (IIIB). No post-procedural mortality was recorded in both the groups.

DISCUSSION

Subtotal cholecystectomy was first reported by Madding in 1955 as a replacement for cholecystostomy in cases of technically difficult total cholecystectomy.⁵ After which, the subtotal cholecystectomy has been widely accepted as an easy, safe and definitive procedure in cholelithiasis patients with difficult gall bladder where critical view of safety is difficult to achieve. Many surgeons in such cases prefer conversion to open cholecystectomy as it ensures direct visualization of structures in Calot's triangle. However, conversion cholecystectomy not always offers better outcomes.⁷⁻⁹ Also, subtotal cholecystectomy provides the benefit of maintaining the procedure to be minimally invasive and single step.

In this study, the postoperative outcomes of subtotal lap cholecystectomy were compared with conversion cholecystectomy and were better in terms of duration of surgery, length of hospital stay and post-operative complications. These results were similar to those in a meta-analysis performed by Elschaer et al, which showed better outcomes of subtotal cholecystectomy over open cholecystectomy in terms of wound infection, sub hepatic collection, reoperation and mortality.⁷

Two subtotal cholecystectomy types performed in this study were reconstituting subtotal cholecystectomy and fenestrating cholecystectomy. Reconstituting type was commonly associated with the remnant gall bladder disease which required a completion cholecystectomy very often.¹⁰ Bodvall and Overgraad first reported the complications related to remnant gall bladder following cholecystectomy.¹¹ In this study, one case of reconstituting subtotal cholecystectomy developed remnant gall bladder disease requiring a completion cholecystectomy.

5-10% of patients undergoing cholecystectomy continue to experience symptoms of biliary disease, a condition best termed as post cholecystectomy syndrome.¹² The risk is higher in those undergoing subtotal

cholecystectomies. The cause being remnant gall bladder and non-visualization of cystic duct leading to retained calculi in Hartmann's pouch or slippage of stones or biliary sludge into the cystic duct.

Biliary fistula is the other common complication seen in patients of subtotal cholecystectomy, particularly, fenestrating type.

The largest series of laparoscopic subtotal cholecystectomy was reported by Palanivelu, which involved 206 patients presenting with liver cirrhosis and cholelithiasis wherein no case of postoperative hemorrhage was seen, which is a very common in this subgroup of patients.¹³ Another case series was reported by Bickel and Shtamler of subtotal cholecystectomy in 6 patients who recovered with good outcomes.¹⁴ Henneman and colleagues also gave systematic reviews mentioning about the excellent outcomes of subtotal cholecystectomy.¹⁵

This study has some limitations. The procedure was performed by different operating surgeons in different patients. Thus, difference in surgeon's individual efficacy and intraoperative decision making was the major limitation on this study. Also the patients were unequally randomized because of lack of preference for an open procedure by the patient and their relatives.

CONCLUSION

Subtotal laparoscopic cholecystectomy is an efficient means of dealing with a difficult gall bladder encountered during laparoscopic cholecystectomy. It prevents the conversion to open procedure, which is associated with more postoperative complications and longer hospital stay, and thus, maintaining the advantage of minimally excess surgery. It is also an efficient alternative to cholecystostomy which was practiced earlier and was a 2-stage surgical procedure. It has reduced the risk of postoperative hemorrhage in a very susceptible group of patients (liver cirrhosis and portal hypertension). However, the complications associated with this procedure include biliary fistula and remnant gall bladder disease. Remnant gall bladder disease is a rare complication mainly seen with reconstituting type of subtotal cholecystectomy which occasionally requires a completion cholecystectomy.

Funding: No funding sources

Conflict of interest: None declared

Ethical approval: The study was approved by the Institutional Ethics Committee

REFERENCES

1. Behari A, Kapoor VK. Asymptomatic Gallstones (AsGS) to treat or not to? Indian J Surg. 2012;74:4-12.

2. Shea JA, Healey MJ, Berlin JA, Clarke JR, Malet PF, Staroscik RN, et al. Mortality and complications associated with laparoscopic cholecystectomy. A meta-analysis. *Ann Surg.* 1996;224:609-20.
3. Antoniou S, Antoniou G, Koch O, Pointner R, Grandrath F. Meta-analysis of laparoscopic versus open cholecystectomy in elderly patients. *World J Gastroenterol.* 2014;20:609-20.
4. Keus F, de Jong K, Gooszen HG, Laarhoven C. Laparoscopic versus open cholecystectomy for patients with symptomatic cholelithiasis. *Cochrane Database Syst Rev.* 2006;18:CD006231.
5. Madding GF. Subtotal cholecystectomy in acute cholecystitis. *Am J Surg.* 1955;89:604-7.
6. Strasberg SM, Pucci MJ, Brunt LM, Deziel DJ. Subtotal cholecystectomy-“fenestrating” versus “reconstituting” subtypes and the prevention of bile duct injury: definition of the optimal procedure in difficult operative conditions. *J Am Coll Surg.* 2016;222(1):89-96.
7. Elshaer M, Gravante G, Thomas K, Sorge R, Al-Hamali S, Ebdewi H. Subtotal cholecystectomy for difficult gallbladders: systematic review and meta-analysis. *JAMA Surg.* 2015;150(2):159-68.
8. Henneman D, da Costa DW, Vrouwenraets BC, van Wagenveld BA, Lagarde SM. Laparoscopic partial cholecystectomy for the difficult gallbladder: a systematic review. *Surg Endosc.* 2013;27(2):351-8.
9. Tian Y, Wu SD, Su Y, Kong J, Yu H, Fan Y. Laparoscopic subtotal cholecystectomy as an alternative procedure designed to prevent bile duct injury: experience of a hospital in northern China. *Surg Today.* 2009;39(6):510-3.
10. Elshaer M, Gravante G, Thomas K, Sorge R, Al-Hamali S, Ebdewi H. Subtotal cholecystectomy for difficult gallbladders: systematic review and meta-analysis. *JAMA Surg.* 2015;150(2):159-68.
11. Bodvall B, Overgaard B. Cystic duct remnant after cholecystectomy: incidence studied by cholegraphy in 500 cases, and significance in 103 reoperations. *Ann Surg.* 1966;163: 382-90.
12. Zhou PH, Liu FL, Yao LQ, Qin XY. Endoscopic diagnosis and treatment of post-cholecystectomy syndrome. *Hepatobil Pancreat Dis Int.* 2003;2(1):117-20.
13. Bickel A, Shtamler B. Laparoscopic subtotal cholecystectomy. *J Laparoendosc Surg.* 1993;3(4):365-7.
14. Palanivelu C, Rajan PS, Jani K, Shetty AR, Senthilkumar K, Senthilnathan P, et al. Laparoscopic cholecystectomy in cirrhotic patients: the role of subtotal cholecystectomy and its variants. *J Am Coll Surg.* 2006;203(2):145-51.
15. Henneman D, Da Costa DW, Vrouwenraets BC, van Wagenveld BA, Lagarde SM. Laparoscopic partial cholecystectomy for the difficult gallbladder: a systematic review. *Surg Endosc.* 2013;27(2):351-8.

Cite this article as: Singh SK, Shukla D, Singh PK, Katyayan I. Laparoscopic subtotal cholecystectomy a boon to difficult gall bladder. *Int Surg J* 2021;8:215-9.