

Original Research Article

Laparoscopic subtotal cholecystectomy in severe cholecystitis with unclear anatomy

Maged Rihan*

Department of General Surgery, Faculty of medicine, Cairo University, Egypt

Received: 12 October 2020

Accepted: 19 November 2020

***Correspondence:**

Dr. Maged Rihan,

E-mail: magedrihan@hotmail.com

Copyright: © the author(s), publisher and licensee Medip Academy. This is an open-access article distributed under the terms of the Creative Commons Attribution Non-Commercial License, which permits unrestricted non-commercial use, distribution, and reproduction in any medium, provided the original work is properly cited.

ABSTRACT

Background: Aim of the study was to determine the differences between laparoscopic cholecystectomy and laparoscopic subtotal cholecystectomy as regards bile duct injury and post-operative complications rates in patients with severe cholecystitis and obscure anatomy.

Methods: We retrospectively reviewed the charts and postoperative outcomes of 293 patients with severe cholecystitis who underwent either laparoscopic cholecystectomy or laparoscopic subtotal cholecystectomy between September 2011 and January 2020. Patients with intraoperative altered anatomy which led to difficult dissection were defined as having severe cholecystitis.

Results: There were 304 cholecystectomies done for patients with severe cholecystitis. Of those, 203 underwent laparoscopic cholecystectomy (LC group), 90 underwent laparoscopic subtotal cholecystectomy (LSC group). There was no significant difference in male to female ratio, age, cases performed on an elective or emergency basis, hospital length of stay or initial operative findings. There were 5 patients with detected intraoperative biliary injury in LC group only. Postoperative bile leaks were significantly higher in the LSC (11.1%) than in the LC group (3.9%). Postoperative collections which needed percutaneous aspiration were also significantly higher in the LSC group (18.9%) than in the LC group (7.4%). Reoperation for collection was required in 8 patients in LC group and in 5 patients in LSC group. The rates of retained common bile duct stones, port site hernia, wound infections, and total complications were not significantly different between the two groups (28.1% v. 45.6%).

Conclusions: Our study demonstrated that laparoscopic subtotal cholecystectomy is a safe procedure which reduces the risk of bile duct injury and is comparable to laparoscopic cholecystectomy in patients with severe cholecystitis with unclear anatomy.

Keywords: Severe cholecystitis, Laparoscopic cholecystectomy, Laparoscopic subtotal cholecystectomy

INTRODUCTION

Laparoscopic cholecystectomy (LC) era started in the late 1980s and was considered to be the gold standard treatment for patients suffering from gall bladder diseases.^{1,2} The outcome of laparoscopic cholecystectomy is essentially affected by the severity of inflammation, male sex, greater body mass index, and advancing of the patient's age.³ Conversion to open surgery is required in 5-

20% of patients to minimize the risk of biliary and vascular injury especially in the presence of dense adhesions or fibrosis at the hepatocystic triangle.³⁻⁶

Open procedure is associated with a higher postoperative morbidity rates of wound infection, postoperative pain, prolonged hospital stay and a slow recovery.⁷ The method of "Critical View of Safety" for identification of the cystic duct and cystic artery in LC requires three criteria:⁸

Clearing the hepatocystic triangle (formed by the cystic duct, the common hepatic duct, and lower edge of the liver) from fat and fibrous tissue, exposing the cystic plate by separation of the lower third of the gallbladder from the liver, and two structures only to be viewed entering the gallbladder.

In patients where the dissection of hepatocystic triangle cannot be done safely, laparoscopic subtotal cholecystectomy (LSC) is an applicable surgical option.⁹ Leaving a stump behind the cystic duct for long times may lead to stones formation, while very close dissection to the common bile duct or right hepatic artery in difficult cholecystectomies is threatening. Because a gall bladder remnant stones are easier to treat than biliary or vascular injury, it is believed that leaving a stump is a more wise decision. The consensus is to avoid excessive blind dissection in acute inflammatory conditions. Furthermore, it is believed that the LSC is a valuable option in difficult situations and gives the patients the chance to enjoy all the advantages of the minimal access surgery.¹⁰

In this study we present a single center experience with a positive results in LSC aiming to avoid open conversion for difficult severe cholecystitis cases and to support the hypothesis that subtotal cholecystectomy is safer than total cholecystectomy in presence of hazardous anatomy.

METHODS

This is a retrospective study to analyze the postoperative outcomes of 293 patients with severe cholecystitis who underwent either LC or LSC at Aljedaani Hospital (private hospital in Jeddah- Kingdom of Saudi Arabia) between September 2011 and January 2020. It included elective and emergency cholecystectomies. Demographic data of the patients, operative reports, hospital length of stay, operative and post-operative morbidities (intraoperative bile duct injuries, bile leaks, intraabdominal collections, retained common bile duct stones, port site hernia and wound infections) were collected either from the electronic medical record or from the paper sheets.

Informed consents were obtained from all patients before surgery, and preoperative routine laboratory and ultrasonography reports were collected. Computed tomography (CT), magnetic resonance cholangiopancreatography (MRCP), or endoscopic retrograde cholangiopancreatography (ERCP) were done when needed.

The decision to do LSC was taken on the basis of intraoperative findings when there was impression that approaching the hepatocystic triangle will be unsafe due to severe cholecystitis with distorted anatomy to avoid vascular or biliary injury. This was adopted by three of our general surgery consultants; however, most of the patients in this study were operated by one of them.

Patients who underwent laparoscopic or open cholecystectomies for early uncomplicated cholecystitis, and patients with cholecystectomy done during other abdominal operations (e.g., sleeve gastrectomies) were excluded from the ultimate study analysis.

Patients with intense acute or chronic cholecystitis (dense pericholecystic adhesions, perforated or gangrenous) were included. All operative details were reviewed to recognize the patients with difficult dissection of the hepatocystic triangle.

The postoperative follow up period varied according to the time between the operation and the time of data collection. The primary outcome was incidence of intraoperative biliary injuries. The secondary outcomes involved postoperative bile leak or later strictures with need to do ERCP and/or stenting, presence of retained common bile duct stones, port site hernias, wound infection, intraabdominal collections with need for percutaneous drainage or reoperation.

Operative approach

The patient is positioned in the reverse Trendelenburg position with left side tilting, and the surgeon stands on the left side of the table. Two 10-mm and two 5-mm laparoscopic ports are used in the common positions for LC. Induction of pneumoperitoneum and assessment of the whole abdominopelvic cavity followed by dissection of pericholecystic adhesions with omentum, duodenum, stomach, or colon to display the gall bladder. If the gall bladder was mobilized off of the liver allowing a safe access to the hepatocystic triangle, LC was carried out. In patients where the 'critical view of safety' cannot be obtained, LSC is carried out to avoid conversion. The decision to terminate unsafe dissection was taken early to avoid possible biliary injury. The fundus is opened transversely by diathermy with aspiration of bile or pus and evacuation of stones by collecting in a laparoscopic retrieval bag. Then splitting of the GB wall by diathermy into anterior and posterior walls. The two walls are dissected until the Hartmann's pouch and then transected. The view from inside of the gallbladder helps in confident dissection and reduces the risk of biliary injury. This is followed by doing intracorporeal stitches to close the gall bladder remnant. Sub-hepatic drain was inserted in all patients and ports sites were closed. Drains were removed within 24 to 48 hours in cases with minimal serosanguineous output, but were left for longer times in patients with bile leak until subsequent ERCP.

Statistical analysis

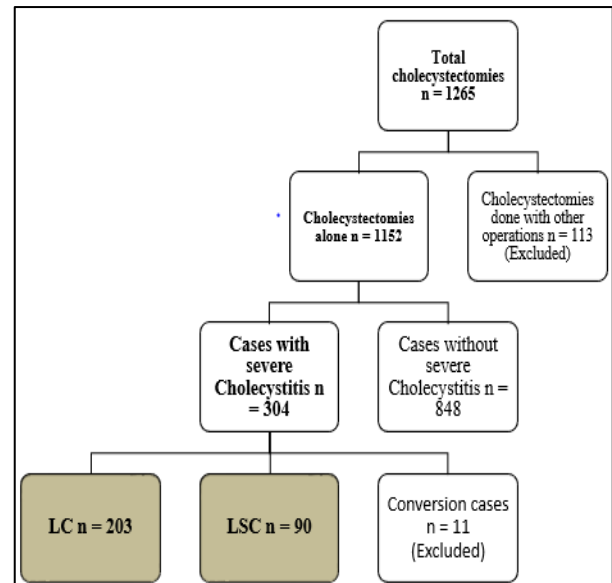
We applied chi-square tests to compare the data between the LC and the LSC groups. The continuous variables (age, hospital length of stay) were proved to be nonparametric by the Shapiro-Wilk test of normality and compared using a Wilcoxon rank-sum test.

Risk ratio was used for analysis of all operative and postoperative complications (intraoperative bile duct injuries, bile leaks, intraabdominal collections, retained common bile duct stones, port site hernia and wound infections). All statistics were analyzed in SPSS software.

RESULTS

There were 1265 cholecystectomies done between September 2011 and January 2020. Of these, 113 were done with other bariatric or hepatobiliary operations. Of the remaining 1152 patients, 848 without severe cholecystitis, and 304 with severe cholecystitis. Of those with severe cholecystitis, 203 underwent LC (LC group), 90 underwent LSC (LSC group), and 11 were converted to open cholecystectomy in the beginning of the laparoscopy setting without further tissue dissection and were excluded from the analysis. The comparisons were done between the LC group and the LSC group. The flow of patients' numbers is summarized in Figure 1. Demographic data for the LC and LSC groups are summarized in Table 1. There was no significant difference in male to female ratio, age, cases performed on an elective or emergency basis or hospital length of stay.

Also there was no significant difference between both groups regarding the initial operative findings. All patients had severe cholecystitis. There were 5 patients with detected intraoperative biliary injury in LC group. For those 5 patients, conversion to open exploration was done, repair of common bile duct injury with T tube insertion was done for 4 patients, and hepaticojejunostomy was done for one patient with almost total transection of the common hepatic duct. No intraoperative bile duct injuries were detected in the LSC group. As regards the postoperative complications, postoperative bile leak were significantly higher in the LSC (11.1%) than in the LC group (3.9%).



LC=laparoscopic cholecystectomy, LSC=laparoscopic subtotal cholecystectomy

Figure 1: Patients' numbers flow chart.

Postoperative collections which needed percutaneous aspiration were also significantly higher in the LSC group (18.9%) than in the LC group (7.4%). Reoperation for collection was required in 8 patients in LC group and in 5 patients in LSC group. The rates of retained common bile duct stones, port site hernia and wound infections were not significantly different between the two groups. There was no mortality within the two groups. Total complications rates were different between the LC and LSC groups (28.1% v. 45.6%).

The postoperative interventions were significantly different between the LC and LSC groups (21.2% v. 40%, RR 2.3). Operative and postoperative sequelae and interventions in both groups are summarized in Table 2.

Table 1: Demographic data and operative findings in patients with severe cholecystitis for LC and LSC groups.

Demographic data	LC group (n=203)		LSC group (n=90)		P value
	Number	Percentage	Number	Percentage	
Male sex	88	43.3	52	57.8	0.2
Elective cases	64	31.5	38	42.2	0.2
Median age	59.5- range (22-82) years		62 range- (31-85) years		0.3
Median length of stay	3 range (1-22) days		3 range (1-14) days		0.4
Operative findings					
Dense adhesions	52	25.6	29	32.2	0.6
Acute inflammation	28	13.8	19	21.1	0.3
Perforation	36	17.7	16	17.8	0.4
Gangrene	48	23.6	14	15.6	0.2
Contracted gall bladder	16	7.9	7	7.8	0.4
Empyema	9	4.4	5	5.6	0.5
Mirrizi’s syndrome	14	6.9	0		0.05

LC = laparoscopic cholecystectomy; LSC = laparoscopic subtotal cholecystectomy.

Table 2: Operative, postoperative sequelae and interventions in patients with severe cholecystitis for LC and LSC groups.

Postoperative sequelae	LC group (n=203)		LSC group (n=90)		RR
	Number	Percentage	Number	Percentage	
Biliary injury	5	2.5	0		0.5
Biliary leak	8	3.9	10	11.1	3.2
Biliary stricture	3	1.5	0		0.3
Common bile duct stones	9	4.4	4	4.4	0.7
Port site hernia	2	1	1	1.1	0.3
Wound infection	7	3.4	4	4.4	0.5
Percutaneous drainage for collection	15	7.4	17	18.9	2.6
Reoperation for collection	8	4	5	5.6	1.5
Total	57	28.1	41	45.6	1.4
Total postoperative interventions (ERCP, percutaneous drainage and reoperation)	43	21.2	36	40	2.3

LC = laparoscopic cholecystectomy; LSC = laparoscopic subtotal cholecystectomy; common bile duct=common bile duct; ERCP = endoscopic retrograde cholangiopancreatography; RR = risk ratio.

DISCUSSION

In the presence of distorted or unclear biliary anatomy, subtotal cholecystectomy with fundus first approach was well recognized as a safe procedure in the prelaparoscopic era.¹¹ Between 1985 and 2017, seventy-two research papers, sixty seven case series, three reviews, and two cohort studies were published about subtotal cholecystectomy indications, outcomes, and techniques.¹²

Currently, laparoscopic cholecystectomy may still be considered unsafe and risky by some surgeons who convert to an open procedure when facing such difficult cases.¹¹ However, the newer generations of surgeons may have no or limited experience with the open technique which would not certainly provide a more clear anatomical view, especially for a higher BMI patients.¹³

Most of the LSC patients (32.2%) in this study had dense adhesions at the hepatocystic triangle with obscure anatomy. In addition, 21.1% had acute inflammation, 17.8% had gall bladder perforation, 15.6% had gangrenous gall bladder, 7.8% had a contracted gall bladder and 5.6% had empyema of the gall bladder.

Several surgical techniques have been described for subtotal cholecystectomy.¹⁴ They include excision of the anterior wall only and leaving the posterior wall attached to the liver, excision of both walls and the gall bladder divided at Hartmann's pouch.¹⁵ Regardless of the technique, the gall bladder stump are either left open or closed by intracorporeal stitch, endoloop, or by stapling.¹⁶

The technique done for all patients of the LSC group in this study involved bisecting the gall bladder wall down to the closest safe area to the junction between the Hartmann's pouch and the cystic duct for safe transection of both anterior and posterior walls and then stump closure

by intracorporeal absorbable sutures with subhepatic drain insertion.

A common complication of the LSC procedure is post-operative bile leak. There is an acceptable higher bile leak rate, which matches with our study results, in the setting of LSC if compared with LC with risky severe cholecystitis as long as all of these patients eventually had favourable outcomes.¹⁷ It has been recorded in up to 16% of cases, either from the open stump or from the remnant posterior wall if left.^{15,18} We recommend routine closure of the remnant stump and excision of the whole remaining gall bladder walls as possible. We recorded an 11.1% incidence of bile leak in LSC group which is lower and favorable compared to the previously mentioned incidence. ERCP was done early for all patients with postoperative bile leak in our LSC group.

The incidence of bile duct injury in laparoscopic cholecystectomy is 0.6%.^{19,20} Tornqvist and colleagues observed a two fold increase in rate of biliary injury when comparing patients of severe cholecystitis with those with noninflamed gall bladder.²¹ A review of 15 retrospective studies and case series with 625 patients revealed only a single case of biliary injury in patients having LSC.¹⁴ We did not observe any biliary injuries in the LSC group or in patients who underwent LC for non severe cholecystitis. There were 5 patients with bile duct injuries (2.5%) in LC group. Similar tendency rates have been reported elsewhere.¹⁷

Other known complication recorded includes common bile duct stricture, with an overall reported incidence of 2-4%.¹⁴ Here, 3 patients (1.5%) in LC group had common bile duct strictures which were treated successfully by ERCP and stenting and no patient had developed this complication in LSC group. There is an attention related to LSC which is the formation of new stones or retained stones in the gall bladder remnant and slipping of stones to the common bile duct, with reported recurrent gall bladder

disease symptoms to occur in up to 5% of patients.^{14,15} In our study with a median follow-up period of 35 months (7-52 months), formation of new stones did not recorded, but there were nine patients (4.4%) had retained common bile duct stones in LC group and 4 patients (4.4%) in LSC group who were successfully treated by ERCP immediately after the operation.

Purzner et al reported that subphrenic collections after LSC were more common (21.7%) and percutaneous drains for postoperative intraabdominal collections were used in 15.2% of LSC patients versus 6.7% in the LC cohort.¹⁷ In another study, 1.5% of LSC patients were readmitted posoperatively because of intraabdominal collection.²² In this study, postoperative collections which needed percutaneous aspiration were also significantly higher in the LSC group (18.9%) than in the LC group (7.4%).

There was increase in bile leaks and intraabdominal collections rates in the LSC group, taking into consideration that these complications are more easy to treat if compared to the treatment of biliary ducts injury.

Open cholecystectomy has lost its popularity, and LSC when needed, becomes more convenient as comfort with laparoscopy has progressed in the current technical training models for most surgery residents.¹⁷ In this study, we attempted to provide a scope for the laparoscopic management in cases of severe cholecystitis and to support the use of LSC if achieving the “critical view of safety” would increase the risk of bile ducts injury.

Strength and weaknesses of this research

In this study, recognition of patients with severe cholecystitis as a discrete group which is more susceptible to complications than other patients with typical cholecystitis, is considered a point of strength. The limitations of this study are being a retrospective single center study, and the variability of follow-up periods according to how close is the time of data collection to the time of the operation.

CONCLUSION

In patients with severe cholecystitis and risky dissection of the hepatocystic triangle, laparoscopic subtotal cholecystectomy is a safe procedure which reduces the risk of bile duct injury and is comparable to laparoscopic cholecystectomy regarding other morbidities. It encourages the continuation of laparoscopy instead of conversion to open procedure with its associated disadvantages.

Funding: No funding sources

Conflict of interest: None declared

Ethical approval: The study was approved by the Institutional Ethics Committee

REFERENCES

1. Begos DG, Modlin IM. Laparoscopic cholecystectomy: From gimmick to gold standard. J Clin Gastroenterol. 1994;19:325-30.
2. Blum CA, Adams DB. Who did the first laparoscopic cholecystectomy? J Minim Access Surg. 2011;7:165-8.
3. Kanakala V, Borowski DW, Pellen MG, Dronamraju SS, Woodcock SA. Risk factors in laparoscopic cholecystectomy: a multivariate analysis. Int J Surg. 2011;9:318-23.
4. Comitalo JB. Laparoscopic cholecystectomy and newer techniques of gallbladder removal. JSLS. 2012;16:406-12.
5. Gurusamy KS, Davidson C, Gluud C, Davidson BR. Early versus delayed laparoscopic cholecystectomy for people with acute cholecystitis. Cochrane Database Syst Rev. 2013;6:CD005440.
6. Kama NA, Doganay M, Dolapci M, Reis E, Atli M, Kologlu M. Risk factors resulting in conversion of laparoscopic cholecystectomy to open surgery. Surg Endosc. 2001;15:965-8.
7. Bingener CJ, Richards ML, Strodel WE, Schwesinger WH, Sirinek KR. Reasons for conversion from laparoscopic to open cholecystectomy: a 10- year review. J Gastrointest Surg. 2002;6:800-5.
8. Strasberg SM, Brunt LM. Rationale and use of the critical view of safety in laparoscopic cholecystectomy. J Am Coll Surg. 2010;211:132-8.
9. Strasberg SM, Pucci MJ, Brunt LM. Subtotal cholecystectomy “fenestrating” vs “reconstructing” subtypes and the prevention of bile duct injury: definition of the optimal procedure in difficult operative conditions. J Am Coll Surg. 2016;222:89-96.
10. Palanivelu C, Rangarajan M, Jategaonkar PA, Madankumar MV. Laparoscopic management of remnant cystic duct calculi: a retrospective study. Ann R Coll Surg Engl. 2009;91:25-9.
11. Katsohis C, Prousalidis J, Tzardinoglou E, Michalopoulos A, Fahandidis E, Apostolidis S, et al. Subtotal cholecystectomy. HPB Surg. 1996;9:133-6.
12. Lunevicius R. Laparoscopic subtotal cholecystectomy: a classification, which encompasses the variants, technical modalities, and extent of resection of the gallbladder. Ann R Coll Surg Engl. 2020;102(4):315-7.
13. Wolf AS, Nijssen BA, Sokal SM, Chang Y, Berger DL. Surgical outcomes of open cholecystectomy in the laparoscopic era. Am J Surg. 2009;197:781-4.
14. Henneman D, Costa DW, Vrouwenraets BC, Wagensveld BA, Lagarde SM. Laparoscopic partial cholecystectomy for the difficult gallbladder: A systematic review. Surg Endosc. 2013;27:315-58.
15. Philips JA, Lawes DA, Cook AJ, Arulampalam TH, Zaborsky A, Menzies D, et al. The use of laparoscopic subtotal cholecystectomy for

- complicated cholelithiasis. *Surg Endosc.* 2008;22:1697-700.
16. Chowbey PK, Sharma A, Khullar R, Mann V, Baijal M, Vashistha A. Laparoscopic subtotal cholecystectomy: a review of 56 procedures. *J Laparoendosc Adv Surg Tech.* 2000;10:31-4.
 17. Purzner RH, Ho KB, Al-Sukhni E, Jayaraman S. Safe laparoscopic subtotal cholecystectomy in the face of severe inflammation in the cystohepatic triangle: a retrospective review and proposed management strategy for the difficult gallbladder. *Can J Surg.* 2019;62(6):402-11.
 18. Horiuchi A, Watanabe Y, Doi T, Sato K, Yukumi S, Yoshida M, et al. Delayed laparoscopic subtotal cholecystectomy in acute cholecystitis with severe fibrotic adhesions. *Surg Endosc.* 2008;22:2720-3.
 19. Deziel DJ, Millikan KW, Economou SG, Doolas A, Ko ST, Airan MC. Complications of laparoscopic cholecystectomy: a national survey of 4,292 hospitals and an analysis of 77,604 cases. *Am J Surg.* 1993;165:9-14.
 20. Strasberg SM. Error traps and vasculo-biliary injury in laparoscopic and open cholecystectomy. *J Hepatobiliary Pancreat Surg.* 2008;15:284-92.
 21. Tornqvist B, Waage A, Zheng Z. Severity of acute cholecystitis and risk of iatrogenic bile duct injury during cholecystectomy, a population- based case-control study. *World J Surg.* 2016;40:1060-7.
 22. Harilingam MR, Shrestha AK, Basu S. Laparoscopic modified subtotal cholecystectomy for difficult gall bladders: a single-centre experience. *J Minim Access Surg.* 2016;12(4):325-9.

Cite this article as: Rihan M. Laparoscopic subtotal cholecystectomy in severe cholecystitis with unclear anatomy. *Int Surg J* 2020;7:3929-34.