

Case Report

Inguinal hernia in females: do we know enough?

Ketan Vagholkar*, Madhavan Iyengar, Suvarna Vagholkar

Department of Surgery, D. Y. Patil University School of Medicine, Navi Mumbai, India

Received: 14 December 2015

Accepted: 02 January 2016

***Correspondence:**

Dr. Ketan Vagholkar,

E-mail: kvagholkar@yahoo.com

Copyright: © the author(s), publisher and licensee Medip Academy. This is an open-access article distributed under the terms of the Creative Commons Attribution Non-Commercial License, which permits unrestricted non-commercial use, distribution, and reproduction in any medium, provided the original work is properly cited.

ABSTRACT

Inguinal hernia in females is quite uncommon as compared to males. However in females it may pose both a diagnostic as well as a surgical challenge to the attending surgeon. Awareness of the anatomy of the region and all the possible contents is essential to prevent untoward complications. A case of an indirect inguinal hernia in a female is presented along with a review of literature to highlight the intricacies of the surgical anatomy and management.

Keywords: Inguinal hernia, Females

INTRODUCTION

Inguinal hernia continues to be the commonest hernia in women. Surgical management in women is similar to that in men. However a wide variety of presentations may add to the confusion in diagnosing inguinal hernia in females. Surgical repair of the hernia in women needs a proper understanding of the relationship of the reproductive organs to the hernia site.

A case of an indirect inguinal hernia in a 24 year old woman is presented along with a brief review of the surgical management.

CASE REPORT

A 24 year old female presented with a swelling in the left groin of 2 months duration. Patent was otherwise asymptomatic, but gave specific history of left groin swelling appearing on straining only. Patient did not have any precipitating factors for a hernia. She was nulliparous with no medical co-morbidities. Physical examination revealed a left inguinal hernia extending just proximal to the labia majora. The opposite groin was normal. Per-abdominal examination did not reveal any abnormality.

Patient underwent open inguinal hernioplasty. After the inguinal canal was opened, the sac was identified and dissected free from the round ligament up to the deep ring (Figure 1). The sac was opened and reduction of the omentum was ensured. A formal herniotomy was done. The redundant part of the sac was then excised. The round ligament was carefully preserved (Figure 2). As the posterior wall of the inguinal canal was attenuated and weak, a polypropylene mesh was placed over the posterior wall and fixed with polypropylene sutures. External oblique aponeurosis was closed with 2-0 vicryl and the skin approximated with staples. Postoperative recovery was uneventful. Skin staples were removed on the tenth postoperative day. Patient has been following up for more than six months with no recurrence.

DISCUSSION

A swelling which appears in the inguinal region on coughing confirms the diagnosis of an inguinal hernia. However in a few cases an inguinal hernia in a female patient can prove to be a very deceptive lesion. Endometriosis which is a common condition in urban population can develop in a hernia sac giving rise to a multitude of confusing symptoms.^{1,2} An endometriotic

lesion in the inguinal region can give a false feeling of a hernia recurrence in an already operated patient.³ Therefore careful assessment of specific symptoms with relation to the menstrual cycle can only help in preoperative diagnosis.

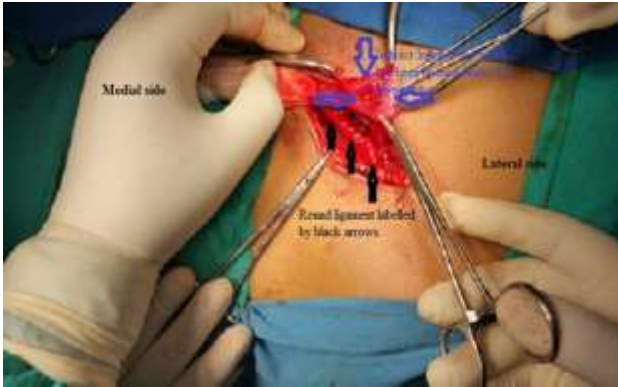


Figure 1: Intraoperative photograph of a dissected left inguinal hernia showing the indirect sac marked by blue arrows which has been opened and its relationship with the round ligament marked by black arrows.

Understanding the anatomy of the female inguinal canal is pivotal for a successful outcome of the surgical repair. The female inguinal canal structurally is similar to that in that in male with the exception of its contents. In females the round ligament replaces the cord. The round ligament is anatomically an important support of the uterus. Transections of the round ligament during repair can lead to anatomical weakening of the uterine support. However this anatomic concern continues to be a contentious issue with the gynaecologists in favour of preservation of the round ligament, whereas the surgeons in favour of its removal in order to ensure the complete obliteration of the inguinal canal in order to reduce the chances of recurrence.^{4,5}

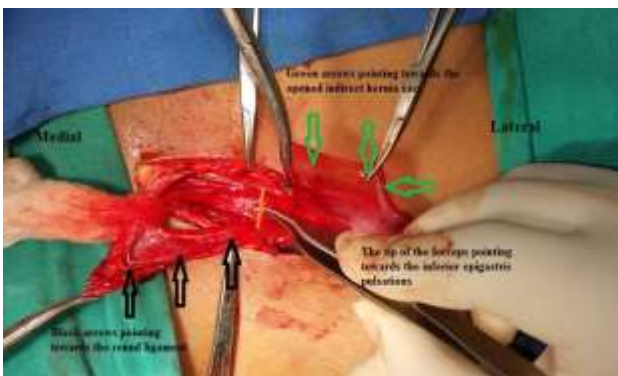


Figure 2: Round ligament marked by black arrows has been dissected free from the sac marked by green arrows up to the red vertical line pointed by the forceps which was the site of the inferior epigastric artery pulsations.

The anatomy of the round ligament in female infants and girls has been studied by Ando et al.⁵ Their results revealed that the round ligament as was traditional thought did not end in the labia majora but midway in the inguinal canal. Internally it was attached to the mid portion of the fallopian tube or the ovary which leads to the conclusion that the ligament that runs along the hernia sac is best described as the suspensory ligament of ovary.⁶

A wide range of contents can surprise the surgeon at the time of surgery. Sliding inguinal hernia containing the ovary is a complex lesion necessitating a careful and meticulous dissection with least trauma to the ovaries.⁷ A part of the uterus, fallopian tube and ovaries can also find its way in to the hernia sac.^{8,9} Therefore the hernia sac in a female patients in like a magic box the truth of which is unravelled only after exploration.

Irrespective of the anatomical nature of the ligament it is important for the surgeon to dissect the hernia sac from the round ligament as was done in the case presented (Figure 2). It is undoubtedly a good surgical practice to retain or maintain majority of the anatomical structures unless there are compelling reasons to do so. In case of a direct sac the question of damage to the round ligament does not arise. The choice of repair in female subjects also needs elaborate attention. Majority of female patients who present with an inguinal hernia are multiparous with thinned out and weakened lower abdominal wall tissues. Use of local tissues to strengthen the posterior wall may therefore not be worthwhile.¹⁰ It is therefore a safe practice to place a mesh over the posterior wall. Adequate precautions need to be taken to prevent migration of the mesh by fixing it with non-absorbable sutures. In female infants and girls some researchers have proposed to explore the contra lateral side to rule out a concomitant inguinal hernia. However this view has not met with great support.

Laparoscopic approach can also be used to treat these lesions. Laparoscopy can provide a very clear perspective of the contents of the hernia sac. But as the number of female inguinal hernias is much less as compared to the male population, studies substantiating a positive role of laparoscopy are still unavailable.

CONCLUSION

Awareness of female inguinal anatomy is essential before embarking on any surgical intervention for inguinal hernia.

The possibility of a sliding inguinal hernia with uterus, fallopian tube and ovaries should be considered.

The round ligament should be preserved as far as possible to prevent any weakening of uterine support.

Open surgical approach is undoubtedly a safe approach in such patients. However laparoscopic approach is also helpful especially in cases wherein the clinical diagnosis is ambiguous as in a scar endometriosis mimicking a recurrent hernia.

ACKNOWLEDGEMENTS

We would like to thank the Dean of D. Y. Patil University School of Medicine, Navi Mumbai, India for allowing us to publish this case report. We would also like to thank Parth K. Vagholkar for his help in typesetting the manuscript.

Funding: No funding sources

Conflict of interest: None declared

Ethical approval: Not required

REFERENCES

1. Sataloff DM, La Vorgia KA, McFarland MM. Extrapelvic endometriosis presenting as a hernia: clinical reports and review of the literature. *Surgery*. 1989;105(1):109-12.
2. Kamio M, Nagata T, Yamasaki H, Yoshinaga M, Douchi T. Inguinal hernia containing functioning rudimentary uterine horn and endometriosis. *Obstet Gynecol*. 2009;113(2 Pt 2):563-6.
3. Ducarme G, Uzan M, Poncelet C. Endometriosis mimicking hernia recurrence. *Hernia*. 2007;11(2):175-7.
4. Herrington JK. Occult inguinal hernia in the female. *Ann Surg*. 1975;181:481-3.
5. Ando H, Kaneko K, Ito F, Seo T, Ito T. Anatomy of the round ligament in female infants and children with an inguinal hernia. *Br J Surg*. 1997;84(3):404-5.
6. Mollaeian M, Mollaeian A, Ghavami Adel M, Abdullahi A, Torabi B. Preserving the continuity of round ligament along with hernia sac in indirect inguinal hernia repair in female children does not increase the recurrence rate of hernia. Experience with 217 cases. *Pediatr Surg Int*. 2012;28(4):363-6.
7. Fowler CL. Sliding indirect hernia containing both ovaries. *J Pediatr Surg*. 2005;40(9):e13-4.
8. Osifo OD, Ovuenu ME. Inguinal hernia in Nigerian female children: beware of ovary and fallopian tube as contents. *Hernia*. 2009;13(2):149-53.
9. Ozkan OV, Semerci E, Asian E, Ozkan S, Dolapcioglu K, Besirov E. A right sliding indirect inguinal hernia containing paraovarian cyst. Fallopian tube and ovary: a case report. *Arch Gynecol Obstet*. 2009;279(6):897-9.
10. Glasgow F. An evaluation of the strength of the posterior wall of the inguinal canal in women. *Br J Surg*. 1973;60:342-4.

Cite this article as: Vagholkar K, Iyengar M, Vagholkar S. Inguinal hernia in females: do we know enough? *Int Surg J* 2016;3:354-6.