

Case Report

Acute appendicitis in mobile caecum: a diagnostic dilemma: a case report

Naren Karthik K. C.*, Dhinesh Kumar N., Boopathi Subbarayan, Tirou Aroul T.

Department of General Surgery, Mahatma Gandhi Medical College and Research Institute, Pondicherry, India

Received: 29 September 2020

Accepted: 17 November 2020

*Correspondence:

Dr. Naren Karthik K. C.,

E-mail: narenkarthik1993@gmail.com

Copyright: © the author(s), publisher and licensee Medip Academy. This is an open-access article distributed under the terms of the Creative Commons Attribution Non-Commercial License, which permits unrestricted non-commercial use, distribution, and reproduction in any medium, provided the original work is properly cited.

ABSTRACT

Acute appendicitis is usually diagnosed on the basis of clinical history, physical examination and results of laboratory tests. The position of the appendix can vary considerably, both in relation to the caecum and because of the inconsistent position of the caecum itself. Acute appendicitis in a mobile caecum can pose a diagnostic dilemma which can lead to delay in appropriate treatment. In this case report, we present a 21 year old male with acute appendicitis and surgically proven to be acute appendicitis in a mobile caecum.

Keywords: Acute appendicitis, Mobile caecum, Atypical, Diagnostic dilemma

INTRODUCTION

Acute appendicitis is usually diagnosed on the basis of clinical history, physical examination and results of laboratory tests.¹ Acute appendicitis in the presence of a mobile caecum may present with atypical abdominal findings which can cause a diagnostic dilemma and delay in appropriate treatment which can lead to complicated appendicitis.² Abdominopelvic computed tomography (CT) examination can be helpful in establishing the diagnosis in atypical presentation of acute appendicitis with mobile caecum. The management of such cases may warrant laparoscopic appendectomy which can be diagnostic as well as therapeutic.

A mobile caecum is an uncommon congenital disorder, but may very rarely be a cause of acute abdomen in childhood. Abnormal mobility of caecum and ascending colon has been estimated to be found in 10-20% of population.⁴ Embryologically, posterior peritoneum covers only caecum and ascending colon in the retroperitoneal space.⁵ Mobile caecum is defined as an anomalous position of the right colon, caecum and terminal ileum due to failure of right colonic mesentery to fuse with posterior parietal peritoneum.⁶ This condition is mostly asymptomatic. It

can rarely present as an acute condition leading to caecal volvulus or can present as a chronic syndrome associated with symptoms of recurrent lower abdominal pain and constipation. When there are atypical clinical findings of acute appendicitis and ultrasonogram findings are not diagnostic, abdominopelvic CT helps to recognize the situation of the appendix and the caecum and can prevent misdiagnosis.⁵

CASE REPORT

A 21 year old male presented with complaints of abdominal pain of 24 hours duration. The pain was mild and initially located in the epigastric and suprapubic region, later progressed to diffuse type of pain. Patient also had vomiting and fever. Patient had similar complaints 7 years back and was managed conservatively. General examination revealed pulse 98 beats per minute (bpm), blood pressure (BP) 110/70 mmHg and temperature of 100°F. Physical examination of the abdomen revealed rebound tenderness in the right lower quadrant. His laboratory tests were normal except for elevated white blood cell count of 17,200 cells/mm³. Abdominopelvic CT examination with intravenous contrast was performed which demonstrated prominent appendix which was pelvic

in position with mild wall thickening and enhancement. The appendix measured 9.2 mm in diameter with few hyperdense foci within, likely representing appendicolith. He underwent an emergency laparoscopic appendectomy. The procedure revealed a mobile caecum and ascending colon with a mesentry and the appendix was inflamed and turgid lying in the pelvis.

Biopsy report revealed features of acute appendicitis.

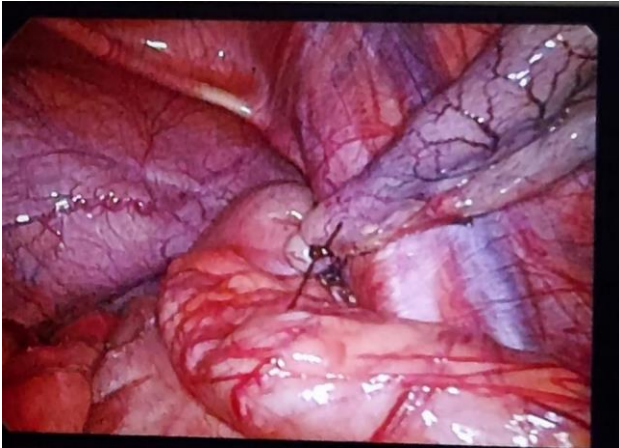


Figure 1: Appendix and mobile caecum in pelvic position.

DISCUSSION

Embryologically, caecum and ascending colon are usually attached to retroperitoneum by the posterior parietal peritoneum. Failure of the right colonic mesentery to fuse to the lateral peritoneum may lead to unattached caecum and ascending colon that causes it to be highly mobile. Embryogenesis of bowel is a complex process that begins during 5th gestational week and involves 3 phases: herniation, return to abdomen and fixation.⁷ Anomalies of rotation and fixation of the gastrointestinal tract are frequently associated with other embryological defects. The suspension of the caecum and ascending colon by a mesentery may allow them to rotate freely.

Intermittent bouts of abdominal pain occur as result of intermittent episodes of caecal obstruction which resolves immediately as caecum moves into normal position.⁴ It is usually found in patients diagnosed and operated for acute appendicitis. It can manifest as acute condition of caecal volvulus presenting with sudden onset abdominal pain, abdominal distension and vomiting which can lead to strangulation, gangrene that necessitates an emergency surgery.⁷ Mobile caecum syndrome can be misdiagnosed as functional colon disease since both can present with chronic constipation.⁸

The normal appendix is located posteromedial to the caecum, 3 cm from the ileocaecal valve. The normal appendix is mostly retrocaecal in position. In the presence of a mobile caecum, the clinical findings of acute

appendicitis may be atypical owing to the abnormal position of the appendix.³ Ultrasonogram (USG) abdomen has high sensitivity and specificity in diagnosing acute appendicitis but is least effective in cases of acute appendicitis in a mobile caecum. In USG, a mobile caecum can be misdiagnosed as meckel's diverticulum, duplication of mesenteric cyst, infected urachal cyst or sigmoid diverticulitis.⁵ Abdominopelvic CT is the investigation of choice for mobile caecum.⁸ Most common findings are redundant colon, deviation towards mid line, elongated and over rotated caecocolon in the left lower quadrant or lying transversely across the abdomen, crossing the mid line in the left upper quadrant.⁵ Toprak et al reported two cases of acute appendicitis in a mobile caecum in which they found that right hemicolon and caecum were located in left upper quadrant adjacent to splenic flexure and descending colon.⁵ Kaskin et al reported a case of acute appendicitis in a mobile caecum in which caecum and ascending colon were located in the epigastric region adjacent to left lobe of liver and gall bladder.⁵ In our patient, caecum and ascending colon with the mesentery were located in the pelvis along with the appendix and they were all mobile as a single unit.

Laparoscopic grading of mobile caecum syndrome

Gomes et al have graded mobile caecum syndrome from grade I to grade III, based on ileocaecal-appendiceal unit mobility, peritoneal attachment and ability to rotate on its own axis, on laparoscopy.⁸

Grade I is retroperitoneal or little mobility, do not reach the midline.

Grade II is wide mobility, crosses the midline, absence of the caecum and part of ascending colon, able to rotate on its own axis.

Grade III is maximal mobility, reach the left quadrant of the abdomen, complete absence of caecum and ascending colon, able to rotate on its own axis.

Based on the grading system proposed, our patient falls in grade II.

CONCLUSION

Acute appendicitis is diagnosed with classical symptoms and signs. But acute appendicitis in a mobile caecum may pose a diagnostic dilemma and delay in appropriate treatment. A high index of suspicion and abdominopelvic CT will be helpful in establishing the diagnosis in such atypical cases. It will always warrant a laparoscopic appendectomy as it will be diagnostic as well as therapeutic.

Funding: No funding sources

Conflict of interest: None declared

Ethical approval: Not required

REFERENCES

1. Toprak H, Bilgin M, Atay M, Kocakoc E. Diagnosis of Appendicitis in Patients with Abnormal Position of the Appendix due to Mobile Caecum. *Case Rep Surg.* 2012. Available at: <https://www.ncbi.nlm.nih.gov/pmc/articles/PMC3512262/>. Accessed on: 06 July 2020.
2. Yazawa K, Azuma Y, Kurokawa T, Yoshioka Y, Tsurita G, Shinozaki M. Abdominal CT-aided diagnosis of acute appendicitis in the presence of mobile cecum: A case report. *Int J Surg Case Rep.* 2018;42:258-60.
3. Jean JY, Tseng HH, Kao WS, Lee MC. An Unusual Presentation of Acute Appendicitis With Mobile Cecum Syndrome. *Pediatr Neonatol.* 2015;56.
4. Garude K, Rao S. Mobile cecum: an incidental finding. *Indian J Surg.* 2013;75(4):265-7.
5. Keskin S, Keskin Z, Gunduz M, Sekmenli T, Kivrak HY. Gangrenous Appendicitis in a Boy with Mobile Caecum. *Iranian J Radiol.* 2015. Available at: <https://sites.kowsarpub.com/iranradiol/articles/17938.html>. Accessed on: 29 June 2020.
6. Pardy C, Lewis J, Mahomed A. Laparoscopic Cecopexy for Mobile Cecum Syndrome as a Cause of Chronic Right Iliac Fossa Pain. *Videoscopy.* 2016;26(5).
7. Cesaretti M, Trotta M, Leale I, Minetti GA, Cittadini G, Montecucco F, et al. Surgery to Treat Symptomatic Mobile Cecum Syndrome Is Safe and Associated with Good Recovery Outcomes. *Case Rep Gastrointest Med.* 2018;4718406.
8. Gomes CA, Soares C Jr, Catena F, Di Saverio S, Sartelli M, Gomes CC, et al. Laparoscopic Management of Mobile Cecum. *JLS.* 2016;20(4).

Cite this article as: Naren KKC, Kumar DN, Subbarayan B, Aroul TT. Acute appendicitis in mobile ceacum-a diagnostic dilemma: a case report. *Int Surg J* 2020;7:4225-7.