

Original Research Article

A comparative study of the efficacy of nanocrystalline silver gel and silver sulfadiazine cream on the healing of second degree burn wound

Bikash Maiti, Sabyasachi Bakshi*

Department of General Surgery, BSMCH, West Bengal, India

Received: 27 September 2020

Revised: 07 November 2020

Accepted: 12 November 2020

***Correspondence:**

Dr. Sabyasachi Bakshi,

E-mail: dr.bakshi.s@gmail.com

Copyright: © the author(s), publisher and licensee Medip Academy. This is an open-access article distributed under the terms of the Creative Commons Attribution Non-Commercial License, which permits unrestricted non-commercial use, distribution, and reproduction in any medium, provided the original work is properly cited.

ABSTRACT

Background: The final aim of burn management is to prevent infection, to promote early epithelialization as well as healing of wound and betterment of functional and aesthetic after effects. The present study aimed to compare the effect of nano crystalline silver gel and silver sulfadiazine cream on the healing of second-degree burn wounds.

Methods: After matching the inclusion and exclusion criteria burn wounds of patients were divided into two parts (sides); one part was dressed with silver sulfadiazine cream and the other one was dressed with nano crystalline silver gel. The wound dressing was changed everyday after washing the wound with normal saline. Wound parameters were measured on the ninth day and twentieth day of dressing, using clinical assessment and photographic tool. The obtained data were statistically analyzed using the Chi-square test.

Results: In our study, most patients were noted to have increased epithelization, increased granulation tissue, decreased inflammation, decreased wound infection as well as decreased slough following dressing with both nanocrystalline silver gel and silver sulfadiazine cream but there were more in numbers of patients dressing with nanocrystalline silver gel.

Conclusions: The effect of nanocrystalline silver gel on the reduction of the healing time and necrotic tissue amount and increasing the granulation, epithelialization, and necrotic tissue type was greater. Considering the above findings nanocrystalline silver gel is more recommended to be used for burn wounds.

Keywords: Nanocrystalline silver, Silver sulfadiazine, Wound, Burn, Healing

INTRODUCTION

Burns is a global public health problem, accounting for an estimated 180,000 deaths annually. The majority of these occur in low and middle income countries and almost two-thirds occur in the African and Southeast Asia region. Over 10 lakh people are moderately or severely burnt every year in India.¹ In terms of damage grade, the burn is divided into four categories; the first-degree burn needs no special treatment, third-degree and fourth-

degree burn require auto graft, and second-degree burn takes two to three weeks to recover.²

The final aim of burn management and therapy is to minimize pain and thereby reducing the chance of anxiety and depression, to prevent infection, to promote early epithelialisation as well as healing of wound and betterment of functional and aesthetic after effects.³ The use of topical agent has been fundamental in that regard and has helped to improve the survival of patients with major burns and to minimize the incidence of burn

wound sepsis, a leading cause of mortality and morbidity in these patients.

Over the past 40 years, silver sulfadiazine (SSD) has become a very popular antimicrobial silver delivery system. All kinds of combinations of sulpha drugs with silver were tested *in vitro*, but SSD appeared to be the most effective and therefore used as a conventional dressing agent in burn wounds. However, development of bacterial resistance and impaired reepithelialisation has been described.⁴ Side effects of SSD are include argyria, hepatic, and renal toxicity, Bone marrow toxicity.⁵⁻⁸

These adverse effects demand a new therapy options for better burn wound management. Advances in the field of nanotechnology helped us to provide a new form of silver delivery system and have markedly improved the biologic value of silver. Nano silver particles have no local or systemic toxicity and do not impair healing. Smaller the particle size of silver, greater contact with wound surface area, thus increasing bioactivity and silver solubility. Silver in nanoscale affects the metabolism, respiration, and reproduction of microorganisms through connecting to the protein and the cell wall of microorganisms and influencing their phagocytosis process, which ultimately leads to the death of cells.^{9,10} Due to strong antibacterial activity, nanosilver is used for the treatment of wounds, including burn, because it can reduce the recovery time and relieve inflammation.¹¹⁻¹³

Adia et al. compared the effect of nanosilver and silver sulfadiazine on the burn wounds and observed that the wound healing time was shorter in nanosilver dressing.¹⁴

Therefore, the present study aims to compare the effect of dressing with nanocrystalline silver gel and silver sulfadiazine cream on the healing of second-degree burn wounds in patients hospitalized in Bankura Sammilani medical college and hospital in 2018 to 2019 in order to take an effective step towards the faster recovery of patients with burn wounds and reduction of their pain and suffering.

METHODS

This is an institution based (single centre) prospective, observational study. The study population comprised of subjects, satisfying the inclusion and exclusion criteria mentioned below. They were considered into the study at general surgery department of BSMCH, West Bengal, India for a time frame of about one and half years (from February 2018 to July 2019). After taking the informed consent from the participants; data were collected using the proforma. The primary data for this study were the investigation reports of the patients. The sample size (SS) for the proposed study will be calculated based on the formula;

$$SS = N = [(Z \alpha + Z \beta) \times (p_1 q_1 + p_2 q_2)] / d^2$$

where $Z_{\alpha}=1.96$ (two tailed) at 95% confidence interval (CI), $Z_{\beta}=0.84$ at 80% power of the test, p_1 and p_2 are the prevalence/incidence rates of event of interest (here it wound infection), q_1 and q_2 are the complements of p_1 and p_2 i.e. $(100-p_1)$ and $(100-p_2)$, d is the effect size i.e. minimum difference in the occurrence of event of interest to get a discernable clinical benefit. Here, $p_1=5.2\%$ (wound infection rate in silver nanocrystalline group) and $p_2=55$ (wound infection rate in silver sulfadiazine group).¹¹

Effect size was assumed to be 22, putting the values in the formula and considering 10% drop out, the final sample size for each group was 53.

Topical therapy was performed in 53 patients with second degree burn wounds, consisting of 53 pairs of side of the body, while 53 sides (study arm) will receive nanocrystalline silver gel and 53 sides (control arm) will receive silver sulfadiazine cream.

Inclusion criteria for the study were; patients of age greater than and equal to 18 years with 20% to 40% body surface burned, burns due to heat source or liquids (non acidic), an interval of less than 24 hours between the occurrence of burn and visiting hospital, burn patients involving on both sides of the body preferably either limbs, abdomen or chest, patients willing to participate in the study, second degree burns, BMI of the patient between 18.9 to 29.9 and haemoglobin amount of greater than 8 gm/dl and plasma albumin value of above 3 gm/dl

Exclusion criteria for the study were; patients with multi-organ failure or life-threatening sepsis, patients with severe co-morbidities, mentally unstable patients, patients with uncontrolled diabetes or end stage renal disease, infected burn wounds not well controlled on antibiotics, allergy to nano-silver or silver sulfadiazine.

Following variables were studied; total body surface area burnt, amount of 4077 pitheli after ninth day of dressing, pain during dressing changes, swab culture, distribution of infective organism, amount of slough, epithelization, granulation and inflammation, wound healing time, wound contracture and hypertrophic scar formation.

Study tools

A proper history was taken from each and every patient regarding the etiology of burn, the degree and nature of the burn wound and any subsequent management received. Photographs of the wound after cleaning properly with distilled water were taken prior to dressing with nanocrystalline silver and silver sulfadiazine. Photographs were repeated at 5 days and 9 days after beginning of dressing and at the completion of the study at 20 days and during follow up period.

Investigations

A complete blood count (CBC), serum sugar, urea, creatinine and serum electrolytes as well as serum albumin, total proteins were done in every patient prior to incorporation into the study. Surface swabs for culture and sensitivity were taken for culture in nutrient agar/MacConkey’s medium both at the beginning and at the end of the study from the burn wound.

Study procedure

Patients meeting the inclusion criteria were first chosen. One side of the wound was marked for dressing with nanocrystalline silver gel while other side was marked for dressing with silver sulfadiazine cream. The two sides harboring different dressing materials were isolated from one another so as to avoid any leaching effect from one portion the wound to another and confound the results. Nanocrystalline silver impregnated dressing and silver sulfadiazine impregnated dressing were changed every day. A proper wound assessment were made before instituting dressing with nanocrystalline silver gel and silver sulfadiazine cream. Wound assessments were made at 5 days and 9 days after beginning of dressing and at the completion of the study at 20 days and during follow up period. Infection in the burn wound was confirmed by surface swabs taken from the burn wound. The final results were assessed from both a clinical point of view as well as by assessment of swabs taken from the wound. Serial photographs of the wound during the study period were taken so as to compare the results. 90% healing was chosen as our end point as the healing of the rest of the wound to completion is generally variable and dependent upon other factors like age, depth and percent of burns. During the follow up period, the patients were examined for formation of either hypertrophic scar or contracture.

Outcome measurement

This was done in the following ways noting the visible changes in the wound including the amount of slough within the wound, the amount of exudates (noted by measurement of weight changes in the dressing materials), the quality and character of granulation tissue within the wound and the character of the skin adjacent to the wound. Microbial assessment of the wound by surface swabs taken by the method described previously at the end of the study period.

RESULTS

Distribution of cases depending upon burn wound percentage profile

In current study, total 53 patients were included in which 30 patients were 30-40% TBSA of burns and 20 patients were 20-30% TBSA of burns (Table 1).

Table 1: Distribution of study population according to burn wound percentage profile.

Burn wound percentage (%TBSA)	N
20-30	23
31-40	30
Total	53

Distribution of cases depending upon pain during dressing changes

Pain was recorded during removal of old dressings as also during application of new dressings. It was found out that intensity of pain felt was significantly (p=0.0001, Chi-square 40.407) lesser incidence in nanocrystalline silver gel dressing side group than in patients of silver sulfadiazine dressing side group (Table 2).

Table 2: Distribution of study population according to pain during dressing changes.

Pain during dressing changes	NCS	SSD
Present	10	43
Absent	43	10
Total	53	53

Distribution of cases depending upon amount of 4078 pitheli after ninth day of dressing

In current study, majority of patients with nanocrystalline silver dressing group had small (38 sides) amount of 4078 pitheli and less, no one of them had medium (8 sides) and heavy (7 sides) 4078 pitheli compared to the silver sulfadiazine dressing group (Table 3, Figure 1).

Table 3: Distribution of cases depending upon amount of 4078 pitheli after dressing on ninth day.

Exudate from wound	NCS	SSD
Small	38	26
Medium	8	15
Heavy	7	12
Total	53	53

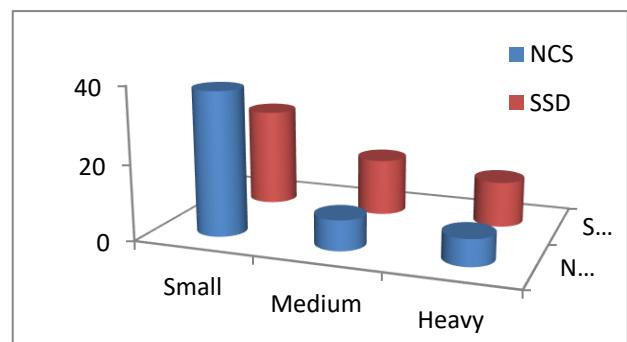


Figure 1: Distribution of study population according to amount of exudate after dressing on ninth day.

Distribution of cases depending upon wound character

Increased slough was not noted in any of the wounds after 9 days in either of the dressed areas as compared to pre dressing wound while decreased slough was noted in each and every wound in both sections dressed with either nanocrystalline silver gel or silver sulfadiazine cream. Increased epithelialization was noted in 40 patients dressed with nanocrystalline silver and 34 patients dressed with silver sulfadiazine. Increased epithelization and decreased inflammation were noted in ~90% patients dressed with nanocrystalline silver gel (Table 4, Figure 2).

Table 4: Distribution of cases depending upon wound character after dressing on ninth day.

Wound character	NCS	SSD
Increased slough	0	0
Decreased slough	53	53
Increased epithelialization	40	34
Increased granulation	48	38
Decreased inflammation	45	40

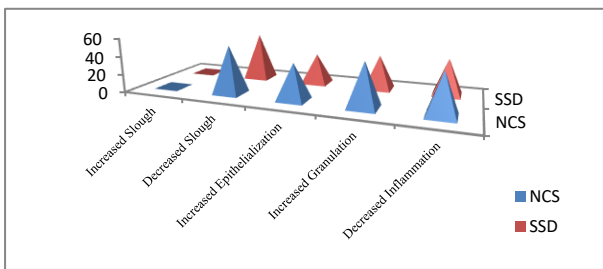


Figure 2: Distribution of study population according to wound character.

Distribution of cases depending upon wound culture

In current study nanocrystalline dressing group showed less no of culture positive cases (18 sides group out of 53 nanocrystalline dressing side group) and it was statistically significant ($p=0.0037$, Chi-square 84.22) (Table 5, Figure 3).

Table 5: Distribution of cases depending upon wound culture.

Culture & sensitivity	NCS	SSD
Sterile cases	35	20
Culture positive cases	18	33
Total	53	53
Infective organism	NCS	SSD
<i>Pseudomonas</i>	10	19
<i>S. Aureus</i> (MRSA)	3	7
<i>Klebsiella</i>	4	4
Other	1	3
Total	18	33

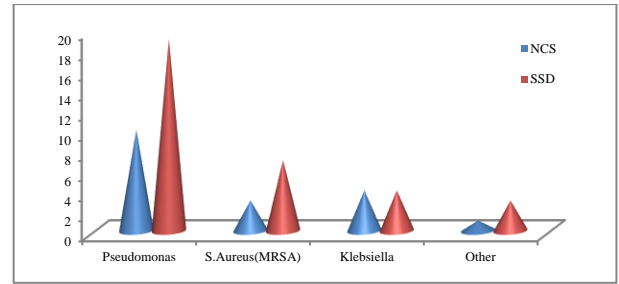


Figure 3: Distribution of study population according to infective organism in wound culture.

Distribution of cases depending upon infective organism

In this study more than 50% of culture positive cases were for *Pseudomonas*. All types of microorganisms are more effectively killed in nanocrystalline silver gel group compared to the SSD group except for *Klebsiella* and proteus.

Distribution of cases depending upon development of wound contracture

During follow up period, nanocrystalline dressing side group showed less no (18 out of 53 nano crystalline dressing side group) of development of wound contracture than silver sulfadiazine group (26 sides out of 53 SSD dressing sides group). There was no significant difference ($p=0.225$, Chi-square, 1471) in both the groups (Table 6, Figure 3).

Distribution of cases depending upon development of hypertrophic scar

Although there was no significant ($p=0.116$, Chi-squared 2463) difference in both the groups, we found that the final esthetic outcome of the healed area (hypertrophic scar) was more superior in nanocrystalline silver dressing group than silver sulfadiazine dressing group (Table 6).

Table 6: Distribution of cases depending upon wound contracture and hypertrophic scar.

Wound contracture	NCS	SSD
Present	8	13
Absent	45	40
Total	53	53
Hypertrophic Scar	NCS	SSD
Present	18	26
Absent	35	27
Total	53	53

Distribution of cases depending upon 90% wound healing in 20 days

Wound healing was significantly higher in patients using nanocrystalline silver gel than silver sulfadiazine dressing

group side in both 20-30% and 31-40% burn wounds of the patients (Table 7).

Table 7: Distribution of cases depends upon 90% of wound healing in 20 days in 20-30% burn and 90% wound healing in 30-40% of burn.

90% wound healing in 20 days in 20-30% burn	NCS	SSD
Present	18	7
Absent	5	16
Total	23	23
90% wound healing in 20 days in 30-40% of burn	NCS	SSD
Present	20	13
Absent	10	17
Total	30	30

Clinical photographs showing burn wound on day 9 showing appearance of granulation tissue with clearance of slough on nanocrystalline silver dressing side (left arm and fore arm) whereas right side of arm and fore arm (control) shows slough with minimum appearance of granulation tissue (Figure 4-5).

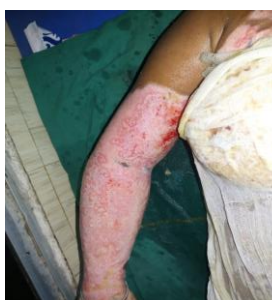

Figure 4: Burn wound on day 9 showing appearance of granulation tissue with clearance of slough on nanocrystalline silver dressing side (left arm and forearm).

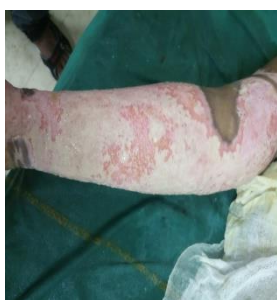

Figure 5: Right side of arm and fore arm (control) shows slough with minimum appearance of granulation tissue.

DISCUSSION

Burn wound infections cause the majority of death in patients with burn wounds in developing countries

because a large proportion of these patients are managed on a conservative basis owing to lack of adequate infrastructure. Early topical application of bactericidal or antibacterial agents is an effective measure which could effectively protect burn wound from bacterial infection and ultimately promote wound healing.

Silver as a topical antimicrobial agent has been used for many countries. Dr. Charles Fox introduced SSD cream in 1970 and since then has been an important part of burns management.¹⁵ However, development of bacterial resistance and impaired reepithelialisation has been described. Bone marrow, liver, renal toxicity are the side effects of SSD.⁵⁻⁸ These adverse effects demand a new therapy options for better management. The advent of nanotechnology has permitted conversion of metallic silver into its nanoparticle form. High surface to volume ratio makes silver nanoparticle more effective even at very low concentration, thus reduces the chance of toxicity. These nanosized silver particles are more effective than its pure form against microbial organisms and holds the promise of making topical silver therapy more effective and better tolerated.

Moreover, the use of SSD cream results in the formation of a pseudo-eschar and can withdraw fluid from this wound surface. Whereas, nanocrystalline silver delivery maintains moisture layer on the wound surface. Advantages of a moist wound dressing include decrease in surface desiccation and eschar formation, increase in local growth factor production, activation of surface proteases to remove devitalized tissue, decrease surface inflammation, enhanced wound surface immune defences, increase rate of angiogenesis and fibroblast proliferation, increased proliferation and migration of epithelial cells along thin water layer.

Hence, current study was conducted to compare the clinically efficacy of compound silver (SSD) and nano sized metallic silver (nanocrystalline silver) on burn wounds.

Current study included of 53 cases (consisting of 53 pairs of side of the body) of 20-40% burns the burns were most commonly found in females and male to female ratio was 1:13 in our study population.

Silver sulfadiazine was found to decrease the exudates production in a large number of patients but nanocrystalline silver gel caused decreased production of exudates in even more patients. This is comparable to the following study conducted by Voight et al and Dunn et al.^{16,17}

Nanocrystalline silver dressing side of the patient experiences less pain during dressing changes compared to silversulfadiazine dressing side. This is comparable to the following study conducted by Tredget et al, Varus et al and Fong et al.¹⁸⁻²⁰

Most common complication of burns in our study population is wound infection, which occurred in 30-40%. The most common causative organism was found to be pseudomonas followed by *S. Aureus*. Nanocrystalline silver dressing side of the patients had a much lower infection rate compared to silver sulfadiazine dressing side group. This is comparable to the following studies done by Hegger et al, Tredget et al, Fong et al, Lansdown.^{18,20-22} Because in complex organic biological fluids, continuous concentration of silver >50 ppm and as high as 60.5 ppm are needed to kill microbes and this difference in the dissolution properties of nanocrystalline silver dressings appears to alter the biological character of the solution including both antimicrobial and anti-inflammatory activities.^{23,24}

Both nanocrystalline silver and silver sulfadiazine were effective in reducing slough from the wound bed, decreasing the size of the wound as assessed by the decrease in surface area of the wound and decreasing inflammation as evidenced by haematological parameter.

In present study nanocrystalline silver dressing side of the patient showed more anti-inflammatory effect compared to silver sulfadiazine side. This was comparable to the Sibbald et al study. Because it reduces local matrix metalloproteinase levels and enhanced cellular apoptosis.²⁵ In current study, most patients were noted to have increased epithelialisation, increased granulation tissue as well as decreased slough following dressing with both nanocrystalline silver gel and silver sulfadiazine cream but there were more in numbers of patients dressing with nanocrystalline silver gel. Granulation tissue appeared faster in wounds treated with nanocrystalline silver and that was evidenced in Wright et al study.²⁶

Twenty days was kept as a cut-off point to study the difference in wound healing in both groups. Because more than 50% of patients had comprehensive wound healing within this time. This was in concurrence with various other studies in wound healing in burns patients. Typically, the wound repair process involves steps that include inflammation around the site of injury, angiogenesis and the development of granulation tissue, repair of connective tissue and epithelium and ultimately remodelling that leads to a healed wound. In present study one event that impedes wound healing was colonization of the wound bed by microorganism.^{27,28} In current study, wound healing were significantly higher in nanocrystalline dressing side group in both 20-30% and 31-40% burns. This was also comparable to the study by Wright et al.²⁶

Wright et al in their animal experiments had demonstrated that after acute injury, rapid wound healing was achieved with nanocrystalline silver dressings. Additionally it was shown that the level of matrix metalloproteinase decreased thereby leading to a decrease in the proteolytic effect of the wound and thereby a

decrease in the inflammation with the wound. It was also shown that dressing in the absence of nanocrystalline silver led to a high level of cellular apoptosis which in turn impaired wound healing but the process was reversed with the administration of nanocrystalline silver. Kirshner additionally showed that initial reduction of matrix metalloproteinase levels associated with nanocrystalline silver dressings led to a persistent decrease in the same with progression of dressing.²⁹

Wound contractures and hypertrophic scar were slightly higher in silver sulfadiazine but there was no statistical significance in both the groups.

Limitations

Limitations of current study were, study included 53 cases (consisting of 53 pairs of side of the body) of 20-40% burns the burns were most commonly found in females and male to female ratio was 1:13 in our study population. Female predominance occurred due to the working atmosphere in kitchen, involvement in dowry problems, stressful life, handling of combustible fuel and volatile gas. Kerosene can easily spill and is highly combustible, accidents are possible while handling.

CONCLUSION

Mortality from burns is on the decrease with the advent of better management and understanding of pathophysiology of burns. This is complimented by newer and more effective topical agents for dressing. Silver sulfadiazine, once considered as the gold standard in burn wound dressings is slowly giving way to other dressing materials although it is still the most widely used dressing material worldwide. Because of antibiotic resistance, local control of infection of the burn wound is now assuming more important than ever. This can be achieved with potent dressing materials as has been shown in our study. From current study it can be concluded that nanocrystalline silver gel dressing can decrease pain, inflammation, exudate formation and bacterial load in a large proportion of patients. Pseudomonas aeruginosa and staphylococcus are the most commonly incriminated organism. Nanocrystalline silver has potent antimicrobial effect. Nanocrystalline silver dressing increases the amount of granulation tissue, epithelization and ultimately healing of the burn wound. In current study, we found that the final aesthetic outcome (hypertrophic scar) of healed area is more superior in nanocrystalline silver group. Further studies regarding cost effectiveness and long term follow up will decide whether it is the appropriate time to consider nanocrystalline silver gel as the gold standard dressing material.

Funding: No funding sources

Conflict of interest: None declared

Ethical approval: The study was approved by the Institutional Ethics Committee

REFERENCES

1. Burns fact sheet. Available at: <http://www.who.int/news-room/fact-sheets/detail/burns>. Accessed on 08 May 2018.
2. Black JM, Hawks JH. *Medical surgical nursing clinical management*. 8th ed. USA: Saunders/Elsevier; 2009.
3. Van Loey NE, Maas CJ, Faber AW, Taal LA. Predictors of chronic posttraumatic stress symptoms following burn injury: Results of a longitudinal study. *J Trauma Stress*. 2003;16:361-9.
4. Stanford W, Rappole BW, Fox CL. Clinical experience with silver sulfadiazine, a new topical agent for control of Pseudomonas infections in burns. *J Trauma*. 1969;9:377-88.
5. Abedini F, Ahmadi A, Yavari A, Hosseini V, Mousavi S. Comparison of silver nylon wound dressing and silver sulfadiazine in partial burn wound therapy. *Int Wound J*. 2013;10:573-8.
6. Muller MJ, Hollyoak MA, Moaveni Z, Brown TL, Herndon DN, Heggers JP, et al. Retardation of wound healing by silver sulfadiazine is reversed by Aloe vera and nystatin. *Burns*. 2003;29:834-6.
7. Chaby G, Viseux V, Poulain JF, De Cagny B, Denooux JP, Lok C, et al. Topical silver sulfadiazine-induced acute renal failure. *Ann Dermatol Venereol*. 2005;132:891-3.
8. Fraser JF, Cuttle L, Kempf M, Kimble RM. Cytotoxicity of topical antimicrobial agents used in burn wounds in Australasia. *ANZ J Surg*. 2004;74:139-42.
9. Naghsh N, Safari M, Hajmehrabi P. Investigating the effect of silver nanoparticles on E. coli growth. *Qom Univ Med Sci J*. 2009;6:65-8.
10. Shiryazdi SM. Compare immediate effect of betadine, sterillum and silver nanocluids in hand disinfection before surgery. *J Med Microbiol*. 1993;8:35-40.
11. Chen X, Schluesener HJ. Nanosilver: a nano product in medical application. *Toxicol Lett*. 2008;176:1-12.
12. Rai MK, Deshmukh SD, Ingle AP, Gade Ak. Silver nanoparticles: the powerful nanoweapon against multidrug resistant bacteria. *J Appl Microbiol*. 2012;112:841-52.
13. Vlachou E. The safety of nanocrystalline silver dressings on burns: A study of systemic silver absorption. *Burns*. 2007;33:979-85.
14. Adhya A, Bain J, Ray O, Hazra A, Adhikari S, et al. Healing of burn wounds by topical treatment: A randomized controlled comparison between silver sulfadiazine and nano-crystalline silver. *J Basic Clin Pharm*. 2015;6:29-34.
15. Fox CL. *Silver sulphadiazine, addendum to local therapy*. New York: Harper and Row; 1967.
16. Voight D, Paul C. The use of Acticoat as silver impregnated telfa dressings in a regional burn and wound care center: the clinicians view. *Wounds*. 2011;13:11-23.
17. Dunn K, Edwards-Jones V. The role of Acticoat with nanocrystalline silver in the management of burns. *Burns*. 2004;30(Supp 1):S1-9.
18. Tredget EE, Shankowsky HA, Groeneveld A, Burrell R. A matched-pair, randomized study evaluating the efficacy and safety of Acticoat silver-coated dressing for the treatment of burn wounds. *J Burn Care Rehabil*. 1998;19(6):531-7.
19. Varas R, O'Keefe T, Namia N, Pizano LR, Tellachea MH, Rashid Q, et al. A prospective, randomized trial of Acticoat versus silver sulfadiazine in the treatment of partial thickness burns: which method is less painful?. *J Burn Care and Rehabil*. 2005;26:344-7.
20. Fong J. The use of silver products in the management of burn wounds: change in practice for the burn unit at Royal Perth Hospital. *Aus J Wound Manage*. 2005;13:S16-22.
21. Heggers J, Goodheart RE, Washington J, McCoy L, Carino E, Dang T, et al. Therapeutic efficacy of three silver dressings in an infected animal model. *J Burn Care Rehabil*. 2005;26(1):53-6.
22. Lansdown AB. Silver. I: Its antibacterial properties and mechanism of action. *J Wound Care*. 2002;11(4):125-30.
23. Maple PA, Hamilton-Miller JM, Brumfitt W. Comparison of the in-vitro activities of the topical antimicrobials azelaic acid, nitrofurazone, silver sulphadiazine and mupirocin against methicillin-resistant Staphylococcus aureus. *J Antimicrob Chemother*. 1992;29:661-8.
24. Taylor PL, Ussher AL, Burrell RE. Impact of heat on nanocrystalline silver dressings. *Biomaterials*. 2005;26:7221-9.
25. Wright JB, Lam K, Buret AG, Olson ME, Burrell RE. Early healing events in a porcine model of contaminated wounds: Effects of nanocrystalline silver on matrix metalloproteinases, cell apoptosis, and healing. *Wound Repair Regen*. 2002;10:141-51.
26. Wright J, Lam K, Burrell R. Wound management in an era of increasing bacterial antibiotic resistance: a role for topical silver treatment. *Am J Infect Control*. 1998;26:572-7.
27. Wright JB, Hansen DL, Burrell RE. The comparative efficacy of two antimicrobial barrier dressings: In vitro examination of two controlled release of silver dressings. *Wounds*. 1998;10:179-88.
28. Robson MC. Wound infection. A failure of wound healing caused by an imbalance of bacteria. *Surg Clin North Am*. 1997;77:637-50.
29. Kirshner R. Matrix metalloproteinases in normal and impaired wound healing: A potential role of nanocrystalline silver. *Wounds*. 2002;13:4-14.

Cite this article as: Maiti B, Bakshi S. A comparative study of the efficacy of nanocrystalline silver gel and silver sulfadiazine cream on the healing of second degree burn wound. *Int Surg J* 2020;7:4076-82.