

Case Report

Multiple cystic lesions in the abdominopelvic cavity one and a half years after resection of presacral neurogenic tumor: tumor recurrence or other?

Umar Zeb Khan¹, Matiullah Masroor², Hai Liu^{1*}

¹Department of General Surgery, The Third Xiangya Hospital of Central South University, Changsha, China

²Department of General Surgery, The Second Xiangya Hospital of Central South University, Changsha, China

Received: 06 September 2020

Revised: 17 October 2020

Accepted: 28 October 2020

***Correspondence:**

Dr. Liu Hai,

E-mail: minisurgery@126.com

Copyright: © the author(s), publisher and licensee Medip Academy. This is an open-access article distributed under the terms of the Creative Commons Attribution Non-Commercial License, which permits unrestricted non-commercial use, distribution, and reproduction in any medium, provided the original work is properly cited.

ABSTRACT

Cystic lesions of abdominopelvic cavity include a variety of pathologies and diagnosis can sometimes be challenging. Urinoma can be caused by iatrogenic injury, spontaneous rupture of ureters or by various causes of ureteral obstruction. It needs to be differentiated from abdominopelvic cystic diseases including tumors that can undergo cystic degeneration. Here we report a case of a 41 years old female underwent a presacral neurogenic tumor resection at a local hospital 5 years ago. The tumor recurred three and a half years after the first surgery and removed at another hospital. She experienced abdominal distension and difficulty in urination from the last 2 months and was diagnosed as having a recurrence of tumor once again at both hospitals on separate CT scans. They believed that the tumor was too large and encroaching on adjacent organs to be surgically resected, she was finally diagnosed as infected urinoma during surgery in our hospital. Even though spontaneous rupture of ureters and urinoma formation is a rare disease but it should be considered as a main differential diagnosis of recurrence of neurogenic tumors especially in post abdominopelvic surgeries patient.

Keywords: Urinoma, Neurogenic neoplasia, Presacral surgery, Retroperitoneal surgery, Spontaneous rupture of ureter

INTRODUCTION

Cystic lesions of retroperitoneal space include a variety of pathologies that can be classified as either neoplastic or non-neoplastic, and diagnosis can sometimes be challenging. A urinoma is the collection of urine leaked from any part of urinary system and surrounded by a fibrous capsule in the perirenal area, retroperitoneal region or even intraperitoneal region.^{1,2} The fibroblastic reaction helps the formation of the fibrous capsule of urinoma later on without the epithelial lining. Spontaneous perforation of the ureter is very rare, it can be caused by ureteral calculi, retroperitoneal fibrosis,

post-radiation scarring, and even in some cases with no obvious cause.^{3,4} Ureteral fistula is mostly caused by iatrogenic ureteric injury including either direct transection, suture ligation, crush and thermal injury, or indirect trauma of devascularization and ischemia, and is a potential complication of any retroperitoneal-pelvic surgery whether for urological, general surgical or gynecological disease, so it should be taken as a major differential diagnosis of cystic lesions, especially for a recurrent neurogenic neoplasia, which tends to be large, and in some instances, intralésional cystic degeneration occurs, making proper diagnosis more difficult.^{2,5-8} We report a patient with infected urinoma developed one and a half year after excision of recurrent pelvic neurogenic

tumor, and discuss the clinical presentation, the diagnostic work-up, and proper management with review of the literature.

CASE REPORT

A 41 year old female admitted to our hospital with complain of abdominal pain and distention from the last 2 months. In past medical history, she denied any other medical disease but underwent two surgeries for resection of presacral tumor. The first operation was done via median incision of lower abdomen 5 years ago at a certain hospital in southwest china, and the pathological diagnosis was neurogenic neoplasm. She recovered well and followed up every 6 months for three years without any obvious problem. Three and half years later she presented to the same hospital for the complaint of frequency and dysuria. CT scan showed the recurrence of tumor that made the patient worry and visited another hospital in Beijing and admitted there. CT scan of second hospital also showed pelvic occupying lesion with right ureter dilatation and right hydronephrosis. She underwent the second surgery (sacro coccygectomy+tumor resection) one and a half years ago. A mass of 5x20x3 cm was removed after resection of tail bone. Histopathology report was presacral myxoid neoplasia, neurofibroma considered. She was discharged 10 days after surgery in good condition with stitches removed, and she was well for about one and a half year afterwards. However, for the last two months, she had been suffering from persistent abdominal pain aggravated by meals, complaining of fatigue and loss of appetite. A week earlier she developed painful micturition and was taken to local hospital where a Foley catheter was applied. She went to the previous hospital in Beijing for further diagnosis and treatment. There she took a plain and contrast enhanced pelvic CT scan that showed giant, space occupying cystic lesion considered as tumor recurrence. Because the lesion was in close connection with pelvic organs, it was supposed unresectable form surgical point of view and she was referred to our hospital for further management.

On physical examination she looked a little pallor, body temperature 37.5°C, pulse 93 times/minute, respiratory rate 16 times/minute, blood pressure 120/80mmHg. Abdominal examination revealed abdominal distention, about 20 cm long surgical scar in the middle of the lower abdomen, localized protrusion in the upper portion of the scar (incisional hernia), weakened abdominal breathing, no varicose veins in the abdominal wall, no peristaltic wave, a giant mass without obvious boundary felt in the left upper abdomen, extending to pelvis. There is slight tenderness but no rebound tenderness.

Laboratory investigation of urinalysis showed WBC 40/ul, bacterium 2+, complete blood cell count (CBC) showed WBC $15.43 \times 10^9/L$, RBC $4.5 \times 10^{12}/L$, PLT $362 \times 10^9/L$, urine cultures were positive for *Escherichia coli*, liver and kidney function test were almost normal.

A full abdominal CT scan was taken and the results as follow; multiple circumscribed round and oval cystic lesions with a well-developed capsule and septa can be seen in pelvis and right abdomen, some lesions were filled with contrast media in delayed scan (Figure 1). A cystic lesion of about 17.7x10.9 cm in size was seen on the left abdomen, with thick capsule, the internal density was uniform, the value of plain scan was 8Hu and without enhancement, its borderline with bowel, mesentery and right psoas muscle was not clear, viscera such as bowel, bladder and uterus were displaced (Figure 2). There was mild hydronephrosis in the right kidney and mild dilatation in the middle-upper part of right ureter (Figure 3). Final radiographic diagnosis; firstly, the cystic lesion in the left abdominal cavity was considered to be an ovarian cystadenoma or mesenteric cyst; secondly, multiple cystic lesions in the abdominopelvic cavity were considered to be ureteric leakage of the right ureter, whereas the reason of right hydronephrosis and right hydroureter should be considered in combination with surgical history.

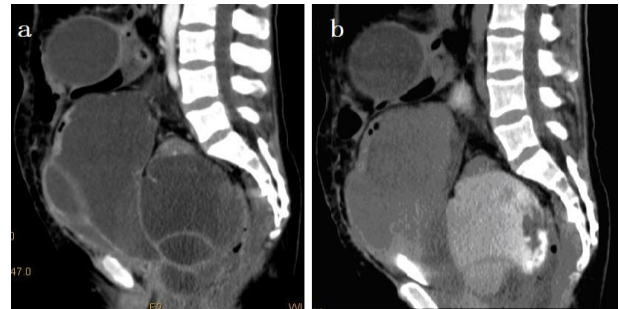


Figure 1: In sagittal plane, multiple cystic lesions were found in the abdominopelvic cavity, a) on plain scan, septated cysts can be seen, b) on delayed scan, the pelvic cysts were filled with contrast agent.

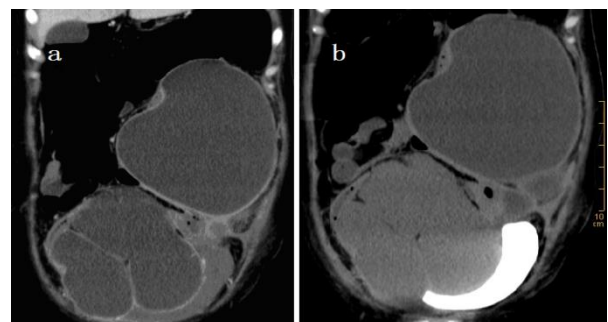


Figure 2: On the coronal scan, there were multiple giant cysts in the abdomen, a) on plain scan, thick cystic wall and septa were seen, b) on delayed scan, the bladder was pushed upper left from pelvis to abdomen.

Antibiotics and nutritional support were given since admission and an explorative laparotomy was performed on day 9 after admission. The previous incision of the abdomen was incised. There were dense adhesions and adhesiolysis was done carefully. The cystic masses in the

left upper abdomen were punctured with a syringe, and the milky white liquid was extracted. The thickened capsule was cut open with electrocautery for convenience of suction. About 4.5 liter of milky white, foul smelling fluid was suctioned and the abdominal masses were disappeared. So, it was supposed to be urine leakage and urinoma formation which became infected and resulted in abdominal abscess. A rubber tube drain with side holes was placed in cavity of the cyst and exerted from left side of abdominal wall. Because of severe adhesion, the lesions in pelvis were left for drainage under the guidance of ultrasound. A double-J stent was placed in right ureter and ureter integrity restored back at the same time. Abdomen was closed in layers and the incisional hernia was repaired simultaneously. Ultrasound-guided Puncture and drainage of residual pelvic cyst was performed later on and about 3000ml liquid of the same nature was drained. The drainage was sent for laboratory test which showed WBC 4+/HP, creatinine 374 umol/L, bacteria culture negative, but *Candida albicans* positive. Antibiotics and nutrition support continued for a couple of days after operation. Antifungal was given accordingly. The postoperative pathological diagnosis was pseudocyst. Her postoperative course was uneventful, and she made excellent recovery. She was discharged on day 9 after surgery.

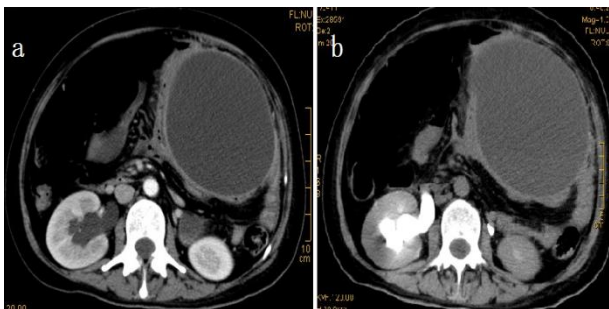


Figure 3: Transverse section on right renal hilum plane, right kidney with mild hydronephrosis and ureteral dilatation, a large cystic mass in left upper abdomen, a) arterial phase scan, b) delayed scan.

DISCUSSION

Spontaneous perforation of the ureter and the formation of urinoma or abscess near the site of obstruction is a rare disease that poses a difficult diagnostic and therapeutic dilemma. In this case, lower ureteral obstruction was present before the second operation and it may be associated with recurrent tumor compression or postoperative ureteral adhesions. The diversity of clinical manifestations makes it difficult to differentiate from previous neurogenic tumor which can undergo cystic degeneration.^{7,8} CT scan is necessary and ultrasonography is also very useful in the diagnosis of retroperitoneal pelvic cystic lesions.² Puncture and drainage under the guidance of CT or ultrasound is not only a diagnostic method, but also a safe and effective treatment for benign lesions. The drainage material can

be used for cytological, bacteriological and digestive enzyme test, it's very helpful in clarifying the diagnosis.⁹ This case was misdiagnosed as having a recurrence of tumor in the previous two hospitals. The objective reason may be that the tumor is a mucinous neurogenic tumor, which is difficult to differentiate from a urinoma. Subjectively speaking, one of the reasons may be related to the fact that only pelvic CT scan was performed instead of a full abdominal CT scan. They didn't know the full extent of the disease or the entire urinary system. Another reason may have to do with ignoring the patient's general condition. The patient had low fever, mild abdominal tenderness, a marked increase in white blood cells on a CBC analysis, and leukocytosis on a urine analysis. All of these suggest that the patient has symptoms of infection, which cannot be explained by tumor recurrence.

The treatment strategy for urinoma should be individualized. Successful approaches in the literature include the retrograde insertion of a double-J ureteral stent and/or nephrostomy drainage with antibiotics. These catheters are usually left in place until final surgery can be performed. In unknown cause cases, the catheter can be removed once the patient's clinical condition improves and the image is consistent with the improvement of clinical symptoms.⁶ In general, timely diagnosis and intervention can reduce complications and mortality. Generally speaking, the infection should be controlled first, and the definitive operation should be scheduled. Traditionally, reconstructive surgery requires a three-month waiting time for inflammation, adhesions, tissue edema to subside and anatomic repositioning of the organs.¹⁰

CONCLUSION

Although spontaneous rupture of ureters leading to urinoma is a rare disease and diagnosis can be challenging specifically in cases where patient already underwent previous surgeries for a recurrent disease which can be easily misleading to other diagnosis like recurrence of the given disease. Precise diagnosis can be made from a detailed medical history, careful laboratory test analysis, and imaging studies. This case suggests that the characteristics of the urinoma are similar to that of the abdominopelvic cystic lesions. It can be confusing with recurrence of neurogenic neoplasia especially those which are large and having intralésional cystic degeneration. It should be considered as a major differential diagnosis of tumor recurrence especially after abdominopelvic surgeries. Awareness and high index of suspicion is crucial for the appropriated diagnosis.

ACKNOWLEDGEMENTS

We would like to thank Dr. Bin Liu, department of urology, the third Xiangya hospital, central south University, for his help in clinical work.

Funding: No funding sources

Conflict of interest: None declared

Ethical approval: Not required

REFERENCES

1. Goldwasser J, Wahdat R, Espinosa J, Lucerna A. Urinoma: prompt diagnosis and treatment can prevent abscess formation, hydronephrosis, and a progressive loss of renal function. *Case Rep Emerg Med.* 2018;2018:5456738.
2. Yang DM, Jung DH, Kim H, Kang JH, Kim SH, Kim JH, et al. Retroperitoneal cystic masses: ct, clinical, and pathologic findings and literature review. *Radio Graphics.* 2004; 24:1353-65.
3. Yanaral F, Ozkan A, Cilesiz NC, Nuhoglu B. Spontaneous rupture of the renal pelvis due to obstruction of pelviureteric junction by renal stone: A case report and review of the literature. *Urol Ann.* 2017;9(3):293-5.
4. Stravodimos K, Adamakis I, Koutalellis G, Koritsiadis G, Grigoriou I, Screpetis K, et al. Spontaneous perforation of the ureter: clinical presentation and endourologic management. *J Endourol.* 2008;22(3):479-84.
5. Aguilera A, Rivas JG, Franco LMQ, Quesada-Olarte J, Carrion DM, Martinez-Pineiro L. Ureteral injury during abdominal and pelvic surgery: immediate versus deferred repair. *Cent European J Urol.* 2019;72(3):312-8.
6. Gild P, Kluth LA, Vetterlein MW, Engel O, Chun FKH, Fisch M. Adult iatrogenic ureteral injury and stricture incidence and treatment strategies. *Asian J Urol.* 2018;5:101-6
7. Harada TL, Nagao G, Aoyagi T, Kuroda I, Tokuyama N, Takahashi M, et al. Giant retroperitoneal schwannoma in a 52-year-old man. *Radiol Case Rep.* 2018;13(4):810-4.
8. Ogose A, Kawashima H, Hatano H, Ariizumi T, Sasaki T, Yamagishi T, et al. The natural history of incidental retroperitoneal schwannomas. *PLoS One.* 2019;14(4):e0215336.
9. Morotti A, Busso M, Barozzino CM, Cinardo P, Angelino V, Familiari U, et al. Detection and management of retroperitoneal cystic lesions: A case report and review of the literature. *Oncol Lett.* 2017;14(2):1602-8.
10. Eken A, Akbas T, Arpacı T. Spontaneous rupture of the ureter. *Singap Med J.* 2015;56:29-31.

Cite this article as: Khan UZ, Masroor M, Liu H. Multiple cystic lesions in the abdominopelvic cavity one and a half years after resection of presacral neurogenic tumor: tumor recurrence or other?. *Int Surg J* 2020;7:4180-3.