

Case Series

Modification of varicose vein stripping to achieve immediate compression in a theatre setting with minimum personnel

Joseph Francis, Nihaz Y. Nazer*

Department of General Surgery, Travancore Medical College, Kollam, Kerala, India

Received: 29 August 2020

Revised: 10 September 2020

Accepted: 14 September 2020

***Correspondence:**

Dr. Nihaz Y. Nazer,

E-mail: nihaznazer@gmail.com

Copyright: © the author(s), publisher and licensee Medip Academy. This is an open-access article distributed under the terms of the Creative Commons Attribution Non-Commercial License, which permits unrestricted non-commercial use, distribution, and reproduction in any medium, provided the original work is properly cited.

ABSTRACT

Compression bandaging is a key aspect following stripping for varicose vein surgery. With adequate compression, formation of subcutaneous hematoma can be prevented and thereby prevent revascularisation of the hematoma leading to recurrence of varicose vein. Various techniques exist to provide compression. Our modification provides an easy alternative to achieve immediate compression following stripping and is especially useful in a setting where staff is very limited. Materials required include a 10 cm width gauze bandage, 1% lidocaine with epinephrine, and number 1 silk suture in addition to the conventional tools for open varicose vein surgery. The gauze bandage is introduced along with the stripper which is passed from groin to below knee. The bandage is kept in the subcutaneous tunnel till perforator ligation, groin wound closure and application of compression bandage. The gauze bandage is removed through a small window within the compression stocking below the knee and the wound closed in a single layer. From 2005 to 2020, 410 patients underwent varicose vein surgery with the modified technique. Of these, 1 patient developed complication secondary to hematoma formation which was managed conservatively. Our modification of the varicose vein stripping technique is shown to be a cost effective and simple technique which provides immediate compression and effortlessly facilitates haemostasis till wounds are closed and compression stockings applied. in various literatures.

Keywords: Varicose vein surgery, Great saphenous vein stripping, Compression following GSV stripping

INTRODUCTION

Varicose vein is a disease that affects 22 million women and 11 million men between the ages of 40 to 80 years.¹ Symptoms of uncomplicated disease includes pain, aching, heaviness, itching, cramps and restless legs.² Without treatment, varicose veins may progress in severity and extent.³ They can rupture and bleed or thrombose and are associated with a 7-fold increased risk of DVT.⁴

Clinical practice guidelines from the Society for Vascular Surgery and the American Venous Forum recommend surgery as the primary treatment of symptomatic varicose veins.⁵ Evolution of minimally invasive techniques have resulted in newer modalities for ablation such as laser or

radio frequency ablation, yet conventional surgery remains the mainstay of varicose veins treatment.⁶ Following surgery, application of compression bandaging is a well analyzed procedure in order to reduce the risk of hematoma formation and recurrence.⁷

A standard method to apply compression bandage after great saphenous vein (GSV) stripping is to wrap the bandage from ankle to groin just before stripping, with adequate exposure of the exit wound for closure after stripping. This requires sufficient staff to lift the limb, while wrapping the compression dressing and closing the wound simultaneously. Moreover, this method carries the chance of blood staining the dressing when pulling out the vein. Alternatively, compression stockings can be applied

at the end of the entire procedure but carries the risk of hematoma formation during the gap between stripping and closure time.

Our technique provides an alternate solution which overcomes the inherent problems of applying the compression bandage to attain hemostasis and facilitates immediate compression especially in a setting with minimum staff. This technique was adopted into our practice as there were only two sterile staff- the surgeon and assisting nurse at the time of surgery. Due to the ease of performing this modification, we continued this maneuver even with excess theatre workforce.

In this study, we provide the details and results of our modification of stripping for varicose vein surgery which we have been using for the past 15 years.

CASE SERIES

From 2005 to 2020, 410 patients underwent Trendelenburg surgery with inverted stripping of GSV and perforator ligation using the modified method. The cases were performed initially in the district government hospital, from 2005 to 2013 and then at Travancore Medical College, Kerala, from 2014 onwards.




Figure 1: Additional materials required for surgery, other than for conventional stripping.

The materials required in addition to the tools used for conventional stripping, is a sterile 10 cm width gauze bandage, 1% lidocaine with epinephrine and a number 1 silk suture as shown in Figure 1.

The saphenofemoral junction is identified by using the landmark 4 cm lateral and inferior to the pubic tubercle. At most times, a 2-3 cm incision is sufficient for adequate exposure and ligation of tributaries. The stripper is passed through the saphenous vein down to 7-10 cm below the knee joint. A small incision is made over the stripper below the knee joint and retrieved. The distal part of the vein is ligated and divided.

A 10 cm wide gauze bandage is folded in such a way that the length of the bandage is equivalent to twice the distance between the groin incision and the below knee incision (Figure 2). It is then folded in half, in effect making the bandage equivalent to the length of the GSV being stripped. The gauze piece is then soaked in 1% lidocaine with epinephrine. A number 1 silk is folded four times with one end attached to the gauze bandage and the other end tied securely to the stripper head and proximal GSV (Figure 3).

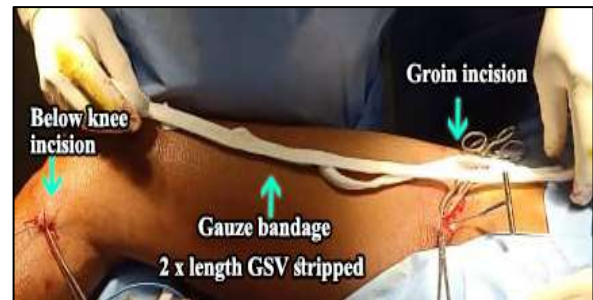

Figure 2: Measuring length of 10 cm gauze bandage.

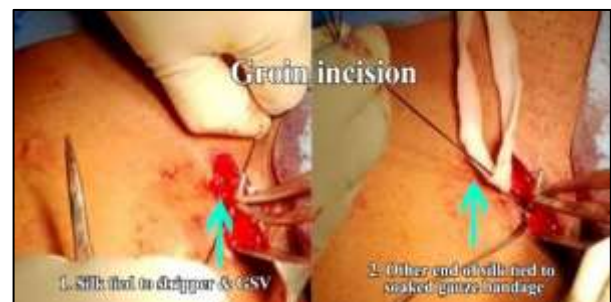

Figure 3: Attaching gauze bandage to GSV and stripper head with silk suture.

The GSV is then inverted and stripped from groin to below knee in a steady manner, pulling in the gauze bandage through the subcutaneous tunnel and out through the below knee incision (Figure 4). Leaving the gauze bandage in situ, the groin incision is closed in layers using 2-0 vicryl and 3-0 monocryl. After dealing with the perforators through incisions in pre-operatively marked areas, these incision sites are closed in a single layer using 3-0 monocryl.

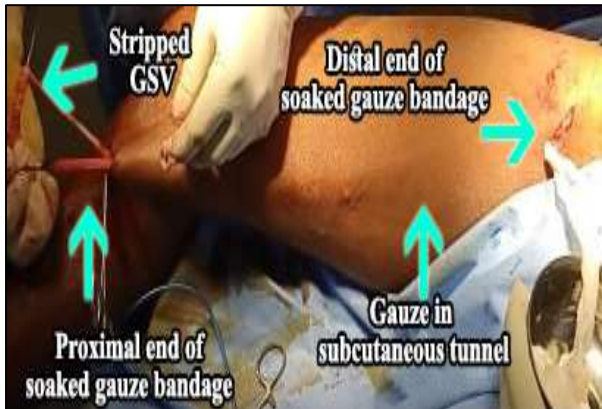

Figure 4: Stripping the GSV along with placing gauze bandage in subcutaneous tunnel.

The limb is then wrapped from foot to groin with pads and elastocrepe bandage applied. A small gap is left below the knee at the exit site of the gauze bandage in the subcutaneous tunnel. Once adequate compressive dressing has been applied to the limb, gauze bandage is removed from the subcutaneous tunnel using a steady pressure and site closed in a single layer with 3-0 monocryl.

Patients are discharged on post-operative day three after wound examination and dressing. They are advised to apply compression bandage during daytime for three weeks. Patient is reviewed one week after discharge during which sutures are removed. Patients are then advised further follow up only if needed.

For the 410 patients, data collected included patient characteristics such as age, sex, address, co-morbidities. All patients underwent venous doppler to confirm the clinical findings, for perforator marking and to document the absence of deep vein thrombosis. In our prospective study, there were 261 male patients and 149 female patients (Table 1). The age of patients ranged from 20-65 years with mean of 52 years, as shown in Table 2. 60 patients underwent bilateral lower limb varicose vein surgery in the same sitting.

Table 1: Sex distribution of study population.

Total patients	Male	Female
410	261	149

Table 2: Age distribution of patients in the study.

Age (in years)	Total patients (%)	Male	Female
20-40	81 (20)	58	23
40-60	234 (57)	155	79
> 60	95 (23)	48	95

On routine course, patients are examined twice for any evidence of complications. On post-operative day 3, wound is examined for any signs of complications such as inflammation, infection, wound dehiscence or hematoma formation. None of the patients in our study population had any major complications at the time of discharge. Patients are then reviewed after a week from discharge during which sutures are removed and are re-examined for any complications (Table 3). During this post-operative day 10 follow up, one patient was noted to have an adverse event secondary to the surgery. The patient, a female, developed hematoma along the medial aspect of thigh which was managed conservatively in the hospital. We did not notice any adverse events with respect to hematoma formation, unusual pain, sensory or cosmetic impairment in the rest of the patient population. None of the patients have returned with complaints or features suggestive of recurrence.

Table 3: Incidence of post-operative complications.

Follow up time	Incidence of major complication
Post-operative day 3	0
Post-operative day 10	1 (0.24%)

DISCUSSION

The advantages of invaginated stripping and stripping from groin to below knee has been well documented by studies on neurophysiological outcomes.⁸ Following stripping, the rationale for compression bandaging is to prevent hematoma formation and thereby reduce the risk of recurrence by revascularization of hematoma.⁹ Studies have found that subcutaneous hematoma formation is the commonest complication after surgical stripping of varicose veins.¹⁰

Different studies have shown various methods to prevent post-operative hematoma formation. Methods to prevent excessive bleeding from stripper track include tightly applying a sterile elasticated bandage while the stripper is withdrawn or by gently rolling a swab along the course of the vein until all the bleeding has stopped before applying the bandage.¹¹ Studies have demonstrated that higher compression by inelastic bandaging or by eccentric compression is more effective in reducing post-operative pain and complications.¹² Other methods like application of antiembolism stockings at end of the procedure may not give adequate compression.¹³

Literature review has shown that very few studies have assessed the timing of compression bandaging. Generally, the limb can be bandaged or have a compression stocking applied as soon as the wounds are closed.¹⁴ This delaying in application of compression bandage till wounds have been closed after stripping carries the risk of bleeding into the tract and hematoma formation. The prevalent method of applying the compression bandage prior to stripping requires adequate assistance and increases the chance of blood stain on the external bandage.

Our method aims to facilitate compression of the GSV track immediately after stripping. By inserting a gauze bandage soaked with lidocaine and epinephrine following stripping, gives adequate time for the surgeon to conduct the remaining part of the surgery including perforator ligation, wound closure and application of the sterile compression dressing without the risk of bleeding into the subcutaneous track and maintain a clean dressing.

Few studies have assessed the use of gauze bandage for varicose vein stripping, however they have not folded the gauze bandage and used a smaller size of 4 cm width 15 and 5 cm width.¹⁶ By using a bigger width of gauze bandage and folding the bandage, we gain additional thickness for hemostasis and have not noticed any problems secondary to this additional thickness. Both the studies have used 1% lidocaine with epinephrine for soaking the bandage. Additionally, these authors have also highlighted that using gauze bandage facilitates the removal of any remaining vein segments while acknowledging that inverted stripping rarely causes avulsion.¹⁵

Of the 410 patients that underwent varicose vein stripping with this modification, only 1 developed a complication. The patient developed a subcutaneous hematoma which was discovered 10 days post procedure. For this patient, the gauze bandage was soaked in plain lignocaine instead of a combination with epinephrine. This over-sight and the time between closing the wound and applying compression may have contributed to the complication. The patient did not come for further follow up and therefore the possibility to re-vascularization is not known.

Within the limitations of the design of our study, we have found that there are various advantages of our method. The main advantage is the ease at which immediate compression can be achieved as a bridge till wounds are closed and compression stockings applied. Using a bandage along with the stripper head helps exert pressure for vein removal and to remove any residual vein in the tract. This offers the benefit of achieving instantaneous compression and the ability to maintain a clean dressing that is free of blood stains. Conducting a randomized control trial with a longer follow up period will give better insight into the statistical significance of these advantages.

CONCLUSION

Conventional flush ligation and stripping remains the gold standard technique for treatment of varicose veins. Subcutaneous hematoma formation after stripping is the commonest complication and can cause recanalization and recurrence of varicose veins. Post-operative compression is given to reduce risk of hematoma formation. The first problem with applying compression bandage is that there is a delay and increased risk of hematoma formation if bandaging is postponed till wounds closed. Secondly, it requires adequate manpower to elevate the leg, to apply the bandage and close the wound simultaneously.

Our method is a simple modification which is also cost-effective solution that does not require any additional time or skill to perform. This modification helps facilitate removal of the vein, attain immediate hemostasis, preserve a clean post-operative dressing and helps achieving compression especially when the theatre workforce is limited.

Funding: No funding sources

Conflict of interest: None declared

Ethical approval: Not required

REFERENCES

1. Hamdan A. Management of varicose veins and venous insufficiency. *JAMA*. 2012;308(24):2612-21.
2. Perkins JM. Standard varicose vein surgery. *Phlebology*. 2009;24(1):34-41.
3. Piazza G. Varicose Veins. *Circulation*. 2014;130(7):582-7.
4. Müller-Bühl U, Leutgeb R, Engeser P, Achankeng EN, Szecsenyi J, Laux G. Varicose veins are a risk factor for deep venous thrombosis in general practice patients. *Vasa*. 2012;41(5):360-5.
5. Głowiczki P, Comerota AJ, Dalsing MC. The care of patients with varicose veins and associated chronic venous diseases: clinical practice guidelines of the Society for Vascular Surgery and the American Venous Forum. *J Vasc Surg*. 2011;53(5):2-48.
6. Winterborn RJ, Corbett CR. Treatment of varicose veins: the present and the future--a questionnaire survey. *Ann R Coll Surg Engl*. 2008;90(7):561-4.
7. Turgunov EM, Kiktev II, Balykbaeva AM, Korobeinikova DV, Galitskiĭ FI. Efficacy of compression hosiery and elastic bandaging after surgical treatment of varicose veins. *Angiol Sosud Khir*. 2019;25(4):108-115.
8. Jaworucka-Kaczorowska A, Oszkinis G, Huber J, Wiertel-Krawczuk A, Gabor E, Kaczorowski P. Saphenous vein stripping surgical technique and frequency of saphenous nerve injury. *Phlebology*. 2015;30(3):210-6.
9. Munasinghe A, Smith C, Kianifard B, Price BA, Holdstock JM, Whiteley MS. Strip-track

- revascularization after stripping of the great saphenous vein. *Br J Surg.* 2007;94(7):840-3.
10. Keith LM, Smead WL. Saphenous vein stripping and its complications. *Surg Clin North Am.* 1983;63(6):1303-12.
 11. Kirk RM. *General surgical operations.* 3rd ed. Churchill Livingstone; 1994: 879.
 12. Mosti G. Post-treatment compression: duration and techniques. *Phlebology.* Mar 2013;28(1):21-4.
 13. Cuschieri A, Steele RJC, Moossa AR. *Essential surgical practice.* 4th ed. Butterworth-Heinemann; 2000: 2.
 14. Margaret F, James H, Brendan M. Farquharson's textbook of operative general surgery 10th ed. FL, U.S.A: CRC Press; 2015: 110.
 15. Bergan JJ. *The vein book.* Elsevier Academic Press. 2007;xvii:617.
 16. Teruya TH, Ballard JL. New approaches for the treatment of varicose veins. *Surg Clin North Am.* 2004;84(5):1397-417.

Cite this article as: Francis J, Nazer NY. Modification of varicose vein stripping to achieve immediate compression in a theatre setting with minimum personnel. *Int Surg J* 2020;7:3418-22.