

## Case Report

# A rare case: adenoma of the epididymis

**Sheena Wadhwa\*, Ashwini Rajareddy Kothudam, Sri Ram Varma Angani,  
Syed Iqbalulla Sha Khadri**

Department of General Surgery, Rajarajeswari Medical College and Hospital, Bengaluru, Karnataka, India

**Received:** 05 September 2020

**Accepted:** 08 October 2020

**\*Correspondence:**

Dr. Sheena Wadhwa,

E-mail: [wsheena@gmail.com](mailto:wsheena@gmail.com)

**Copyright:** © the author(s), publisher and licensee Medip Academy. This is an open-access article distributed under the terms of the Creative Commons Attribution Non-Commercial License, which permits unrestricted non-commercial use, distribution, and reproduction in any medium, provided the original work is properly cited.

### ABSTRACT

Adenomatoid tumour accounts for less than 1-2 % of all intrascrotal neoplasms which usually presents incidentally. It is a non-hormone dependent, uncommon benign mesothelial neoplasm, usually localized in the epididymis. Presenting a case of a 38 years old male requesting for consultation regarding a small lump that he palpated three years ago in his left hemiscrotum during self-examination. U/S examination of the scrotum with Doppler and cytopathology report revealed a benign adenomatoid tumour arising from the left epididymis. Surgical treatment was decided and a left scrotal exploration with excision of the mass was performed with annual follow up. We report here an interesting case of an adenomatoid tumour of the epididymis from our institution, owing to its sheer rarity, even today.

**Keywords:** Adenoma, Epididymis, Paratesticular tumour

### INTRODUCTION

Para testicular tumours are rare and account for approximately 5% of intra-scrotal neoplasms, roughly 75% of which arise from the spermatic cord.<sup>1</sup> Adenomatoid tumors are the most common neoplasms arising from paratesticular tissue, accounting for 30% of them.<sup>1</sup> Adenomatoid tumor is not dependent on any hormones and is a rare benign mesothelial neoplasm, usually localized in the epididymis.<sup>2</sup> It is the most common paratesticular tumor of middle aged patients (average age of clinical presentation, 36 years). The most common presentation is a small (0.5 to 5 cm) painless paratesticular mass detected on routine examination in a man in his third or fourth decade. These tumours are benign and managed by inguinal exploration and surgical excision. However, nuclear atypia and local invasive behaviour have sometimes been noticed, especially in tumors in the head of epididymis.<sup>1,4</sup> Since intra scrotal masses are considered to be malignant, this would be a unique benign occurrence within the scrotum. It is

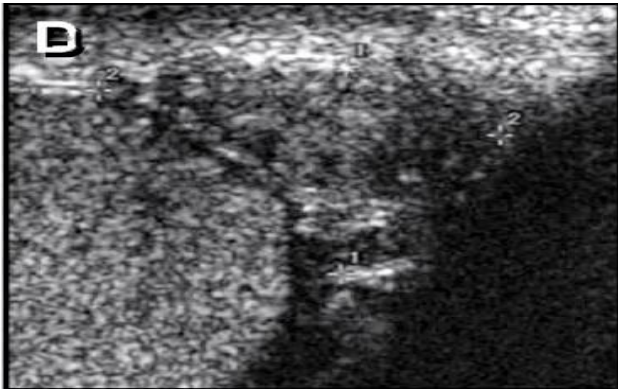
important to be aware of such benign lesions within the epididymis so as to preemptively plan testicular sparing procedures and avoid orchidectomy.<sup>5</sup>

### CASE REPORT

A 38 years old male presented as an outpatient requesting for consultation regarding a small lump that he had palpated three years ago in his left hemiscrotum during self-examination, also giving history of discomfort during exercise and weight lifting. The size of the lump gradually increased to the current size. On General Physical examination, he was moderately built and well nourished. His vitals were normal. On local examination, a small, rounded mass measuring 2x2 cm was found in the left hemiscrotum, non-tender, firm in consistency and localized to the globus minor.

### Investigations

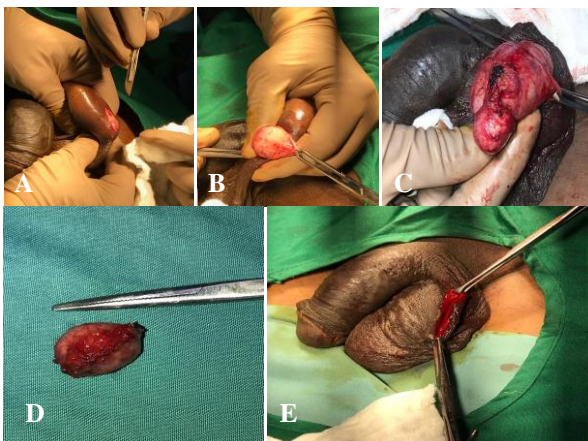
U/S examination of the scrotum with Doppler documented the presence of a hypoperfused, hyperechoic, well demarcated mass, localized to the globus minor, 1.88x1.48 cm in size on the left side, highly suggestive of an adenomatoid tumour of the epididymis. The routine blood examination and the values of the specific tumor markers AFP, LDH, CEA and beta-HCG were normal. Cytopathology report of the swelling revealed benign looking clusters of spindle cells with ovoid, vesicular nuclei with clear cytoplasm in few and vacuolated in few cells suggestive of benign adenomatoid tumour.



**Figure 1: USG scrotum demonstrating adenomatoid tumour in the epididymis (marked).**

### Treatment

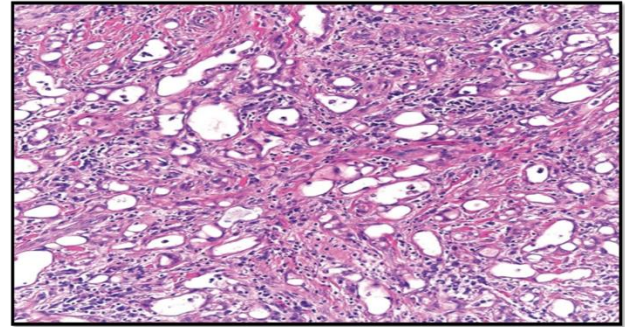
Surgical treatment was decided and a left scrotal exploration with excision of the mass was performed under spinal anesthesia.



**Figure 2: Intra-operative findings A) incision for left sided scrotal exploration, B) after making incision, distinct adenomatous mass noted, arising from left epididymis, C) adenomatous tumour epididymis as seen intraoperatively, D) adenomatous mass excised, E) final look after excising mass, before closure.**

### Histopathological examination

Macroscopic examination revealed a solid, globular unencapsulated mass with smooth surface, measuring 2x3 cm located next to the globus minor. Microscopic examination revealed the presence of cuboidal vacuolated epithelial cells in tubular clusters with a fibrous stroma with a smooth muscle component, suggestive of benign left sided adenoma of epididymis.



**Figure 3: Histopathological image of excised mass demonstrating epithelial cells with fibrous stroma with smooth muscle component.**

### DISCUSSION

Adenomatoid tumors account for approximately 1-2% of intrascrotal neoplasms. Like most intra-scrotal tumors, adenomatoid tumors are more common in Caucasians, with the greatest incidence occurring between third to fifth decade of life. Most tumors originate from the lower or upper poles of epididymis or in their vicinity with a higher incidence in the lower pole.<sup>2</sup>

There are several theories about their histogenesis; mesothelial, müllerian, mesonephric, and endothelial origin. It being of a mesothelial origin however is the most widely accepted and is supported by electron microscopy.<sup>2</sup> Guo et al reported a case of adenomatoid tumor of tunica albuginea in a 12 year old boy.<sup>6</sup> Montero reported the first case of this type of tumor in Spanish urological literature in 1968.<sup>7</sup> Since then, 35 cases of this rare lesion have been reported.

Adenomatoid tumors are usually incidental findings with patients sometimes reporting mild discomfort or pain, mainly during exercise. Usually, there is no correlation between the tumor and previous scrotal inflammation or trauma.<sup>2</sup> Differential diagnoses includes all possible testicular and para-testicular masses as well as other scrotal abnormalities such as lipoma, sarcoma, granuloma, and hematoma of the spermatic cord.<sup>8</sup>

Ultrasonography is the primary imaging modality and is vital for a preoperative diagnosis.<sup>4</sup> An ultrasound examination reveals the solid nature (hyperechogenic homogeneous, well-encapsulated mass) though it may sometimes adopt local invasive behaviour, especially in

tumors in the head of epididymis.<sup>1,4</sup> MRI should be performed when ultrasonographic findings are unclear about the tumor's boundaries and its local invasive behavior or in those cases that the mass arises from the tunica albuginea/adherent to the testis.<sup>9,10</sup> Infact, 14% of adenomatoid tumors arise from the tunica albuginea.

Microscopic features of adenomatoid tumor are characterized by three basic patterns; tubules, cords, and nests with cuboidal epithelium and amphophilic, eosinophilic, or vacuolated cytoplasm. Stroma is fibrous and occasionally hyalinised.<sup>9</sup>

Immunohistochemically, an adenomatoid tumor is positive for markers, such as CK (AE1/AE3) EMA, Cam5.2, CK 5/6, CK7, calretinin, vimentin, WT1, and HBME-1. Other tumor markers, such as AFP, LDH, CEA, and b-HCG, when measured, are negative, thus excluding malignancy.<sup>4,10,11</sup>

Treatment consists of surgical removal, i.e. enucleation or total or partial epididymectomy when the tumor is well outlined.<sup>11</sup> Total tumor resection is considered to be curative as there are no reported cases of recurrence.<sup>12</sup>

Follow up is necessary for annual surveillance of the patient, which could consist of clinical examination, USG examination of the abdomen, pelvis and the scrotum, chest X-ray, and specific tumor markers (AFP, LDH, CEA, and b-HCG).<sup>2</sup>

## CONCLUSION

Adenoma of the epididymis is the most common paratesticular tumor of middle-aged patients accounting for less than 1-2% of intra-scrotal neoplasms and is usually detected incidentally. Tumour markers are negative and USG is the best modality to arrive at the diagnosis and rule out a testicular tumour. Treatment is usually enucleation or tumour resection thus removing the earlier thought need of orchidectomy. Annual follow up with clinical examination, U/S examination of the abdomen, pelvis and the scrotum, and chest X-ray is recommended.

*Funding: No funding sources*

*Conflict of interest: None declared*

*Ethical approval: Not required*

## REFERENCES

1. Maestro MA, Gonzalez RT, Dorrego JMA, Barthel JDP, Serrano MNM. Adenomatoid tumors of the epididymis and testicle: report of 9 cases and bibliographic review. Archivos Españoles de Urología. 2009;62(2):137-41.
2. Patoulias I, Kaselas C, Patoulias D, Theocharides C, Kalogirou M, Farmakis Konstantinos, et al. Epididymal adenomatoid tumor: a very rare paratesticular tumor of childhood. Case Rep Med. 2016;2:1-4.
3. Beccia DJ, Krane RJ, Olsson CA. Clinical management of non-testicular intrascrotal tumors. J Urol. 1976;116(4):476-9.
4. Amin W, Parwani AV. Adenomatoid tumor of testis. Clin Med Pathol. 2009;2009(2):17-22.
5. Pai N, Hegde S, Cherukumudi A, Rajeev TP. Adenomatoid tumor of epididymis: An unusual cause of scrotal swelling. Indian J Case Rep. 2020;6(1):4-6
6. Guo K, Tian R, Liu L, Du C, Li F, Wang H. Adenomatoid tumor of the tunica albuginea in a boy: a case report and literature review. Case Rep Urol. 2015;2015:935193.
7. Cassidy FH, Ishioka KM, McMahon CJ, Chu P, Sakamoto K, Lee KS, Aganovic L. MR imaging of scrotal tumors and pseudotumors. Radiographics. 2010 May;30(3):665-83.
8. Amin MB. Selected other problematic testicular and paratesticular lesions: rete testis neoplasms and pseudotumors, mesothelial lesions and secondary tumors. Mod Pathol. 2005;18 Suppl 2:S131-45.
9. Venyo K, Baiden-Amisshah K. Intra-scrotal adenomatoid tumour referred as an extra testis: a case report and review of the literature. Urol. 2011;2(4):1-9.
10. Sangoi AR, McKenney JK, Schwartz EJ, Rouse RV, Longacre TA. Adenomatoid tumors of the female and male genital tracts: a clinicopathological and immunohistochemical study of 44 cases. Mod Pathol. 2009;22(9):1228-35.
11. Sánchez MJM, Parra ML, García AJ. Tumores paratesticulares. actualidad en urología. Acción Médica. 2009;62(2):137-41.
12. Montero J. Tumor adenomatoide de epidídimo. Arch Esp Urol. 1968;21:425-8.

**Cite this article as:** Wadhwa S, Kothudam AR, Angani SRV, Khadri SIS. A rare case: adenoma of the epididymis. Int Surg J 2020;7:3818-20.