

## Original Research Article

# Experience with laparoscopic common bile duct exploration in failed endoscopic retrograde cholangiopancreatography cases at a tertiary care hospital

Pradeep Panwar, Hetish M. Reddy\*, Rajendra Bagree, Gaurav Jalendra

Department of General Surgery, SMS Medical College, Jaipur, Rajasthan, India

**Received:** 22 July 2020

**Revised:** 05 September 2020

**Accepted:** 09 September 2020

**\*Correspondence:**

Dr. Hetish M. Reddy,

E-mail: [hiteshid@gmail.com](mailto:hiteshid@gmail.com)

**Copyright:** © the author(s), publisher and licensee Medip Academy. This is an open-access article distributed under the terms of the Creative Commons Attribution Non-Commercial License, which permits unrestricted non-commercial use, distribution, and reproduction in any medium, provided the original work is properly cited.

### ABSTRACT

**Background:** Minimally invasive techniques for stone removal in common bile duct (CBD) are endoscopic retrograde cholangiopancreatography (ERCP) followed by laparoscopic cholecystectomy (LC) or laparoscopic CBD exploration with LC (laparoscopic common bile duct exploration (LCBDE) and LC). Failed, multiple attempted or complications of ERCP leads to other surgical approaches where LCBDE is a preferable option by experts due to its added benefits.

**Methods:** We did LCBDE and LC in 40 cases of failed ERCP. Standard investigation protocol was followed in all cases and CBD were explored laparoscopically and stones were retrieved. Post retrieval choledochoscopy was done and sphincter of oddi was dilated by the dilators.

**Results:** With careful selection of cases, stone calculi were retrieved successfully in 38 cases by laparoscopically and 2 cases by open method after conversion. Postoperative choledochoscopy were found normal. Bile leak seen in 3 cases, which were managed conservatively. Standard regime of postoperative care was taken followed by T-tube removal after cholangiogram on day 10-14. All patients survived the operation.

**Conclusion:** We advocate that LCBDE is the most viable alternative for open surgery in failed ERCP cases for retrieval of CBD stones. This results in early recovery, better cosmetic scar, least complications with early resumption of routine life. Needs cautious patient selection and expertise in laparoscopic surgery.

**Keywords:** Common bile duct, Choledocholithiasis, Laparoscopic, CBD exploration T-tube

### INTRODUCTION

Gall stone disease is the most common disorder of hepatobiliary system and 9-16% of cholelithiasis progresses into common bile duct (CBD) stone.<sup>1</sup> Open cholecystectomy and open CBD exploration were the well-known surgical treatment options for cholelithiasis and choledocholithiasis previously but, with the advent of minimal access surgery, laparoscopic cholecystectomy (LC) became gold standard for cholelithiasis.<sup>2</sup> Choledocholithiasis is now treated by a two staged approach of endoscopic retrograde cholangiopan-

creatography (ERCP) followed by LC. In cases where ERCP failed and repeating the procedure increases the risk of complications like pancreatitis, bleeding, duodenal perforation, cholangitis, malignancy, recurrent stone, etc., CBD exploration was needed and thus the laparoscopic CBD exploration laparoscopic CBD exploration (LCBDE) came into the action.<sup>3-5</sup> LCBDE is most cost effective compared to other options and has all the advantages of minimal access surgery. The CBD can be accessed either through the cystic duct or directly through a choledochotomy incision. The main benefit of choledochotomy is that it provides direct access to both

the CBD and the common hepatic duct, enabling access to more difficult stones.<sup>6</sup>

## METHODS

From January 2015 to December 2019, in the institute SMS medical college and hospital, we came across 40 choledocholithiasis cases (24:16; male: female), aged 30-60 years, where CBD stones could not be removed by ERCP and all such cases were considered for LCBDE. Standard investigation protocol i.e. CBC, LFT, RFT, USG, electrocardiogram, complete urine examinations, chest x-ray, MRCP were followed in all cases and CBD were explored laparoscopically via the trans choledochal approach and stones were retrieved by a Desjardin forceps. Post retrieval, flexible choledochoscopy was done and sphincter of oddi was dilated by the dilators. We used the same dilators and Desjardin forceps used in the open approach via the epigastric port by reducing the intraabdominal pressure.

Complications looked for included cholangitis, pancreatitis, bile leak, vomiting, fever and wound infection, and if any, were managed accordingly.

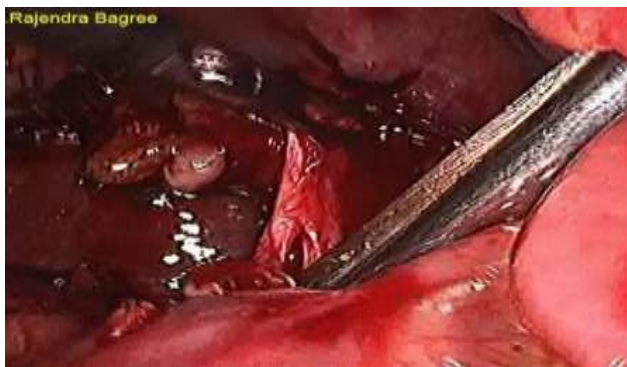It was a hospital based observational study.

Inclusion criteria included all cases of choledocholithiasis in whom CBD was not cleared with the help of ERCP and patient who gave consent for laparoscopic procedure.

Exclusion criteria included patient with comorbidities and immunocompromised state, previous history of any laparotomy, acute pancreatitis.

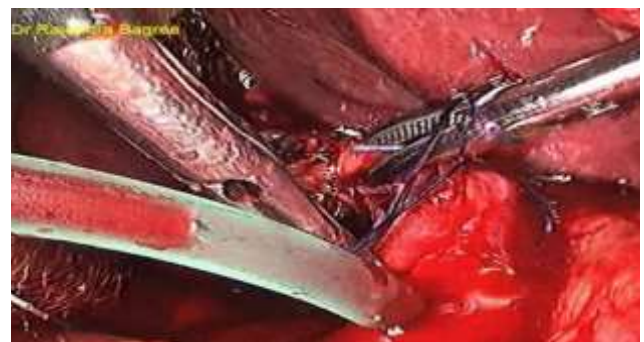
### Operative technique

In this study all cases of choledocholithiasis were subjected to ERCP and then laparoscopic cholecystectomy. The cases where large stone was present and CBD was not cleared through ERCP were planned for LCBDE. Preoperative antibiotic and vitamin k given to all cases. All patients in the study were deemed fit for surgery after due cross specialist references.



**Figure 1: Trans choledochal stone extraction.**

In technique, the standard 4-port placement of LC was used. We did not make any separate port for choledochoscope insertion. The procedure was begun as for a standard LC. The fundus of the gall bladder was retracted towards the right shoulder and the Hartman's pouch was retracted downwards and outwards toward the right hip. Calot's triangle was dissected and 'critical view of safety' obtained. The cystic artery was clipped and divided. Then the cystic duct was milked towards the gall bladder to dislodge any cystic duct stone into the gall bladder. A clip was applied on the gall bladder side to prevent any back slippage of gallstone into the CBD and to prevent biliary spillage into the operative field. After removal of gall bladder, the anterior surface of the CBD was dissected carefully and choledochotomy was performed by a longitudinal incision of 1 cm or more depending on the size of the stone with the help of endoscopic knife just below the insertion of the cystic duct into the CBD, as close to the stone as possible. Stone extraction was done by Desjardin forceps (as used in open) from the epigastric port after reducing the intra-abdominal pressure (Figure 1). After removal of stone, flexible choledochoscopy and irrigation was performed from epigastric port to see the CBD status and complete stone clearance was confirmed. A T-tube was placed in the CBD (Figure 2) with its tail exiting the abdomen through the port on the right anterior axillary line and CBD closure was done by Polyglactin 3-0 by interrupted endoscopic suturing. Intraabdominal drain placement was also done at subhepatic space in all cases and it exited the abdomen through the right mid axillary line port site which was created at the end of the procedure only for the purpose of this drain placement. It was removed on day 3 if drain output was clinically insignificant. Patients were discharged on postoperative day 5 after a T-tube cholangiogram. T-tube was removed in between post-operative day 10-14 according to the clinical status of the patient on follow-up.



**Figure 2: T-tube placement.**

### Statistical analysis

Categorical variables were presented in number and percentage and continuous variables were presented as mean  $\pm$ SD and median. The data was entered in MS EXCEL spreadsheet and analysis was done using

Statistical Package for Social Sciences (SPSS) version 21.0.

## RESULTS

In this study 24 patients were male and 16 were female, with mean age of 44.95 SD 8 years (range 30 to 59 years) (Table 1). Among all 40 patients 5% patient had an history of (n=5) pancreatitis, while 75% patients had an history of (n=30) biliary colic. Mean bilirubin were 2.57 SD 1.27 mg/dL. Mean CBD diameter was 12.02 SD 3.03 mm. Out of 40, 6 patients (15%) presented with abnormal bleeding profile in terms of raised INR and all such cases were optimized before surgery. The most frequent clinical presentation was pain abdomen followed by jaundice.

Trans choledochotomy approach was used in all cases, as all cases were of failed ERCP due to large stone. Of the 40 patients who underwent surgery, laparoscopic extraction could not be completed in 2 patients, in both cases procedure was abandoned due to dense adhesions around CBD and conversion to open surgery was performed.

CBD closure was done after placement of T-tube in all cases, postop cholangiogram done in all cases on day 5 and the T-tube was clamped till day 10-14.

**Table 1: Distribution of demographic characteristics of study subjects.**

Characteristics	Frequency	Percentage (%)
<b>Age (years)</b>		
≤40	12	30
41-50	17	42.50
51-60	11	27.50
<b>Mean ± SD</b>	44.95±8	
<b>Median (IQR)</b>	45.5 (39-51.25)	
<b>Range</b>	30-59	
<b>Gender</b>		
Female	16	40
Male	24	60

Postoperative complications are shown in Table 2. All major and minor postoperative complication were assessed carefully, and managed accordingly. Intestinal obstruction was seen in 2 cases, one of them also found to be having episode of pancreatitis on postop day 2 with raised amylase, were shifted to ICU and managed conservatively. Amongst the major complications, 3 patients presented with bile from the intra-abdominal drain. Their output was monitored closely and leaks healed spontaneously. Minor complications include nausea and vomiting (20%), fever (12.50%), wound infection (5%).

Drain removal was done on day 3 in all 37 cases where output was clinically insignificant while another 3 cases

with bile leak, the drain was removed on follow-up on day 14. All cases had a post-operative T-tube cholangiogram on day 5 and t-tube clamp on day 5. Out of 40, in 32 (80%) patients' outcome was satisfactory and all such cases discharged on day 5 while rest 8 cases discharged with delay due to minor or major complication. There was zero mortality in the study.

**Table 2: Distribution of postoperative complication of study subjects.**

Post-operative complications	Frequency	Percentage (%)
<b>Obstruction</b>	2	5
<b>Vomiting</b>	8	20
<b>Fever</b>	5	12.50
<b>Bile leak</b>	3	7.50
<b>Pancreatitis</b>	1	2.50
<b>Wound infection</b>	2	5

## DISCUSSION

In cases where ERCP failed, CBD exploration will become a mandatory procedure. We found that LCBDE has all the merits of minimal invasive surgery and superior to open surgery.

In this study, present our preliminary experience, with a success rate of 95% (38/40), which is comparable with the results of ERCP and open CBD exploration with less morbidity and zero mortality in the series is very encouraging.

In the series, all cases were referred to us after the ERCP has failed to retrieve the stone from the CBD due to an impacted big stone, hence we decided to use the choledochotomy technique in these cases right from the outset without trying to retrieve the stone by the trans cystic technique.<sup>6</sup>

In this study, we used an intraoperative choledochoscopy after stone extraction to confirm complete clearance of the CBD.

CBD was closed by placement of T-tube. CBD Closure over T-tube allows biliary decompression especially when there is concern about retained fragments or tiny stones and also it enables us for imaging the biliary system postoperatively and it provides an entrance through which any retained stones can be removed. T-tube has its disadvantages. These include- It might make way for bacteremia, accidental premature dislodgment, blockage and it might be associated with bile leak and peritonitis on its removal. Other than 3 cases of bile leak, no other t-tube related complication were seen in the study.

Whereas the length of hospital stay (LOHS) for the LC is generally short (from 1-3 days), it is longer for LCBDE and it also depends on the technique.<sup>7-10</sup> In this study, the

LOHS in the choledochotomy technique, it was longer, 5-7 days. 80% of patients discharged on day 5 after T-tube cholangiogram.

In most studies, the mortality of LCBDE is 0-1% in the hands of experienced biliary surgeons. This rate is similar to the incidence found in open CBD exploration.<sup>11-15</sup> In this study, there was no mortality, which may be attributed to improved preoperative preparation, proper patient optimization, improved anesthesia and selection of patients.

## CONCLUSION

LC is the gold standard treatment modality for cholelithiasis. In cases of choledocholithiasis, where ERCP failed, LCBDE can become the gold standard approach with conversion to open CBD exploration as a choice in case of difficulty. No doubt that the procedure has a steep learning curve. But with adequate skill and experience, the results are phenomenal with zero mortality and negligible complications.

### Limitations of the study

Although in this study LCBDE is better than other therapeutic intervention, but the sample size (n=40) is not adequate to establish a strong acceptance. Further studies with much larger sample size or multi-center studies are required to obtain confidence.

*Funding: No funding sources*

*Conflict of interest: None declared*

*Ethical approval: The study was approved by the Institutional Ethics Committee*

## REFERENCES

1. Salama AF, Abd Ellatif, Elaziz HA, Magdy A, Rizk H, Basheer M et al. Preliminary experience with laparoscopic common bile duct exploration. BMC Surg. 2017;17(1):32.
2. Savita KS, Bhartia VK. Laparoscopic CBD Exploration. Indian J Surg. 2010;72(5):395-9.
3. Gupta P, Bhartia VK. Laparoscopic management of common bile duct stones: our experience. Indian J Surg. 2005;67:94-9.
4. Cuschieri A, Lezoche E, Morino M, Croce E, Lacy A, Toouli J et al. E.A.E.S. multicenter prospective randomized trial comparing two-stage vs single-stage management of patients with gallstone disease and ductal calculi. Surg Endosc. 1999;13:952-7.
5. Tai CK, Tang CN, Ha JPY, Chau CH, Siu WT, Li MKW. Laparoscopic exploration of common bile duct in difficult choledocholithiasis. Surg Endosc. 2004;18(6):910-14.
6. Dorman JP, Franklin ME, Jr Glass JL. Laparoscopic common bile duct exploration by choledochotomy. An effective and efficient method of treatment of choledocholithiasis. Surg Endosc. 1998;12:926-8.
7. Petelin J. Laparoscopic approach to common duct pathology. Surg Lap Endosc. 1991;1:33-41.
8. Appel S, Krebs H, Fern D. Techniques for laparoscopic cholangiography and removal of common duct stones. Surg Endosc. 1992; 6:134-7.
9. Dion YM, Morin J, Dionne G, Dejoie C. Laparoscopic cholecystectomy and choledocholithiasis. CJS. 1992;35:67-74.
10. Fanning NF, Horgan PG, Keane FBV. Evolving management of common bile duct stones in the laparoscopic era. J R Coll Surg Endinb. 1997;389-394.
11. Newman KD, Powell DM, Holcomb III GW. The management of choledocholithiasis in children in the era of laparoscopic cholecystectomy. J Ped Surg. 1997;32:1116-9.
12. Heili MJ, Wintz NK, Fowler DL. Choledocholithiasis: endoscopic versus laparoscopic management. Am Surg. 1999;65:135-8.
13. Rhodes M, Sussman L, Cohen L, Lewis MP. Randomised trial of laparoscopic exploration of common bile duct versus postoperative endoscopic retrograde cholangiography for common bile duct stones. Lancet. 1998;351:159-61.
14. Croce E, Faggioni A, Jakimowicz J, Lacy A, Lezoche E, Morino M et al. EAES ductal stone study: preliminary findings of multi-center prospective randomized trial comparing two-stage vs. single-stage management. Surg Endosc. 1996;10:1130-35.
15. Frazee RC, Roberts J, Symmonds R, Hendricks JC, Snyder S, Smith R et al. Combined laparoscopic and endoscopic management of cholelithiasis and choledocholithiasis. Am J Surg. 1993;166:702-6.

**Cite this article as:** Panwar P, Reddy HM, Bagree R, Jalendra G. Experience with laparoscopic common bile duct exploration in failed endoscopic retrograde cholangiopancreatography cases at a tertiary care hospital. Int Surg J 2020;7:3344-7.